19347

Sam.l Lewis M.D.

6.2.87

TRANSACTIONS

OF THE

PATHOLOGICAL SOCIETY

OF PHILADELPHIA.

VOLUME XII.

CONTAINING THE REPORT OF THE PROCEEDINGS FROM SEPTEMBER, 1883, *TO JULY,* 1885.

EDITED BY

W. E. HUGHES, M.D.,

MEDICAL REGISTRAR OF THE UNIVERSITY HOSPITAL; PHYSICIAN TO THE OUT-PATIENT DEPARTMENT OF THE CHILDREN'S HOSPITAL; RECORDER OF THE SOCIETY.

LEWIS LIBRARY
COLLEGE OF PHARMACY
OF PHILADELPHIA
5/3/87

PHILADELPHIA:
PRINTED FOR THE SOCIETY BY WM. J. DORNAN.
1886.

THE present volume includes the Transactions of the Society from September, 1883, to June, 1885, inclusive.

The papers by Dr. Seiler, on The Pathology of Phthisis Pulmonalis and its Laryngeal Complications (p. 115); by Dr. Delafield, on The Pathology of Broncho-pneumonia (p. 139); and by Dr. Sternberg, on The Pneumoniococcus of Friedländer (*Micrococcus Pasteuri*, Sternberg) (p. 162), were read by the respective authors at the semi-annual conversational meetings of the Society, they having been appointed to open the proceedings on those evenings.

TABLE OF CONTENTS OF VOL. XII.

	PAGE
List of Officers and Committees Elected 1884	iv
List of Officers and Committees Elected 1886	v
List of Former Presidents	vi
List of Members	vii
List of Corresponding Members	xviii
List of Specimens Exhibited at the Meetings of the Society	xix
List of Specimens Reported on by the Committee on Morbid Growths	xxiv
List of Illustrations	xxiv
Diseases, etc., of the Osseous System	1
Diseases, etc., of the Digestive Apparatus	23
Diseases, etc., of the Vascular System	73
Diseases, etc., of the Organs of Respiration	114
Diseases, etc., of the Genito-urinary Apparatus	200
Diseases, etc., of the Nervous System	234
Diseases, etc., of the Organs of Special Sense	236
Tumors not otherwise Classified	244
Miscellaneous	268
Index	281

19347

OFFICERS AND COMMITTEES

OF THE

PATHOLOGICAL SOCIETY OF PHILADELPHIA.

(Elected at the annual meeting, October, 1884.)

President.

E. O. SHAKESPEARE, M.D.

Vice-Presidents.

J. H. C. SIMES, M.D.,
C. K. MILLS, M.D.,
F. P. HENRY, M.D.,
CARL SEILER, M.D.

Secretary.

G. G. DAVIS, M.D.

Recorder.

C. B. NANCREDE, M.D.

Treasurer.

M. S. FRENCH, M.D.

Curator.

H. F. FORMAD, M.D.

Committee on Publication.

JAMES TYSON, M.D., J. H. MUSSER, M.D.,
C. M. WILSON, M.D., F. P. HENRY, M.D.,
C. B. NANCREDE, M.D. (ex-officio).

Committee on Morbid Growths.

G. E. DE SCHWEINITZ, M.D., F. P. HENRY, M.D.,
H. F. FORMAD, M.D., CARL SEILER, M.D.,
W. E. HUGHES, M.D., H. M. FISHER, M.D.,
E. T. BRUEN, M.D.

Business Committee.

J. H. MUSSER, M.D., J. M. BARTON, M.D.,
W. E. HUGHES, M.D., G. G. DAVIS, M.D.,
E. T. BRUEN, M.D.

OFFICERS AND COMMITTEES

OF THE

PATHOLOGICAL SOCIETY OF PHILADELPHIA.

(Elected at the annual meeting, October, 1886.)

President.

J. C. WILSON, M.D.

Vice-Presidents.

J. H. C. SIMES, M.D.,
F. P. HENRY, M.D.,
J. M. BARTON, M.D.,
H. F. FORMAD, M.D.

Secretary.

J. K. MITCHELL, M.D.

Recorder.

W. E. HUGHES, M.D.

Treasurer.

M. S. FRENCH, M.D.

Curator.

H. F. FORMAD, M.D.

Committee on Publication.

J. H. MUSSER, M.D., HENRY BEATES, Jr., M.D.,
H. R. WHARTON, M.D., F. P. HENRY, M.D.,
W. E. HUGHES, M.D. (ex-officio).

Committee on Morbid Growths.

G. E. DE SCHWEINITZ, M.D., MORRIS LONGSTRETH, M.D.,
WILLIAM OSLER, M.D., B. A. RANDALL, M.D.,
F. P. HENRY, M.D., GUY HINSDALE, M.D.

Business Committee.

W. A. EDWARDS, M.D., HENRY BEATES, Jr., M.D.,
J. H. MUSSER, M.D., JAMES TYSON, M.D.,
B. A. RANDALL, M.D.

FORMER PRESIDENTS.

SAMUEL D. GROSS, M.D., LL.D., D.C.L. Oxon., LL.D. Cantab., elected 1857.

RENÉ LA ROCHE, M.D., elected 1858.

ALFRED STILLÉ, M.D., elected 1859, '61, and '62.

EDWARD HARTSHORNE, M.D., elected 1860 and '63.

J. M. DA COSTA, M.D., elected 1864, '65, and '66.

JOHN H. PACKARD, M.D., elected 1867 and '68.

S. WEIR MITCHELL, M.D., elected 1869.

JOHN ASHHURST, Jr., M.D., elected 1870.

JAMES H. HUTCHINSON, M.D., elected 1871 and '72.

WILLIAM PEPPER, M.D., elected 1873.

H. LENOX HODGE, M.D., elected 1876.

S. W. GROSS, M.D., elected 1879.

JAMES TYSON, M.D., elected 1882.

LIST OF MEMBERS.

Members marked O. M. are those originating the Society.
Members marked N. R. are non-resident.

ELECTED

1857 AGNEW, D. HAYES, Rhea Barton Professor of Surgery in the University of Pennsylvania, 1601 Walnut Street. (O. M.)

1871 ALISON, ROBERT H., resigned 1884.

1864 ALLEN, HARRISON, resigned December 11, 1879.

1869 ALLIS, OSCAR H., resigned February 24, 1881.

1865 ANDREWS, THOMAS H., 1117 Spruce Street.

1871 ASHBRIDGE, WILLIAM, resigned December 11, 1879.

1867 ASHHURST, FRANCIS, Mount Holly, New Jersey. (N. R.)

1861 ASHHURST, JOHN, Jr., Professor of Clinical Surgery in the University of Pennsylvania, 2000 De Lancey Place.

1863 ASHHURST, SAMUEL, Surgeon to the Children's Hospital, 2308 De Lancey Place.

1871 ATLEE, WASHINGTON L., Jr., forfeited membership by non-payment of dues, December 10, 1874.

1866 BACHE, T. HEWSON, resigned December 27, 1883.

1878 BAER, B. F., resigned.

1876 BARR, J. W., forfeited membership by non-payment of dues, December 8, 1881.

1880 BARTHOLOW, ROBERTS, Professor of Materia Medica in the Jefferson Medical College, 1525 Locust Street.

1868 BARTLES, WM. H., Insane Department Pennsylvania Hospital, West Philadelphia. (N. R.)

1883 BARTON, ISAAC, 128 South Fifteenth Street.

1869 BARTON, J. M., Surgeon to the German and Jefferson Medical College Hospitals, 1344 Spruce Street.

1885 BEATES, HENRY, Jr., 445 North Seventh Street.

1873 BEECHER, A. C. W., 523 South Ninth Street.

1870 BELL, J. R. F., forfeited membership by non-payment of dues, December 10, 1874.

1871 BENNETT, WM. H., 332 South Fifteenth Street.

1863 BENTON, C. H. (N. R.)

1887 BERENS, BERNARD, 2006 Arch Street.

1875 BERNARDY, EUGENE P., resigned September 22, 1881.

ELECTED

1870 BERTHOLET, ROBERT MORRIS, died 1882.
1871 BETTS, THOMAS, Branchtown, Pa. (N. R.)
1860 BISHOP, C. S., died.
1866 BLACK, J. J., New Castle, Delaware. (N. R.)
1863 BOARDMAN, C. H., St. Paul, Minnesota. (N. R.)
1886 BODAMER, GEORGE A., German Hospital.
1880 BŒNNING, HENRY C., forfeited membership by non-payment of dues, April 14, 1882.
1857 BOKER, CHARLES S., Surgeon to St. Joseph's Hospital, 1622 Chestnut Street. (O. M.)
1868 BOLLES, LUCIUS S., died August 15, 1873.
1883 BOYD, GEORGE M., 1743 North Seventeenth Street.
1877 BRADFORD, T. HEWSON, resigned December 23, 1880.
1873 BRAY, DANIEL, forfeited membership by non-payment of dues, December 8, 1881.
1883 BREINIG, P. B., Bethlehem, Pennsylvania.
1857 BRINTON, JOHN H., Professor of the Practice of Surgery and Clinical Surgery in the Jefferson Medical College, 1423 Spruce Street. (O. M.)
1874 BRUBAKER, A. P., 1210 Race Street.
1874 BRUEN, E. T., Professor of Physical Diagnosis in the University of Pennsylvania, Physician to the Philadelphia Hospital, 1814 Locust Street.
1871 BUCK, WILLIAM PENN, resigned October 23, 1873.
1867 BURNETT, CHARLES H., resigned December 8, 1881.

1882 CATHCART, JAMES H., died March 5, 1874.
1879 CATHCART, T. H., died March 28, 1882.
1871 CHESTON, C. MORRIS, West River, Maryland. (N. R.)
1865 CHESTON, D. MURRAY, resigned December 13, 1883.
1871 CLARK, LEONARDO S., resigned November 29, 1883.
1866 CLEEMANN, RICHARD A., Physician to St. Mary's Hospital, 2135 Spruce Street.
1872 COHEN, J. SOLIS, Professor of Diseases of the Throat and Chest in the Philadelphia Polyclinic and School for Graduates, 1431 Walnut Street.
1883 COHEN, S. SOLIS, 1431 Walnut Street.
1869 CORBIT, WILLIAM B., Washington, D. C. (N. R.)
1877 CRUICE, R. B., 731 North Seventeenth Street.
1871 CURTIN, ROLAND G., Physician to the Philadelphia Hospital, 22 South Eighteenth Street.

1857 DA COSTA, J. M., Professor of the Theory and Practice of Medicine in the Jefferson Medical College, 1700 Walnut Street. (O. M.)
1885 DALAND, JUDSON, 319 South Eighteenth Street.
1859 DARBY, J. T., New York City. (N. R.)
1876 DARLINGTON, W. L. (N. R.)

ELECTED

1857 DARRACH, JAMES, 5094 Green Street, Germantown. (O. M.)

1868 DARRACH, WILLIAM, died January 28, 1881.

1882 DAVIS, G. G., 1817 Mount Vernon Street.

1885 DEAVER, J. B., Demonstrator of Anatomy in the University of Pennsylvania, Surgeon to the Philadelphia Hospital, 1610 Vine Street.

1877 DEAVER, R. W., resigned January 27, 1887.

1882 DERCUM, F. X., Pathologist to the State Hospital for the Insane at Norristown, Pennsylvania; Chief of Dispensary for Nervous Diseases, University Hospital, 636 North Eighth Street.

1882 DE SCHWEINITZ, G. E., Ophthalmic Surgeon to the Children's Hospital, 1330 Spruce Street.

1885 DOCK, GEORGE.

1886 DONGES, JOHN W., Camden, New Jersey.

1877 DRYSDALE, T. M., 1531 Arch Street.

1883 DUNN, T. D., West Chester, Pennsylvania. (N. R.)

1866 DUER, EDWARD L , 1704 Arch Street.

1870 DUHRING, L. A., resigned November 9, 1882.

1876 DULLES, C. W., 4101 Walnut Street.

1860 DUNTON, W. R., 5059 Germantown Avenue, Germantown.

1883 DUNMIRE, G. B., 1116 Arch Street.

1883 EDWARDS, J. F., 115 South Seventh Street.

1882 EDWARDS, W. A., Physician to St. Joseph's Hospital, 300 South Thirteenth Street.

1885 EGBERT, J. C., General Wayne, Pennsylvania.

1875 ENGEL, HUGO, forfeited membership by non-payment of dues, February 23, 1882.

1876 ESKRIDGE, J. T., Colorado Springs, Colorado. (N. R.)

1881 FENTON, T. H., 1335 Arch Street.

1857 FISCHER, EMIL, 729 North Sixth Street. (O. M.)

1863 FISH, AUGUSTINE H., died August 3, 1872.

1876 FISHER, HENRY M., Physician to the Episcopal Hospital, 919 Walnut Street.

1857 FORBES, WILLIAM S., Professor of Anatomy in the Jefferson Medical College, 1409 Locust Street. (O. M.)

1869 FORD, WILLIAM H., 1622 Summer Street.

1878 FORMAD, H. F., Demonstrator of Pathology in the University of Pennsylvania, 3535 Locust Street.

1871 FOX, CHARLES, resigned December 10, 1884.

1886 FREEMAN, W. J., 2034 Chestnut Street.

1880 FRENCH, M. S., 1423 Walnut Street.

1885 FUSSELL, M. H., 168 Green Lane, Manayunk.

ELECTED

1883 GARRETT, E. F., 5043 Germantown Avenue, Germantown.
1868 GARRETSON, JAMES E., resigned November 22, 1883.
1871 GERHARD, GEORGE S., Ardmore, Pennsylvania. (N. R.)
1870 GETCHELL, FRANK H., 1432 Spruce Street.
1877 GILLIARD, LOUIS, died November, 1878.
1882 GODEY, H. E., N. E. corner Nineteenth and Spruce Streets.
1877 GOLDSBOROUGH, C. B. (N. R.)
1866 GOODELL, WILLIAM, Clinical Professor of Diseases of Women in the University of Pennsylvania, 500 North Twentieth Street.
1886 GOODELL, W. C., 500 North Twentieth Street.
1868 GOODMAN, H. ERNEST, resigned February 23, 1882.
1868 GRAHAM, JAMES, resigned January 9, 1879.
1867 GRIER, MATTHEW J., 1531 Spruce Street.
1883 GRIFFITH, J. P. C., 123 South Eighteenth Street.
1868 GROSS, FERDINAND H., Surgeon to the German Hospital, 1416 Girard Avenue.
1857 GROSS, SAMUEL D., died May 6, 1884. (O. M.)
1858 GROSS, SAMUEL W., Professor of the Principles of Surgery and Clinical Surgery in the Jefferson Medical College, 1112 Walnut Street.
1869 GROVE, JOHN H., Surgeon to St. Mary's Hospital, 1330 Arch Street.
1862 GRUEL, THEODORE H. E., 612 Spruce Street.
1874 GUITÉRAS, JOHN, Charleston, South Carolina. (N. R.)

1884 HAEHNLEN, W. F., 1421 North Broad Street.
1871 HALE, GEORGE J., forfeited membership by non-payment of dues, March 23, 1876.
1857 HALL, A. DOUGLASS, resigned October 9, 1873. (O. M.)
1886 HAMAKER, W. D., Meadeville, Pennsylvania. (N. R.)
1875 HAND, FRANK C., died September 1, 1881.
1885 HARE, HOBART A., 113 South Twenty-second Street.
1866 HARE, HORACE BINNEY, died March 21, 1879.
1868 HARGADINE, R. W. (N. R.)
1859 HARLAN, GEORGE C., resigned January 12, 1882.
1874 HARRIS, CHARLES M., died.
1858 HARRIS, ROBERT P., resigned January 9, 1873.
1881 HART, R. H., forfeited membership by non-payment of dues.
1857 HARTSHORNE, EDWARD, died June 29, 1885. (O. M.)
1859 HARTSHORNE, HENRY, resigned October 12, 1864.
1867 HASSLER, FERDINAND A., resigned February 9, 1871.
1869 HATFIELD, NATHAN L., Surgeon to the Philadelphia Hospital, 501 Franklin Street.
1868 HAYES, I. MINIS, resigned January 13, 1881.
1879 HAZLEHURST, S. F. (N. R.)
1873 HEARN, JOSEPH, Surgeon to the Jefferson Medical College Hospital, Surgeon to the Philadelphia Hospital, 312 Catharine Street.

ELECTED

1870 HENRY, FREDERICK P., Professor of Practice of Medicine in the Philadelphia Polyclinic and School for Graduates, Physician to the Episcopal Hospital, 721 Pine Street.
1866 HERBERT, THEODORE. (N. R.)
1879 HESS, ROBERT, resigned January 12, 1882.
1857 HEWSON, ADDINELL, forfeited membership by non-payment of dues, December 22, 1881. (O. M.)
1880 HEWSON, ADDINELL, Jr., 1304 Pine Street.
1874 HICKMAN, N. B., forfeited membership by non-payment of dues, December 8, 1881.
1884 HINSDALE, GUY, 4004 Chestnut Street.
1858 HODGE, H. LENOX, died June 10, 1881.
1883 HOELLY, G. H., Camden, New Jersey.
1871 HOFFMAN, WASHINGTON ATLEE, died September 20, 1874.
1886 HOLLAND, J. W., Professor of Chemistry in the Jefferson Medical College, 1914 Locust Street.
1860 HOPKINS, HENRY ST. GEORGE. (N. R.)
1876 HOPKINS, W. B., resigned October 14, 1880.
1877 HORWITZ, THEODORE, died December 12, 1877.
1870 HOUSTON, JAMES P. S., Savannah, Georgia. (N. R.)
1866 HOWE, HERBERT M., resigned February 28, 1878.
1859 HOYT, WILLIAM D. (N. R.)
1880 HUGHES, D. E., Williamsport, Pennsylvania. (N. R.)
1882 HUGHES, W. E., Medical Registrar of the University Hospital, 3726 Baring Street.
1879 HUIDEKOPER, R. S., resigned October 28, 1880.
1857 HUMPHRIES, GEORGE H., New York City. (O. M., N. R.)
1868 HUNTER, CHARLES T., resigned October 14, 1880.
1870 HUTCHINS, E. R. (N. R.)
1858 HUTCHINSON JAMES H., Physician to the Pennsylvania Hospital, 133 South Twenty-second Street.

1866 INGHAM, JAMES V., resigned December 11, 1879.
1866 INGRAM, T. D., forfeited membership by non-payment of dues, December 8, 1881.

1874 JAMISON, EDWARD, St. Louis, Missouri. (N. R.)
1866 JENKS, WILLIAM, died October 31, 1881.
1875 JOHNSON, RUSSELL H., resigned December 8, 1881.
1883 JUDD, L. D., 3603 Powelton Avenue.
1885 JURIST, L. J., 1210 Walnut street.

1859 KANE, JOHN K., Wilmington, Delaware. (N. R.)
1857 KEALER, WILLIAM, resigned January 28, 1875. (O. M.)
1874 KEATING, JOHN M., resigned December 22, 1881.
1857 KEATING, WILLIAM V., forfeited membership by non-payment of dues, September 14, 1864. (O. M.)

ELECTED

1866 KEEN, WILLIAM W., resigned December 9, 1886.
1875 KELLY, JOSEPH V., 4257 Main Street, Manayunk.
1884 KILDUFF, ROBERT, resigned December 9, 1886.
1858 KING, WILLIAM, died.
1879 KIRKBRIDE, J. J., 35 South Nineteenth Street.
1869 KNIGHT, SAMUEL R., resigned October 28, 1880.

1867 LAMBDIN, A. C., forfeited membership by non-payment of dues, December 10, 1874.
1871 LANDIS, HENRY G., died.
1872 LA ROCHE, C. PERCY, Nice, France. (N. R.)
1857 LA ROCHE, RENÉ, died December 9, 1872. (O. M.)
1879 LEACH, A. L., forfeited membership by non-payment of dues, December 22, 1881.
1869 LEAMAN, HENRY, 828 North Broad Street.
1860 LEE, CHARLES C., New York City. (N. R.)
1882 LEE, J. G., resigned September, 1883.
1861 LEEDOM, JOHN M., died.
1887 LEOPOLDT, ISAAC, 1520 Franklin Street.
1857 LEVICK, JAMES J., resigned October 13, 1861. (O. M.)
1868 LEWIS, FRANCIS W., 2016 Spruce Street.
1869 LEWIS, FRED. W., died 1873.
1875 LEWIS, MORRIS J., Physician to the Episcopal Hospital, 1216 Walnut Street.
1857 LEWIS, SAMUEL, Aldine Hotel. (O. M.)
1877 LITTLE, WILLIAM S., 215 South Seventeenth Street.
1859 LIVEZY, EDWARD, forfeited membership by non-payment of dues, September 14, 1864.
1886 LLOYD, JAMES HENDRIE, 200 South Fortieth Street.
1876 LODER, P. E., forfeited membership by non-payment of dues, February 9, 1882.
1886 LONGAKER, D., 513 Green Street.
1873 LONGENECKER, JEROME, forfeited membership by non-payment of dues, 1875.
1875 LONGSTRETH, MORRIS, Physician to the Pennsylvania Hospital, 1416 Spruce Street.
1870 LOUGHLIN, J. ENEU, forfeited membership by non-payment of dues, May 9, 1878.

1882 MACCONNELL, W. G., 250 South Tenth Street.
1873 MACCOY, A. W., 1415 Walnut Street.
1874 MANN, CHARLES H. (N. R.)
1867 MARKOE, JAMES, died March, 1884.
1868 MARTIN, GEORGE. (N. R.)

ELECTED

1874 MATTISON, CHARLES C., died.

1865 MAURY, FRANK F., died 1879.

1870 MAXWELL, J. G., forfeited membership by non-payment of dues, December 10, 1874.

1866 MCARTHUR, J. A., forfeited membership by non-payment of dues, December 8, 1881.

1861 MCCALL, C. A., resigned.

1880 MCCLELLAN, G., 1352 Spruce Street.

1868 MCCLURE, W. W., resigned September 10, 1878.

1884 MCILVAINE, E. S., resigned December 11, 1884.

1864 MEARS, J. EWING, Surgeon to St. Mary's Hospital, 1429 Walnut Street.

1873 MEIGS, ARTHUR V., Physician to the Pennsylvania Hospital, 1322 Walnut Street.

1857 MEIGS, JOHN FORSYTHE, died December 16, 1882. (O. M.)

1874 MILLER, C. K. I., died 1878.

1882 MILLER, D. J. M., 2310 Spruce Street.

1878 MILLS, C. K., Professor of Diseases of the Mind and Nervous System in the Philadelphia Polyclinic and School for Graduates, Neurologist to the Philadelphia Hospital, 1909 Chestnut Street.

1885 MITCHELL, JAMES, 808 North Sixteenth Street.

1884 MITCHELL, J. K., 314 South Sixteenth Street.

1857 MITCHELL, S. WEIR, Physician to the Hospital for Nervous Diseases, 1524 Walnut Street. (O. M.)

1876 MONTGOMERY, E. C., resigned January 11, 1883.

1857 MOREHOUSE, GEORGE R., 227 South Ninth Street. (O. M.)

1884 MORRISON, WILLIAM H., Holmesburg, Pennsylvania. (N. R.)

1857 MORTON, T. G., forfeited membership by non-payment of dues, September 14, 1864. (O. M.)

1885 MORTON, T. S. K., 1421 Chestnut Street.

1859 MOSS, WILLIAM, resigned December 10, 1885.

1871 MUHLENBERG, FRANK, 1911 Chestnut Street.

1869 MÜLLER, AUGUST F., 4753 Green Street, Germantown.

1880 MUSSER, J. H., Physician to the Philadelphia Hospital, Pathologist to the Presbyterian Hospital, Chief of Medical Dispensary, University Hospital, 3705 Powelton Avenue.

1873 MUSSER, M. B., Obstetrician to the Philadelphia Hospital, 229 South Fortieth Street.

1869 MUSTIN, J. BURTON, died 1871.

1869 NANCREDE, C. B., Professor of General and Orthopædic Surgery in the Philadelphia Polyclinic and School for Graduates, Surgeon to the Episcopal Hospital, Surgeon to St. Christopher's Hospital for Children, 2109 Pine Street.

1879 NEFF, J. S., Physician to the Philadelphia Hospital, 214 South Fifteenth Street.

ELECTED

1885 NEILSON, T. R., 346 South Fifteenth Street.
1880 NEWCOMET, H. W., died June 1, 1885.
1872 NEWSHAM, STANLEY P., resigned December 23, 1881.
1868 NORRIS, HERBERT, resigned January 8, 1880.
1868 NORRIS, ISAAC, resigned November 12, 1874.
1869 NORRIS, J. C., resigned February 10, 1876.
1861 NORRIS, WILLIAM F., Clinical Professor of Ophthalmology in the University of Pennsylvania, 1530 Locust Street.

1875 O'HARA, MICHAEL, 31 South Sixteenth Street.
1886 OLIVER, C. A., 1507 Locust Street.
1874 OSGOOD, HAMILTON. (N. R.)
1885 OSLER, WILLIAM, Professor of Clinical Medicine in the University of Pennsylvania, 131 South Fifteenth Street.

1885 PACKARD, F. A., Pennsylvania Hospital.
1857 PACKARD, JOHN H., Surgeon to the Pennsylvania Hospital, 1437 Spruce Street. (O. M.)
1868 PANCOAST, WILLIAM H., Professor of Surgical Anatomy and Clinical Surgery in the Medico-Chirurgical College, 1100 Walnut Street.
1875 PARKS, EDWARD L. (N. R.)
1873 PARRISH, WILLIAM H., Professor of Anatomy in the Woman's Medical College, 1435 Spruce Street.
1867 PARRY, JOHN S., died 1876.
1870 PAUL, COMEGYS, Belvidere, New Jersey. (N. R.)
1875 PAUL, JAMES, resigned January 22, 1880.
1857 PENROSE, R. A. F., forfeited membership by non-payment of dues, September 14, 1864. (O. M.)
1865 PEPPER, GEORGE, died September 14, 1872.
1865 PEPPER, WILLIAM, Professor of Theory and Practice of Medicine in the University of Pennsylvania, 1811 Spruce Street.
1879 PERKINS, F. M., 1428 Pine Street.
1885 PIERSOL, G. A., 1110 Spring Garden Street.
1870 PORTER, WILLIAM G., Surgeon to the Presbyterian Hospital, 1223 Spruce Street.
1886 POWELL, WILLIAM M., 2205 Pine Street.

1885 RAHTER, C. A., Harrisburg, Pennsylvania.
1885 RANDALL, B. A., Ophthalmic Surgeon to the Children's Hospital, 1806 Chestnut Street.
1878 RAUB, J. A., 927 North Twelfth Street.
1885 REED, BOARDMAN, Atlantic City, New Jersey.
1884 REED, C H , 1529 Arch Street.
1874 REED, H. B., resigned December 9, 1880.
1859 REED, THOMAS B., Surgeon to the Presbyterian Hospital, 1427 Walnut Street.

ELECTED

1871 Rex, George A., 2118 Pine Street.

1869 Rex, O. P., forfeited membership by non-payment of dues, December 10, 1874.

1877 Reynolds, A. S., forfeited membership by non-payment of dues, February 9, 1882.

1864 Rhoads, Edward, died January 16, 1871.

1878 Rich, T. C., resigned January 13, 1881.

1869 Richardson, Elliott, resigned December 8, 1881.

1863 Richardson, Joseph G., died November 13, 1886.

1857 Richardson, T. G., New Orleans, Louisiana. (O. M.) (N. R.)

1884 Ridge, J, M., Camden, New Jersey.

1886 Riera, J. H., 1630 Vine Street.

1876 Risley, S. D., Lecturer on Ophthalmoscopy in the University of Pennsylvania, 1722 Walnut Street.

1868 Ritz, Charles M. (N. R.)

1886 Riveley, M. P., 121 South Eighteenth Street.

1880 Roberts, A. S., Instructor in Orthopædics in the University of Pennsylvania, 225 South Sixteenth Street.

1876 Roberts, J. B., Professor of General and Operative Surgery in the Philadelphia Polyclinic and School for Graduates, Surgeon to St. Mary's Hospital, 1627 Walnut Street.

1876 Roland, O. (N. R.)

1874 Ronaldson, W. D. (N. R.)

1877 Rudolph, B. J., forfeited membership by non-payment of dues, February 23, 1882.

1867 Santee, Eugene J., 605 North Eleventh Street.

1863 Savery, William, resigned February 11, 1869.

1869 Schell, H. S., resigned December 8, 1881.

1874 Seiler, Carl, 1346 Spruce Street.

1870 Seyfert, T. H., resigned December 27, 1877.

1870 Shaffner, Charles, 251 South Thirteenth Street.

1876 Shakespeare, E. O., Pathologist to the Philadelphia Hospital, Ophthalmic Surgeon to the Philadelphia Hospital, 1336 Spruce Street.

1869 Shapleigh, Elisha B., 658 North Eighth Street.

1868 Sherwood, T. H., forfeited membership by non-payment of dues, December 10, 1874.

1885 Shober, J. B., 1311 Spruce Street.

1878 Shoemaker, J. V., 1519 Walnut Street.

1871 Simes, J. H. C., Professor of Genito-urinary Diseases in the Philadelphia Polyclinic and School for Graduates, Surgeon to the Episcopal Hospital, 2033 Chestnut Street.

1883 Simon, J. W. (N. R.)

1868 Sinkler, Wharton, Physician to the Hospital for Nervous Diseases, 1534 Pine Street.

ELECTED

1881 SKILLERN, P. G., 429 South Broad Street.
1881 SKILLERN, S. R., 3509 Baring Street.
1858 SMITH, A. H., died December, 1885.
1863 SMITH, E. A. (N. R.)
1859 SMITH, F. G., resigned November 13, 1873.
1876 SMITH, R. M., resigned December 9, 1880.
1875 SMITH, STANLEY. (N. R.)
1876 SMYTHE, F. G., died 1879.
1871 SPARKS, G. W., forfeited membership by non-payment of dues, December 10, 1874.
1866 SPOONER, E. A., forfeited membership by non-payment of dues, December 10, 1874.
1871 STARR, LOUIS, resigned October 14, 1880.
1886 STEWART, DAVID D., 2628 North Fifth Street.
1883 STILES, G. A., Conshokocken, Pennsylvania.
1857 STILLÉ, ALFRED, Professor Emeritus of the Theory and Practice of Medicine in the University of Pennsylvania, 3900 Spruce Street. (O. M.)
1870 STRAWBRIDGE, GEORGE, resigned June 10, 1875.
1884 STRITMATTER, I. P., 1232 North Fifth Street.
1869 STRYKER, SAMUEL S., Obstetrician to the Philadelphia Hospital, 3821 Walnut Street.

1886 TAYLOR, L. H., Wilkesbarre, Pennsylvania. (N. R.)
1879 TAYLOR, J. M., 331 South Sixteenth Street.
1866 THOMAS, C. H., resigned February 11, 1886.
1868 THOMSON, WILLIAM, Surgeon to Wills Ophthalmic Hospital, 1426 Walnut Street.
1870 TINKHAM, J. H., United States Navy. (N. R.)
1866 TOWNSEND, GEORGE D. (N. R.)
1868 TOWNSEND, R. M., died.
1886 TULL, M. G., resigned December 9, 1886.
1864 TURNER, A. P. (N. R.)
1863 TUTT, CHARLES PENDLETON, died May 11, 1866.
1863 TYSON, JAMES, Professor of General Pathology and Morbid Anatomy in the University of Pennsylvania, 1506 Spruce Street.

1885 ULRICH, W. B., Chester, Pennsylvania.

1871 VALDIVIESO, R. (N. R.)
1870 VAN HARLINGEN, ARTHUR, resigned December 8, 1881.
1879 VAN VALZAH, W. W., 1704 Arch Street.

1874 WARDER, W. H., Obstetrician to the Philadelphia Hospital, 1212 North Broad Street.
1867 WATSON, E. W., 201 North Twentieth Street.

ELECTED

1866 WEIGHTMAN, J. F., resigned April 27, 1871.

1876 WEIR, A. H., resigned April 14, 1881.

1875 WEST, FRANKLIN, died.

1882 WETHERILL, H. M., resigned October, 1885.

1885 WETHERILL, R. B., Lafayette, Indiana. (N. R.)

1885 WHARTON, H. R., Surgeon to the Children's Hospital, 1405 Locust Street.

1875 WHELEN, ALFRED, resigned December 23, 1880.

1873 WHITE, J. WILLIAM, Demonstrator of Surgery in the University of Pennsylvania, Surgeon to the Philadelphia Hospital, 1806 Locust Street.

1868 WILLARD, DE FOREST, Lecturer on Orthopædic Surgery in the University of Pennsylvania, Surgeon to the Presbyterian Hospital, 1818 Chestnut Street.

1865 WILLIAMS, HORACE, resigned December 11, 1879.

1875 WILLIAMSON, JESSE, resigned October 13, 1881.

1882 WILSON, C. M., 121 South Seventeenth Street.

1867 WILSON, ELWOOD, resigned.

1880 WILSON, H. A., resigned December 30, 1882.

1869 WILSON, JAMES C., Physician to the Philadelphia Hospital, Physician to the Jefferson Medical College Hospital, 1437 Walnut Street.

1867 WILSON, JAMES F., 1010 Race Street.

1869 WILSON, J. H. (N. R.)

1873 WINSLOW, W. H., resigned December 28, 1876.

1864 WISTAR, THOMAS, resigned February 13, 1867.

1875 WOLFORD, W. S., 1310 Walnut Street.

1863 WOOD, H. C., Jr., forfeited membership by non-payment of dues, March 23, 1876.

1883 WOODBURY, F., 218 South Sixteenth Street.

1865 WOODS, D. FLAVEL, Physician to the Presbyterian Hospital, 1501 Spruce Street.

1857 WOODWARD, J. J., U. S. A., died 1884. (O. M.)

1872 WORTHINGTON, D. J., forfeited membership by non-payment of dues, February 9, 1882.

1886 YOUNG, J. K., Surgical Registrar University Hospital, 220 South Sixteenth Street.

1876 ZIEGLER, G. W. (N. R.)

CORRESPONDING MEMBERS.

1866 Bumstead, Freeman J. Died 1879.

1859 Clark, Alonzo, Professor of Theory and Practice of Medicine in the College of Physicians and Surgeons, New York.

1859 Dalton, J. C., Professor of Physiology in the College of Physicians and Surgeons, New York.

1885 Dent, Clinton, London, England.

1860 Ellis, Calvin, Professor of Theory and Practice of Medicine in the Medical Department of Harvard University, Boston, Massachusetts.

1858 Flint, Austin, Sr. Died 1886.

1858 Hammond, William A., member of the National Academy of Sciences, New York.

1860 Isaacs, Charles E., Brooklyn. Died June 16, 1860.

1878 Jackson, J. B. S., Boston. Died 1879.

1886 Pye-Smith, P., London, England.

1860 Reeves, James E., Wheeling, West Virginia.

1861 Rokitansky, Carl. Died 1878.

1860 Watson John, New York. Died June 3, 1869.

1859 Worthington, Wilmer, West Chester, Pennsylvania. Died 1873.

LIST OF SPECIMENS.

I. THE OSSEOUS SYSTEM.

PAGE

1. Large spindle-celled sarcoma of lower jaw. By Dr. W. G. MacConnell for Dr. W. H. Pancoast 1
2. Fracture of the base of the skull. By Dr. Guy Hinsdale . . 1
3. Osteomyelitis of tibia following simple fracture. By Dr. C. M. Wilson 2
4. Caries of the head of the humerus. By Dr. C. B. Nancrede . 5
5. Caries of the astragalus. By Dr. C. B. Nancrede . . . 6
6. Specimens from a case of extensive trephining of the skull. By Dr. C. B. Nancrede 6
7. Round-celled sarcoma of the superior maxilla; excision of that bone with the malar. By Dr. C. B. Nancrede 7
8 Specimens from a case of resection of the humerus. By Dr. C. B. Nancrede 8
9. A case of infantile mollities ossium. By Dr. C. M. Wilson . . 8
10. A case of ununited fracture of both bones of the forearm. By Dr. C. M. Wilson 9
11. Compound fracture of the leg and foot; amputation after one year; recovery. By Dr. Guy Hinsdale 10
12. Early osteitis of the hip-joint; from a case of bilateral coxalgia. By Dr. A. S. Roberts 11
13. Sarcoma of the clavicle. By Dr. G. E. de Schweinitz . . 13
14. Specimens from excision of the astragalus for caries, etc. By Dr. C. B. Nancrede 14
15. Synostosis of the vertebral column. By Dr. A. S. Roberts . . 15
16. Spondylitis of the dorsal vertebræ, with miliary tuberculosis of the lungs. By Dr. A. S. Roberts 16
17. Chronic knee-joint disease followed by acute inflammation. By Dr. H. R. Wharton 18
18. Fracture of the pelvis; rupture of the bladder; fracture of the forearm. By Dr. De Forest Willard 18
19. Osteomyelitis of the femur. By Dr. De Forest Willard . . 21
20. Chronic osteomyelitis of the humerus, the result of compound luxation with fracture. By Dr. C. B. Nancrede 22

II. THE DIGESTIVE APPARATUS.

1. Very large ulcer of the stomach, with unusual features. By Dr. C. W. Dulles 23

PAGE

2. Tubercular ulceration of the intestine, with tubercular infiltration of the lungs and spleen. By Dr. H. M. Fisher 26
3. Cancer of the liver. By Dr. H. M. Fisher 27
4. Carcinoma of stomach and ovaries. By Dr. W. T. Eskridge . 28
5. Small spindle-celled sarcoma of the rectum. By Dr. W. G. MacConnell 31
6. Case of typhoid fever, with abortion in the third month; death; ulceration of Peyer's patches and highly fatty kidneys. By Dr. H. M. Fisher 32
7. Cylindrical-celled epithelioma of cæcum. By Dr. W. E. Hughes 33
8. Large intestines from two cases of chronic dysentery, one of them showing pseudo-polypi. By Dr. J. H. Musser 33
9 Tubercular ulcers of intestines, with perforation. By Dr. W. E. Hughes 35
10. Some statistics of hepatic diseases: an analysis of cases presented to the Pathological Society of Philadelphia from 1857 to 1881 inclusive; with a detailed study of the fatty, the cancerous, and the cirrhotic liver. By Dr. J. H. Musser 37
11. Malignant disease of the peritoneum and abdominal viscera. By Dr. J. B. Roberts 59
12. Case of epithelioma of stomach and colon, presenting singular difficulty of diagnosis. By Dr. J. H. Packard 60
13. Carcinoma ventriculi. By Dr. J. C. Wilson 61
14. A case of intestinal occlusion. By Dr. T. D. Dunn 61
15. Intestinal stricture. By Dr. E. O. Shakespeare 63
16. Encephaloid disease of the stomach. By Dr. J. K. Mitchell . 63
17. Abscess of the pancreas and thrombosis of the portal vein. By Dr. J. H. Musser 66

III. THE VASCULAR SYSTEM.

1. Absence of parietal pericardium; malposition of liver. By Dr. W. E. Hughes 73
2. Enormous hypertrophy of the heart (weighing forty-eight ounces). By Dr. C. W. Dulles 75
3. Calcified pericardium; double mitral disease. By Dr. W. E. Hughes 77
4. Atheroma, dilatation, and aneurism of the aorta; atheroma of some of its branches; death from rupture of the aneurism into the left pleural cavity; congenital deformity of the stomach; malposition of the transverse colon and right kidney; irregular shape of the kidney; anomalous origin of the renal arteries and of the ureters. By Dr. J. H. Musser 80
5. Aneurism of the left ventricle. By Dr. W. E. Hughes . . 82

PAGE

6. Rupture of one of the aortic leaflets during severe muscular strain. By Dr. M. J. Lewis 85
7. Rupture of the heart. By Dr. T. D. Dunn 87
8. Aneurisms of the aorta; empyema. By Dr. W. E. Hughes . . 88
9. Aneurism of the left ventricle communicating with the aorta. By Dr. W. E. Hughes 90
10. Notes of a case of infectious, so-called ulcerative endocarditis. By Dr. J. H. Musser and Dr. G. A. Piersol 92
11. A case of cardiac aneurism. By Dr. J. S. Neff 100
12. Heart from a case of phthisis, with mitral incompetence. By Dr. H. M. Fisher 103
13. Case of aortic and mitral incompetence. By Dr. H. M. Fisher . 105
14. Heart showing dilated hypertrophy, from a case of calculous pyelitis. By Dr. H. M. Fisher 106
15. Double aneurism of ascending and transverse aortic arch. By Dr. Henry Beates, Jr. 109
16. Aneurism of arch of aorta, with rupture into the trachea in two places and perforation of the œsophagus. By Dr. W. Osler . 110

IV. THE ORGANS OF RESPIRATION.

1. Posterior nasal hypertrophy in situ; together with an exostosis from the vomer. By Dr. Carl Seiler 114
2. On the pathology of phthisis pulmonalis and its laryngeal complications. By Dr. Carl Seiler 115
3. Phthisis with empyema. By Dr. H. M. Fisher 129
4. Pleuro-pneumonia complicated with delirium tremens. By Dr. J. H. Musser 131
5. Phthisis following empyema; amyloid kidneys; cancer of the uterus. By Dr. W. E. Hughes 132
6. General tuberculosis of serous membranes. By Dr. W. E. Hughes 134
7. Enlarged bronchial glands which had caused intrathoracic pressure. By Dr. E. T. Bruen 135
8. Carcinoma of larynx. By Dr. W. E. Hughes 136
9. Diphtheritic bronchitis; croupous pneumonia. By Dr. W. E. Hughes 137
10. Diphtheritic croup. By Dr. W. E. Hughes 138
11. The pathology of broncho-pneumonia. By Dr. Francis Delafield 139
12. Three cases of tuberculosis. By Dr. E. T. Bruen 152
13. Larynx, trachea, lungs, and heart, from a case of anginose diphtheria. By Dr. W. A. Edwards 156
14. An anomalous human lung having four lobes on the right side. By Dr. W. A. Edwards 158
15. The pneumonia-coccus of Friedländer (*Micrococcus Pasteuri*, Sternberg). By Dr. George M. Sternberg 162

PAGE

16. Notes on the morbid anatomy of pneumonia. By Dr. W. Osler 188
17. Specimens from a case of pneumonia. By Dr. M. H. Fussell . 197

V. GENITO-URINARY APPARATUS.

a. KIDNEYS, BLADDER, ETC.

1. Secondary tuberculosis of the bladder, urethra, kidney, and suprarenal body. By Dr. W. E. Hughes 200
2. Two cases of suppurative nephritis. By Dr. W. E. Hughes . . 201
3. Cystic degeneration of a fœtal kidney. By Dr. G. E. de Schweinitz 203
4. Tumor of bladder; retention of urine; false passages made by soft catheters; septic fever; death from exhaustion. By Dr. J. H. Musser 204
5. Hypertrophy of prostate gland; chronic cystitis; cystic and cirrhotic kidneys; death from exhaustion. By Dr. J. H. Musser . . 205
6. Alveolar sarcoma of the kidney. By Dr. Morris Longstreth . 206
7. Pyelonephritis and chronic parenchymatous nephritis in the same patient; complicating cystitis. By Dr. James Tyson . . 208
8. Organs from a case of parenchymatous nephritis, which was accompanied by intestinal ulcerations and pelvic abscess. By Dr. H. M. Fisher 210
9. Primary tuberculosis of the kidneys. By Dr. M. H. Fussell . 212
10. Tubercle bacilli in the urine. By Dr. W. Osler 215
11. Multiple hemorrhage of the kidney. By Dr. F. P. Henry . . 215
12. Specimens of extremely contracted kidneys By Dr. F. P. Henry 216
13. Hydatids passed with the urine. By Dr. W. Osler . . . 217

b. FEMALE ORGANS OF GENERATION.

14. Carcinoma of the uterus, fatty kidneys, and emphysema. By Dr. W. A. Edwards 218
15. Case of multiple ovarian fibro-cysts, with subperitoneal fibroids and general peritonitis. By Dr. H. M. Fisher 219
16. Cyst of broad ligament. By Dr. C. M. Wilson 222

c. MALE ORGANS OF GENERATION.

17. Carcinomatous sarcoma of the left testicle. By Dr. W. G. MacConnell 222
18. Malignant disease of the testicle tapped for hydrocele. By Dr. J. B. Roberts 224
19. Sarcoma of testicle. By Dr. G. E. de Schweinitz . . . 225
20. Sarcoma of testicle. By Dr. G. E. de Schweinitz . . . 226
21. Urethral polypi. By Dr. G. E. de Schweinitz 228

d. MAMMARY GLAND.

PAGE

22. Recurrent scirrhus of the male breast. By Dr. G. E. de Schweinitz 229
23. Spindle-celled sarcoma of the breast. By Dr. G. E. de Schweinitz 229
24. Fibroma mammæ. By Dr. W. G. MacConnell for Dr. W. H. Pancoast 230
25. A case of Paget's disease. By Dr. W. G. MacConnell for Dr. J. Hearn 230
26. Colloid carcinoma of the mamma. By Dr. W. G. MacConnell for Dr. J. Hearn 231
27. Cysto-sarcoma of the breast. By Dr. G. E. de Schweinitz . . 232
28. Sarcoma of the breast. By Dr. G. E. de Schweinitz . . . 233

VI. THE NERVOUS SYSTEM.

1. Phantom brain. By Dr. Guy Hinsdale 234

VII. ORGANS OF THE SPECIAL SENSES.

1. Necrosis of the temporal bone and brain abscess. By Dr. Guy Hinsdale 236
2. Slides from an adeno-fibroma of lachrymal gland. By Dr. G. E. de Schweinitz. 238
3. A case of mastoid abscess ending in basilar meningitis. By Dr. G. E. de Schweinitz for Dr. B. A. Randall 238
4. Two specimens of sarcoma of the choroid. By Dr. G. E. de Schweinitz 241

VIII. TUMORS NOT OTHERWISE CLASSIFIED.

1. A case of sarcoma in the anterior mediastinum. By Dr. E. T. Bruen 244
2. Tumor of the anterior mediastinum, with secondary deposits in the lungs. By Dr. J. C. Wilson 247
3. Lipoma. By Dr. J. H. Musser for Dr. T. B. Reed . . . 249
4. Cystic papillary adenoma of the neck. By Dr. J. M. Barton . 249
5. Sarcoma of skin; secondary sarcoma of liver; ovarian tumor; rapid development of hepatic symptoms; death from exhaustion. By Dr. J. H. Musser 250
6. Two cases of hypertrophied mole. By Dr. G. E. de Schweinitz . 252

PAGE
7. Sarcoma of the retroperitoneal glands. By Dr. James Tyson . 253
8. Two specimens of the recurrent "fibroid tumor of Paget." By Dr. C. B. Nancrede 256
9. Sarcoma of the thigh. By Dr. H. R. Wharton 256

IX. SPECIMENS FROM THE LOWER ANIMALS.

1. Autopsy of case of pleuro-pneumonia in a cow. By Dr. T. D. Dunn 260
2. Some studies on the micrococcus of pleuro-pneumonia of cattle. By Dr. T. D. Dunn 261
3. Acute endocarditis in a dog, with embolic infarctions in heart and kidneys. By Dr. H. M. Fisher 266

X. MISCELLANEOUS.

1. Address of the retiring President. By Dr. James Tyson . . 268
2. Case of abscess in the suprarenal capsules. By Dr. E. T. Bruen . 271
3. Address of the retiring President. By Dr. E. O. Shakespeare . 273
4. A case of general melanosis. By Dr. Carl Seiler . . . 276
5. A case of pernicious anæmia. By Dr. W. E. Hughes . . . 278

REPORTS OF THE COMMITTEE ON MORBID GROWTHS.

1. On Dr. Musser's specimen of tumor of the bladder 205
2. On Dr. Fisher's specimen of ovarian and peritoneal tumors . . 222
3. On Dr. Barton's tumor of the neck 250

ILLUSTRATIONS.

1. Drawings illustrating Drs. Musser and Piersol's paper on infectious endocarditis:
   Mitral valves, showing inflammatory outgrowths . . 94
   Tricuspid valve in longitudinal section 95
   Masses of micrococci in the substance of the valve . . 96
2. Drawings illustrating Dr. Sternberg's paper on the pneumonia-coccus of Friedländer . . . . . 165, 166, and 172
3. Drawing illustrating Dr. Edwards's specimen of anomalous lung . 281

REPORT.

I. THE OSSEOUS SYSTEM.

1. *Large spindle-celled sarcoma of lower jaw.*

Exhibited by Dr. W. G. MacConnell, for Dr. W. H. Pancoast.

The patient was a man, æt. 24 years. The growth had existed for about three years. The egg-shell crackle was readily elicited, the growth being of central origin. On section it presented a whitish appearance, and was permeated by spicula of bone.

December 13, 1883.

2. *Fracture of the base of the skull.*

Exhibited by Dr. Guy Hinsdale.

J. H. W., æt. 50 years, fell on the ice December 8, 1882, striking upon the stone pavement. The blow was received on the posterior and left side of the skull, and the skin was not broken. He was shortly afterward admitted to the Episcopal Hospital, totally unconscious. Blood was flowing from his mouth and left ear, and his nose contained clots. His pupils afforded no evidence of his condition because of an iridectomy which had been performed on both eyes some years previous. He talked incoherently, breathing was labored, and at times stertorous. Paralysis of the left leg was noted.

Blood continued to flow from the left ear, and on the second day the discharge became thin and continued serous until his death, which occurred on the eleventh day. The urine was examined several times, and found to contain sugar in moderate amount, but no albumen. Urine was passed freely. The patient never regained consciousness; he became more stupid, and paralysis of the left leg remained.

At the autopsy a superficial clot was found over the brain beneath the seat of injury. A very large clot was found over the right frontal

region beneath the membranes, and filling the sulci between the convolutions. This was the result of the counter-stroke, the force having been first received at a point diametrically opposite, and fully accounts for the left-sided paralysis. The fracture was slightly over five inches in length. It extended from a point in the left occipito-parietal suture one and a half inches behind the temporal bone, and traversed the suture, passing through the petrous portion of the temporal, the auditory canal, close to the inner side of the foramen ovale toward the foramen rotundum, where it terminated.

December 27, 1883.

---

3. *Osteomyelitis of tibia following simple fracture.*

Exhibited by Dr. C. M. Wilson.

George L., æt. 42 years, was admitted into the surgical ward of the Pennsylvania Hospital, November 26, 1883. Sixteen days previously he had been knocked down on shipboard and had sustained a wedge-shaped fracture of the tibia and an oblique fracture of the fibula of the right leg about the middle. When admitted the fragments were in malposition and partial union had taken place. There was considerable deformity, the lower fragment of the tibia being tilted up and overlapping the upper fragment. Extension by means of a footboard was made and the leg placed in a fracture box. The man was apparently making a satisfactory recovery and the limb was in a fairly good position until the afternoon of December 26, just one month after admission, when he was suddenly seized with a severe chill followed by a temperature of $103\frac{1}{2}°$ F. He complained of excruciating pain in the left shoulder-joint. The joint was painted over with iodine and enveloped in cotton. The man was given a calomel purge and placed on twenty grains of the salicylate of sodium every four hours. The next morning his temperature was $102\frac{1}{2}°$ F., and he complained of intense pain in both shoulders and elbows. The upper extremities were enveloped in cotton and the salicylate continued, the supposition being that the case was one of acute articular rheumatism, the man having been exposed to a draft. In the afternoon of this, the second day, he had another severe chill followed by an evening temperature of $104\frac{2}{5}°$ F., and at this time a presystolic mitral murmur was first heard, best at the apex of the heart. In the absence of my chief, Dr. Levis, I came to the conclusion that the case was one of acute pyæmia, and that the evidences of endocardial

trouble and the joint pains were secondary. The man was given massive doses of quinia, which reduced the temperature, and as much stimulus as he could take and digitalis to control the tumultuous action of the heart. The following morning when Dr. Levis saw the case, he agreed with this view and ordered the treatment continued. The man steadily grew worse, however, and died of exhaustion on the morning of December 30th. The post-mortem examination was made twenty-six hours after death. Rigor mortis pronounced, well-developed and well-nourished body. Fat in subcutaneous tissue very abundant, posterior portion of the body very much discolored. Extensive ecchymoses over the arms and shoulders; small patches over the abdomen and chest. Pericardium contained one and a half ounces of clear serum. There were many spots of ecchymosis over the surface of the heart. Both sides of the heart were relaxed and partially filled with post-mortem clots. The valves on the right side appeared to be normal. The aortic valve was incompetent and the free borders of the valve were roughened by recent vegetations. The valve was also slightly thickened and contracted. The mitral orifice was of normal size, the borders of the valve showed old thickening, as well as recent swelling. There was roughening present with injection, which extended pretty well over the whole auricular surface of the valve. The lining membrane of the left ventricle showed numerous spots of ecchymosis. Except these small spots of ecchymosis, there was no evidence of commencing pyæmic abscess in the organ. The tissue, however, was a good deal softened. The weight of the heart was sixteen ounces. The spleen showed nothing special to note; its weight was eight ounces. The left kidney weighed seven ounces, was somewhat swollen, but regular in outline; the tissues were slightly flabby; the capsule thickened, tearing the surface on removal; the organ was congested and the cortex somewhat swollen. The right kidney presented the same general condition; its weight was six ounces. The liver was large and swollen; its margin was rounded, and its surface mottled and marked by the ribs, the most distinctly mottled areas showing rounded patches, whitish or yellowish in the centre and surrounded by a dark red areola. On section the liver presented a homogeneous appearance and was markedly congested; its weight was four pounds four ounces. The lungs were markedly congested, but showed no other changes; no centres of solidification were detected. The base of the left lung anteriorly was bound down by pleuritic adhesions. The brain was not examined. The whole of both bones of the right leg were removed, and a section made longitudinally through the upper fragment of the tibia. The fracture was ununited and there was no evidence of callus. The periosteum tore

easily; on section the medullary cavity showed marked evidence of inflammation. There was a puffy septum of granulation tissue between the severed ends of the bone. Above, there was evidence of extravasated blood which had not been reabsorbed; and two and a half inches above the line of fracture was a small circumscribed medullary abscess. The medullary cavity was inflamed and streaked with red lines. With the exception of one case, under Dr. Longstreth's care, when he was resident in the Hospital, this is the only case of death the result of simple fracture on the records of the Pennsylvania Hospital. Such a condition as was beautifully shown in this specimen when fresh sometimes occurs from compound fractures, especially from gunshot injuries, but osteomyelitis must be a very rare sequela of simple fracture. Medullitis, even of the gangrenous variety, is sufficiently common in amputations in osseous continuity, and sometimes occurs as a result of compound fractures. Gangrenous medullitis is almost always fatal. Osteomyelitis is not necessarily fatal; the inflammation may become circumscribed, a depot of pus form, and the destructive inflammation end there; or a portion or the whole of a bone may die and be removed. But it is easy to see how a virulent inflammation, going on to suppuration, with no vent to the pus, as in this specimen, could readily give rise to septic poisoning. It is through the courtesy of Dr. Longstreth that I have been enabled to present this specimen, and I am indebted to him for valuable aid in preparing it.

Dr. Tyson said that he had seen many cases of osteomyelitis from gunshot injuries during the late war, but he could not recall a case where the medullary canal was encroached upon by a condensing osteitis, as in this specimen.

Dr. Nancrede related a case of fatal septic trouble following a simple fracture of the thigh, where the starting-point seemed to him to have been a superficial ulceration of the skin produced by the adhesive plaster. Possibly section of the bone might have revealed an osteomyelitis, but as the fracture was firmly united he thought that the skin abrasion was the starting-point, and related two cases of pyæmia produced by equally trivial causes.

Dr. Longstreth related a case seen by him when a resident physician at the Pennsylvania Hospital. The patient had a fracture of the thigh of three weeks' standing, and was apparently doing well when chills, sweats, lung consolidation, etc., ushered in a fatal attack of pyæmia. A post-mortem examination revealed osteomyelitis and general pyæmic manifestations. A possible explanation of Dr. Wilson's case was that

the patient had been on shipboard for three weeks after his injury, where the treatment must have been of the crudest description.

Dr. Eskridge called attention to the endocardial trouble found in septic disease which he had been taught, when a student, to consider as of an ulcerative form, and of fatal prognostic import. He had, however, seen two cases which presented all the symptoms of ulcerative endocarditis; but which had recovered, while in two others with a similar clinical history, post-mortem examination revealed only a simple non-ulcerative endocarditis.

Dr. Shakespeare asked whether this condensing osteitis might not have been due to a previous syphilitic trouble. *January* 10, 1884.

---

4. *Caries of the head of the humerus.*

Exhibited by Dr. C. B. Nancrede.

Anne M., æt. 17 years, was admitted to the female surgical ward of the Episcopal Hospital, May 14, 1883. One year before, she fell down stairs and struck her shoulder. She was unconscious for a short time, but was soon able to walk home. The arm did not become inflamed and seemed to the patient, well; nine months after the fall she noticed pain in the shoulder, and an elevated papule formed near the joint, which was opened at the dispensary. This relieved the pain but left a fistulous tract discharging healthy pus. She attended the dispensary until the 14th of May, when she was sent into the house, Dr. Seltzer, the assistant surgeon on duty, having touched dead bone with the probe. After admission she had pain from time to time, gradually increasing in intensity until shortly before operation. Free openings for drainage were made by Drs. Simes and Kelly. The probe detected an apparent sequestrum within the humeral head. Diagnosis: epiphyseal abscess, and strumous disease of the joint. The operation showed complete destruction of the joint; a carious and denuded humeral head, with an abscess about the epiphyseal site containing a sequestrum. The glenoid cavity was denuded of cartilage and roughened. The portions of head and shaft, such as you see, were removed, while all the glenoid cavity was cut away with the gouge forceps, except where the long head of the biceps was attached. Further details of the operation are unnecessary. The patient was practically well at the end of two weeks.

February 14, 1884.

5. *Caries of the astragalus.*

Exhibited by Dr. C. B. Nancrede.

Elwira ——, æt. 9 years, mulatto, a patient in the children's surgical ward of the Episcopal Hospital, received a slight injury of the right ankle-joint about one year ago, since which time the usual symptoms of strumous arthritis have been noted. About two months since, Dr. Packard freely opened the articulation and inserted an oakum seton. Temporary benefit ensued, but February 13, 1884, I found the bone so diseased as to demand excision. This was effected with great readiness by a semi-circular incision upon the outer side of the joint, whereby the perineal tendons were exposed, their sheath partially opened, thus admitting of their being drawn to one side, and the ligamentous structures of the astragalus easily divided. The bone was partially ankylosed to the under surface of the tibia, and nearly all of its tibio-fibular cartilaginous surfaces were bared and carious. All the other tarsal bones seemed perfectly healthy. *February* 14, 1884.

---

6. *Specimens from a case of extensive trephining of the skull.*

Exhibited by Dr. C. B. Nancrede.

These specimens, consisting of nearly the whole right squamous plate of the temporal bone, the inferior angle of the parietal, and a portion of the frontal—in other words, the anterior two-thirds of the temporal fossa, from the orbital plate nearly to the temporal ridge, and from the external angular process of the frontal to a line posterior to the external auditory meatus—were removed by me this day from a man who had been struck by an iron lever which caught his head between it and a large beam. Although the depressed area must have been fully an inch deep, he walked into the surgical dispensary of the Episcopal Hospital, presenting apparently neither motor nor sensory disturbances, pupils and tongue being normal. He was at once sent up to the male surgical ward, and I proceeded to trephine, cutting away the overhanging shelf of sound bone with the "rougeur," and thus elevating and removing over a dozen fragments of bone. The dura mater seemed uninjured. As the specimens show, the middle meningeal artery must have been

torn, but fortunately twisted in removing the fragments, as it was completely surrounded by a bony canal. One branch in the meninges was tied with a fine catgut ligature, and the wound, as well as a deep scalp cut on the opposite side, was dressed with mercuric bichloride.

February 14, 1884.

---

7. *Round-celled sarcoma of the superior maxilla; excision of that bone with the malar.*

Exhibited by Dr. C. B. Nancrede.

Thomas A., æt. 56 years, was admitted to the male surgical ward of the Episcopal Hospital in the fall of 1883, with what appeared to be an ordinary epulis of the back part of the right superior maxilla. On November 2, 1883, Dr. Packard removed the growth with the contiguous alveolar processes, and wiped out the wound with a twenty grain solution of chloride of zinc. Microscopic examination of the growth showed it to be a small round-celled sarcoma. It rapidly returned, so that in two weeks the growth was larger than when first removed. Dr. Packard removed this second growth with the outer wall of the antrum, the alveolar border, and most of the maxillary tuberosity. The wound was wiped out again with chloride of zinc solution, and all morbid tissue seemed removed, yet in less than six weeks it again began to fungate, and during the past week its enlargement could only be compared to that of a mushroom, the increase from day to day being readily perceptible. On February 27, 1884, the growth nearly filled the mouth and pharynx, and pressed upon the tongue so that deglutition was almost impossible. Accordingly, upon that day I proceeded to perform a formal excision of the upper jaw, removing also the right malar and part of the left side of the ethmoid. Owing to the efficient assistance of my colleague, Dr. Forbes, the hot iron was unnecessary, the internal maxillary being caught and tied with singularly little loss of blood. *February* 28, 1884.

8. *Specimens from a case of resection of the humerus.*

Exhibited by Dr. C. B. Nancrede.

Mary D., æt. 17 years, from whom these specimens were removed, received a severe compound, comminuted fracture of the left humerus by having her arm wound around the main shaft of the machinery of a spinning mill, on January 2, 1884. She also at the same time received several severe scalp wounds. Irrigation with bichloride of mercury solution resulted in the salvation of the arm, although in the effort the patient nearly lost her life. At the end of six weeks, no union having taken place, the ends of the fragments being necrotic, I cut down, removed the single fragment here presented, and after sawing off the ends of the main fragments, drilled and fastened them together with two stout silver wires. The whole extremity was then put up in a fixed apparatus—plaster—which was not disturbed until the irritation of the skin from pressure, etc., required it. Now, at the expiration of about five months, the fragments seem firmly consolidated, with the line of the bone apparently perfect. *June* 26, 1884.

---

9. *A case of infantile mollities ossium.*

Exhibited by Dr. Charles Meigs Wilson.

This specimen was sent to me by Mr. Dent, the editor of the English edition of *Billroth's Notes on Clinical Surgery.* The following history was also furnished by Mr. Dent:

"This specimen shows the inner vertical half of the right femur of a child æt. 16 months. There is a pseudo-fracture of the bone. The medullary canal is filled up, and a considerable deposit of enveloping callus maintains the fragments in apposition. The entire bone is unnaturally soft, and in the recent state showed this peculiarity still more strongly. The bone was removed *post-mortem* from the body of a feeble, ill-nourished child. No history of syphilis could be gotten from the parents, and the child showed no evidence of congenital syphilis. Some of the ordinary symptoms of rickets were observable—*e. g.*, bending of the ribs, general tenderness, enlargement of the wrists, etc. No symptoms of scurvy were present. It was evident that there was much more than rickets in the condition. When the child was first admitted to the

hospital there were pseudo-fractures of the right humerus and left tibia, besides the fracture of the right femur. The humerus, which was bent at a right angle, was forcibly straightened. It bent like a bar of soft metal, and remained in its new position. It was, however, put in a light pasteboard splint. Subsequently, with the removal of the splint, the bone again gradually bent, and was again forcibly straightened. While in the hospital under observation, the femora became affected in the usual place—*i. e.*, a little below the trochanter. Some swelling and tenderness were noticed, and then, although the child was kept constantly in bed, the bones became bent; ultimately, in about ten days, the pseudo-fractures became complete. Great improvement of general health, as evidenced by rapid increase of weight, resulted from treatment of rest, good diet, and cod-liver oil. The child finally died from an attack of whooping-cough, after having been under observation a few weeks."

This is a very rare form of bone disease, especially in the young. It is seen occasionally in England—never with us. The pathological changes seem to be of a retrograde character. Sometimes lipomatosis takes place. Sometimes there is a metamorphosis first to cartilage and then to embryonic tissue. This specimen shows, in different portions, both changes. The disease is attended with marked fatality. In this specimen the cortical substance is attenuated, and the medullary cavity is enormously enlarged. The bone seems deficient in lime salts. Some authorities believe that the lactic acid found in the chemical analysis of such bones is accountable for this; this fact is mentioned in order to elicit discussion. Other observers have found enormous quantities of oxalate of lime in the urine of patients with malacosteon bones. One curious fact is the effort which nature makes to repair the fractures, as shown in this specimen. This callus seems deficient in inorganic matter, and eventually becomes reabsorbed. Syphilis, scrofula, and scorbutus, have all been assigned as causes of the affection. Most authorities deny the existence of the disease in children, assign it to middle life, and speak of it as being lighted up or aggravated in women by pregnancy.

September 25, 1884.

---

10. *A case of ununited fracture of both bones of the forearm.*

Exhibited by Dr. C. M. Wilson.

This specimen was taken from an arm amputated at about the middle of the humerus. Eight months previously the girl had fallen from a

window and sustained an oblique fracture of the ulna and radius; that of the ulna being about an inch and a half, and that of the radius two inches and a half below the elbow-joint. The arm was the seat of several large ulcers and many sinuses were present. The probe detected dead bone. The specimen shows that there has been no attempt at union in the radius, but that the comminuted fragments being attached to periosteum, have not been destroyed. There has been slight union of the ulna. The cartilages have been destroyed. The joint contained pus, and the internal condyle of the humerus showed a carious condition. The patient made an excellent recovery after the operation.

November 13, 1884.

---

11. *Compound fracture of the leg and foot; amputation after one year; recovery.*

Exhibited by Dr. Guy Hinsdale.

Wm. M., æt. 35 years, while at work in a mine, was severely injured by a large mass of coal which fell upon him crushing his right ankle. The external and internal malleoli were broken and the soft tissues considerably lacerated. The patient was then transported to the Pennsylvania Hospital, Philadelphia, and placed under the care of Dr. R. J. Levis, and at the patient's urgent request conservative treatment was adopted. Drainage was provided for by means of large incisions; sinuses formed, the joint became ankylosed, and dead bone was felt in every direction. After remaining eleven months in the hospital he was discharged. He was admitted to the Episcopal Hospital in November, 1882. Sinuses extended toward the joint and behind the calcaneum. The lower extremities of the tibia and fibula were necrosed. Several attacks of erysipelas delayed operative treatment, to which the patient had consented.

January 11, 1883, Dr. C. B. Nancrede amputated the leg at the upper third, making use of a short anterior and long posterior flap, catgut ligatures, and silver sutures. The operation was done with full antiseptic precautions. The spray was from a solution of acetate of alumina equal to two and a half per cent. of saturation. The instruments were kept in a two and a half per cent. carbolic acid solution. The wound was dressed with lint saturated with the acetate of alumina solution; over that was placed carbolized gauze; then the mackintosh, which was secured by a rubber band above and by strips of plaster.

Four dressings were made under the spray, and boracic acid ointment was applied over the stump on the third and fourth dressings, which were about three days apart. In four weeks the patient was up in a chair. The most gratifying feature of the case was that at no time after the operation did the temperature rise above 98.5° F.

The specimen has been macerated and shows the original fractures with complete ankylosis of the joint. The fragment of the internal malleolus has disappeared. Above its site the bone is rough and carious. A broad osteophyte is situated on the inner side of the lower end of the bone. The tibia is firmly united to the astragalus and also to the fibula. The latter bone was fractured one and a half inches from its lower extremity. The fragments are united by a small band of bone about one-fifth the thickness of the shaft. The fragments abut firmly against the tibia, the lower fragment resting under its articular surface and being coössified with it. The upper fragment is also firmly united to the tibia. The cuboid, calcaneum, and astragalus are thoroughly co-ossified. Their surfaces, especially on the outer and posterior sides, are rough and carious. *December* 11, 1884.

---

12. *Early osteitis of the hip-joint; from a case of bilateral coxalgia.*

Exhibited by Dr. A. S. Roberts.

The patient from whom these specimens were removed entered the Children's Asylum of the Almshouse, on December 9, 1883. Three weeks later she developed a limp, without known cause, and was transferred to the surgical wards of the Philadelphia Hospital; accompanied by the following meagre record of her past history:

Mary Graham, colored, æt. 5 years, admitted into the Philadelphia Hospital on February 2, 1884. Father unknown, mother died of phthisis; she was an only child. Has been blind since infancy, from opacity of the cornea; otherwise moderately healthy, though poorly nourished. Pain in the right thigh and about the knee-joint accompanied the development of the limp.

I saw her for the first time, about two months after her admission to the hospital, in consultation with my colleague, Dr. McClellan, under whose care she had been placed, and the following notes were recorded as the result of an examination:

A poorly nourished strumous child, lame in both limbs from flexion and adduction of the thighs. An effort on our part to overcome the

deformity, revealed the presence of a marked reflex muscular spasm, limiting the range of motion at the hips to a minimum. This joint rigidity was more pronounced on the right side, likewise the accompanying muscular atrophy. An open sinus, below the right trochanter, was discharging pus freely.

The physical signs established beyond doubt the existence of double coxalgia. The clinical history pointed clearly to a duration of three and one-half months for the lesion in the right hip. A definite time could not be fixed for the commencement of the disease in the left articulation.

The urgent question at the time of consultation was the propriety of excising the right hip-joint. A consolidation of the upper lobe of the right lung, with other pronounced signs of phthisis, and the generally exhausted condition of the patient, caused me to give an adverse opinion to the proposed operation.

The patient died two months later (May 25) from general pulmonary tuberculosis.

An autopsy unfortunately could not be obtained. Dr. Parkhill, resident physician, succeeded in removing from the body the hip-joints; which I have the pleasure of exhibiting to the Society this evening.

Left hip-joint.—Upon opening the capsule about one dessertspoonful of clear straw-colored synovial fluid escaped. The synovial membranes were congested and œdematous; especially noticeable around the margins of the cartilage covering the head of the bone and in the cotyloid notch. The ligamentum teres was swollen and patulous (as though drawn out), of a pale pink color, with a few congested vessels about its insertion into the head of femur. Upon the upper surface of the femoral head the cartilage was mottled by diffuse areas of deep bone congestion.

Right hip-joint.—Presented in many respects a similar appearance, differing only in the more pronounced characters of the inflammatory process. The secretion within the capsule was sero-purulent. The ligamentum teres was destroyed, and was only existing at its points of origin and insertion. The synovial membrane was more deeply congested, and the cartilage more extensively mottled than upon the left side. The acetabulum of both articulations appeared normal.

December 11, 1884.

13. *Sarcoma of the clavicle.*

Exhibited by Dr. G. E. de Schweinitz.

This specimen was sent to me by Dr. John Ashhurst for microscopical examination, and he kindly gave me permission to exhibit it to-night. The tumor occurred in the person of a girl, S. L. B., æt. 16 years, who came to him for treatment last August. She was a somewhat frail-looking, clear-skinned blonde, whose general health up to the time of the appearance of the growth had been satisfactory. The family history was good, none of the other five children, comprising the family, presented any similar affection, nor was there any history of tumor for two generations back. The tumor began at the left sterno-clavicular joint, as a small nut-shaped swelling, having arisen without known inflammatory or traumatic origin, although, as the father stated, they always believed that the patient had in some way, unknown to herself, received an injury at this point. The growth of the tumor was rapid, and at the end of five months it stood out as a prominent swelling, as large as an orange, occupying the inner two-thirds of the clavicle, and was covered by somewhat reddened and thinned skin. Pain, although not constant, was, at times, very severe. On the 7th of last August Professor Ashhurst removed the growth, together with the inner two-thirds or three-fourths of the clavicle. Examination of the gross specimen shows it to be a spindle-shaped growth, about four inches long, three inches at its greatest breadth, and two inches deep, which has taken its origin in the medullary cavity of the bone, and gradually become surrounded by a firm periosteal capsule. The true tumor-tissue is of moderate consistence and a reddish-brown color.

Microscopic examination reveals the following points of interest: The capsule is composed of dense, fibrous tissue, from which prolongations pass, dividing the tumor into numerous spaces, which are filled with small, round, sarcoma cells. These spaces are, in many places, again divided by a delicate spindle-shaped tissue into small alveoli. In addition to the round cells, spindle-shaped cells are also seen in spots, giant cells are absent, or, at least, only a few multi-nucleated cells, relegated to the regions of the spindle cells, are noted. The tumor, I think, should be classified as a small, round-celled sarcoma, with an alveolar arrangement. If this tumor be accepted as a variety of alveolar sarcoma, it is somewhat unusual. Twice before, this evening, specimens of alveolar sarcomata of the long bones have been exhibited,

one of the femur by Dr. Nancrede, and one of the knee-joint by Dr. Formad. At that time Dr. Formad thought the variety of the sarcoma justified a rather more favorable prognosis than usual, while Dr. S. W. Gross, during the discussion, after referring to the somewhat unusual microscopical character of the tumor, thought the outlook for the patient was bad, as this variety of sarcoma is peculiarly fatal. Dr. Formad's prognosis was correct, because, in that instance, the patient was alive and well, if I am not mistaken, for some time after the operation, and may be now for aught I know. In regard to the result of the present case I am able to speak quite definitely. Although the operation was most successful, and the removal of the growth quite complete, the hemorrhage insignificant, and the recovery of the patient satisfactory, in about two months after the operation the growth reappeared, either in the old wound or about two ribs lower. In this case, then, the truth of Dr. S. W. Gross's remarks has been only too thoroughly proved.

Dr. Shakespeare said that this specimen was of interest on account of the rarity with which similar ones had been presented to the Society. Through the kindness of Dr. de Schweinitz, he had the opportunity of examining sections from the growth, and thoroughly agreed with the exhibitor as to its nature. Dr. Simes had also examined microscopic sections, and endorsed the statements made by the preceding speaker.

January 8, 1885.

---

14. *Specimens from excision of the astragalus for caries, etc.*

Exhibited by Dr. C. B. Nancrede.

Elmer ——, æt. 9½ years, had for some years suffered from characteristic symptoms of strumous disease of the astragalus, the details of which it is unnecessary to give. Early in November, 1884, he began to have chills, severe pain in the ankle-joint, which now became swollen, and soon there developed hectic and profuse diarrhœa. Although I had never been able to detect dead bone by the probe, I felt convinced that an abscess, the result of carious bone, had ruptured into the previously only slightly diseased ankle-joint. I accordingly, under ether, examined the ankle-joint, which I found contained a considerable quantity of very offensive pus, which communicated with a cavity lined with carious bone, situated between the astragalus and os calcis. I excised the astragalus, and scraped out the carious external malleolus, as well as the roughened surfaces of the tibia. The boy has since done well.

January 22, 1885.

LEWIS

15. *Synostosis of the vertebral column.*

Exhibited by Dr. A. S. Roberts.

This specimen of synostosis, or calcareous fusion, of the dorsal and lumbar vertebræ, was removed from the body of an aged man that had been sent from the Almshouse to the dissecting room of the University of Pennsylvania. The pathological character of the specimen will alone be of interest, as all facts pertaining to a personal or clinical history of the individual were unobtainable.

The vertebræ, before my attention was directed to them, had been macerated and boiled, destroying thereby all evidence of the nature of the inflammatory process that caused such extensive synostosis.

In referring to the specimen, it will be noticed that the vertebral column is held in a rigid position by a deposit of calcareous plastic material that extends from the fifth dorsal to the sacrum. In the dorsal region to the right of the anterior common ligament, a broad ribbon-like band of the deposit covers the bodies of the lower seven vertebræ. The same fusion exists to the left of the median line, between the seventh and ninth dorsal. It is here interrupted by an intervertebral interspace—to appear again between the eleventh and twelfth dorsal and the first and second lumbar. The smooth plastic character of the effusion is materially altered in the lumbar region, especially noticeable between the bodies of the first, second, and third. It is here thickened and nodular, with occasional bony stalactites, markedly contrasting with the smooth ribbon-like band of the mid-dorsal.

The vertebral laminæ frequently coalesce; this is especially noticeable between the fourth and fifth lumbar and in the lower dorsal region. The cretaceous deposit has occurred in the structure of the intrinsic ligaments of the spine, or those short, firm bands that bind the approximating surfaces of the vertebræ together. Between the fourth and fifth lumbar and the attachment of the latter to the sacrum, the ligamentous structures are all involved by the deposit firmly cementing the superincumbent column to the sacrum.

The articulating facets of the vertebræ, with but few exceptions, show evidences of chalky deposit; their margins are nodular and "frilled." Between the tenth, eleventh, and twelfth dorsal the articulating facets are obliterated by ankylosis. The same fusion exists between the facets of all the lumbar vertebræ. The extremities of the lower dorsal spinous

processes and the last two lumbar are united by ossification of the supraspinous ligament.

Corresponding with this anomalous condition of the vertebral column and its articulating facets, a similar process may be noted to have occurred at the sacro-iliac juncture. The margins of the articulating plane are here encrusted by calcareous nodules. About the margins of the articulating surfaces for the heads, and tubercles of the ribs, the same encrusting chalky concretions have been deposited.

With a view to determining the nature of these plastic effusions, and in lieu of the evidence that would have established the etiology of the affection had a careful autopsy been held, I examined portions of the deposits with the nitric acid and ammonia test, with the hope of detecting the presence of uric acid. The results were negative. A crystalline structure could not be detected by microscopical examination; the mass appeared amorphous, yielding bubbles by the addition of acetic acid. It was, no doubt, largely composed of the carbonate or other salts of lime.

I think it may be inferred that the individual from whom these vertebræ were removed had been afflicted with chronic rheumatic arthritis, as the specimen at least shows the characteristic deposits of this disease. *February* 26, 1885.

---

16. *Spondylitis of the dorsal vertebræ, with miliary tuberculosis of the lungs.*

Exhibited by Dr. A. S. Roberts, for Dr. W. G. Porter.

Frederick H., a gunsmith, æt. 23 years, a native of Berne, Switzerland, was admitted into the surgical wards of the Philadelphia Hospital, under the care of my colleague, Dr. Porter, on January 9, 1885.

He complained of general malaise, great prostration after slight exertion, and a sharp, paroxysmal pain over the region of the sternum, and about the right shoulder-blade. He had always enjoyed excellent health; his parents are healthy and living. He was a moderate drinker, and denied any venereal taint.

During the latter part of August, 1884, five months before admission to the hospital, he commenced losing flesh without apparent cause. The symptom of pain soon followed, located over the ensiform appendix, and a month later he was incapacitated for work by extreme weakness. Upon date of entry a marked angular kyphos was noticed in the mid-dorsal region of the spine. Pain was now constant in anterior portion

of the chest, and greatly aggravated by motion. The vertebral column was rigid, the normal curves obliterated by spasm of the erector spinæ muscles.

One week after admission an elastic swelling appeared below the inferior angle of the right scapula; rapidly losing its circumscribed character, it spread in all directions; a month later it covered the entire posterior half of the trunk, from the spine of the scapula to the belly of the quadratus lumborum, its anterior margin being defined by a perpendicular line corresponding to the pectoral fold of the axilla.

I first saw the patient on February 13th (one week prior to his death). He had a rapid, small pulse, shallow respiration, dry, parched skin, and a temperature of 101°. The abscess had so covered the hump that it could only be detected by deep pressure. He rapidly grew weaker; morning temperature ranged between 99° and 100°, with an evening rise to 100°, 101°, and 102°. It did not vary from this range until two days before death; it then fell to normal (98°), and remained there. He died on February 20, 1885.

Dr. Shakespeare has presented the following report of the post-mortem examination:

"A large, fluctuating abscess was noticed externally, covering the posterior portion of the trunk, extending along the spinal column from the third cervical vertebra to the first lumbar. Skin covering area of distention discolored and mottled. Upon cutting into sac of abscess about one gallon of greenish, stinking, semi-purulent fluid escaped. Dorsal muscles over region of hump dissected away from the vertebræ by the burrowing of the pus, and in the main destroyed. The right scapula had likewise been separated from the trunk by the sac of the abscess pushing under its inferior angle.

"Destruction of tissue marked on right side of column. The spinous processes of the dorsal vertebræ were freely movable at apex of "hump" in all directions.

"Thorax, from within, showed firm pleuritic adhesions in each cavity, more extensive on right side. Lobes of right lung firmly bound together. One or two small normal areas at apex; lung tissue mainly crepitant throughout. Cut surface exhibits cavities in upper lobe. The balance of lung tissue of each lobe studded with gray tubercles. Left lung is in a similar condition, with extensive congestion. Bronchial glands not enlarged. Heart and pericardium normal.

"Liver small, color red; appearance of cut surfaces normal; numerous diaphragmatic adhesions; capsule thickened irregularly. Gall-bladder normal. Spleen flabby, numerous adhesions to diaphragm, with

evidence of peritonitis; dark maroon in color, slightly mottled. Pulp soft, size normal.

"Kidneys slightly enlarged. Capsule readily stripped, leaving a pinkish-gray surface, with some injection of vessels between the 'pyramids of Ferrein.' Cut surface shows cortex thicker than normal, medullary portion pink in color.

"Vertebral column: the sac of the abscess within the thorax occupied the region of the mediastinum. It covered the bodies of all the vertebræ from the second to the tenth dorsal. The anterior common ligament was destroyed; caries had eaten away the greater portion of the bodies of the seventh and eighth dorsal. The heads of the ribs articulating upon these vertebræ were loose in the sac of the abscess.

February 26, 1885.

---

17. *Chronic knee-joint disease followed by acute inflammation.*

Exhibited by Dr. H. R. Wharton.

The patient from whom this specimen was removed, was a man æt. 40 years, who three years before had received a slight injury of the right knee, which caused him more or less trouble up to January, 1885. At this time while at work he twisted the affected knee; this injury was followed by an attack of acute inflammation which went on to suppuration and destruction of the cartilages. The patient when admitted to the hospital had a high temperature, profuse sweats, and a rapid and feeble pulse. His condition was so urgent that it was deemed advisable to remove the part by amputation rather than to make use of the more conservative operation, excision of the knee-joint. *April* 9, 1885.

---

18. *Fracture of the pelvis; rupture of the bladder; fracture of the forearm.*

Exhibited by Dr. De Forrest Willard.

H. C., æt. 23 years, was admitted to the Presbyterian Hospital March 27, 1885, having fallen a few hours previously under a backing locomotive, which, when stopped, held him firmly fixed beneath the ash-pan. In starting the engine to extricate him, he was again rolled by this ash-pan which was not more than fifteen inches above the cross-ties. On admission no lacerations of the skin were visible, but the contusions

about the pelvis were well marked. The pubic, lower abdominal, and upper femoral regions were extremely ecchymosed. The right arm and left iliac region were emphysematous and painful. There were no evidences of urinary infiltration in the perineum or scrotum, although the latter was blackened by ecchymosis. Crepitus was marked at every movement of the pelvis. The left trochanteric region and buttock were much flatter than the right, and pressure increased the deformity so much that it seemed probable that the head of the femur could be pressed into the pelvis through the acetabulum. This was not so, as was subsequently proven, but was due to the great mobility of the anterior pelvic fragment. At least two lines of fracture could be discovered at the iliac crest and one at the pubis. Both bones of the right forearm were also broken in the lower third, and there were many contusions of the trunk. A catheter easily introduced into the bladder secured many blood-clots and about two ounces of urine. Shock was not excessive, and although the patient was restless during the night, only small doses of morphia were necessary. On the following day the mind was perfectly clear. Vomiting soon occurred, but unaccompanied by severe abdominal pain. Diligent search was made for extravasated urine, as only half an ounce was found in the bladder, but the only suspicious territory was found in the left iliac region, and here the ecchymosis and contusion were so great that no positive conclusion could be reached. Temp. 102.1° F., pulse 150. Death occurred on the third day, from peritonitis.

Post-mortem examination.—Complete separation of the symphysis pubis was found, the left fragment with its sharp end having made an opening in the anterior wall of the bladder about one-eighth of an inch in diameter, through which aperture a small quantity of urine—two or three drachms—had found its way into the connective tissue and lay just behind the symphysis. Another fracture extended from behind the anterior superior spinous process downward just behind the acetabulum, through the ischium—another ran from the centre of the crest into the obturator foramen, and the sacrum was torn from the ileum at its synchondrosis. There was blood in the peritoneal cavity, but no pus, and but little lymph. The examination showed that the small collection of urine could not have been reached by puncture, and that the small amount of urine obtained by catheterization was due to suppression and not to its extravasation. The kidneys were much congested. The fractures were undoubtedly produced by the lateral pressure in rolling which reduced the patient's transverse diameter from seventeen to fifteen inches.

Dr. Wharton said that there were several points of interest, and especially with regard to the urinary symptoms. Did he understand Dr. Willard to say that the catheter had been passed and no urine withdrawn?

Dr. Willard replied, several times, evacuating only a few drachms each time.

Dr. O'Hara asked the reporter as to the condition of the kidneys. As total suppression of the kidney secretion was evident, it would cast some light upon it to know the pathological expression of shock in the actual condition of the kidneys. Shock is very often a general and unmeaning term, but if there was an actual diseased condition, whether recent or old, it would be well to record it, in reference to the details of the case. Belfield, in *Diseases of the Urinary and Male Sexual Organs*, had to his mind negatived many cases of shock, and proved that they depend on "negative pressure" or "hyperæmia ex vacuo." Dr. Belfield seemed to the speaker to have clearly made out the matter in reference to the kidney on anatomical and pathological grounds.

Dr. Willard answered that the kidneys were very much congested.

Dr. Nancrede differed *in toto* from Dr. O'Hara in his explanation of the suppression of urine in this case. It is well known experimentally, as well as by post-mortem evidence, that in "shock" an enormous accumulation of blood in certain instances takes place in the abdominal viscera, due to paralysis of the kidney, *and this suppression takes place before any catheterization is attempted*, as was distinctly stated by Dr. Willard. In Dr. Willard's cases Dr. Belfield's "negative pressure" theory was a mechanical impossibility, as it required a previous *retention* of urine either in a bladder with healthy walls, or in one whose parietes were rigid and could not therefore collapse. Neither of these conditions obtained in the case under discussion, and the kidneys had practically ceased to secrete before any catheter was even *near* the patient for introduction, since he was admitted to the hospital *some hours* after the accident, when only "about two ounces of bloody urine" were evacuated. Even with regard to the cases where mechanical conditions were favorable for "hyperæmia ex vacuo," he doubted if this was always the correct explanation. The theory was not new, and he thought was carried far beyond its legitimate limits by Dr. Belfield, with whose work, he assured Dr. O'Hara, he was peculiarly familiar.

May 14, 1885.

19. *Osteomyelitis of the femur.*

Exhibited by Dr. De Forrest Willard.

E. H., æt. 40 years, female, had had trouble with left femur for six years; sinuses forming from time to time, and healing after many months' discharge. On admission to hospital an opening two and a half inches in length and one-half inch in width, was found upon the inside of the thigh at the lower third. The bone was thickened to twice its normal size nearly to the trochanters; many cicatrices existed at various points on the thigh. The knee-joint was not swollen or painful, but the foot could be moved through only forty degrees of the arc of a circle. The discharge from the opening was thin, yellow, and very offensive, but not excessive in amount. This sinus had been open for two years. The patient could walk but was unable to work, and suffered considerable pain. Injections of solution of chloride of zinc corrected the fetor, and as the former sinuses had healed, it was decided not to amputate, although this operation was carefully considered. The opening was accordingly enlarged, and as no sequestrum was found, but the cancellous tissue was much softened, it was gouged, and a counter-opening was made by boring through the outer shell of the condyle, a drainage tube being afterward inserted. The wound was thoroughly disinfected, and immediately closed with dry sublimate dressings. The cotton used had been prepared with a solution of the corrosive chloride, 1 part to 500, instead of 1 to 1000, as was Dr. Willard's custom. On the second day the temperature rose to 101° F., vomiting was quite constant and accompanied by great tenesmus and the frequent passage of bloody mucus. Upon opening the wound it was found that the dressings had vesicated the skin for some distance about the wound. Recognizing the symptoms as probably due to the chloride, iodoform dressings were substituted, with carbolized oil. On the fourth day, possibly by infection from a most virulent and fatal case of erysipelas, a chill occurred, followed by fever, with a temperature of $104\frac{4}{5}$° F., and upon opening the dressings an erysipelatous inflammation was found extending from the toes to the groin. The diarrhœa and vomiting had ceased. At 8 A.M. the next morning, under quinine and kairin, the temperature was 98°, but in the afternoon, after a chill, it rose to 103°, with a pulse of 160, and death took place on the sixth day after the operation. On examination, the femur from three inches below the trochanters to the condyles was found enlarged to twice its natural size, the outer shell

being firm, but the entire internal structure showing marked osteomyelitic changes. The articular cartilage of the femur was intact, but a ledge of osteophytes prevented anything more than the limited motion of the knee mentioned. There was no sloughing of the wound, and the discharge was odorless. Had amputation at the hip-joint been performed, the result would, probably, have been more fortunate.

May 14, 1885.

---

20. *Chronic osteomyelitis of the humerus, the result of compound luxation with fracture.*

Exhibited by Dr. C. B. Nancrede.

J., æt. 30 years, three months before examination had his arm caught by the belting and drawn over a large drum in a position of extreme abduction and probably of extension. The head of the bone was luxated, the greater tuberosity torn off, and the caput humeri thrust through the integument near the anterior axillary fold. When I first saw him at the Episcopal Hospital, three months after the accident, he was very pale; there was a constant discharge of pus from an opening at the site of the old wound—*i. e.*, near the anterior axillary fold, while the orifice of another deep-seated sinus was seen over the middle of the triceps or the outer side of the arm. A probe introduced into the upper sinus readily touched the denuded carious head of the humerus. I attempted to excise the head of the bone, but when prepared to saw it after its protrusion through the wound, I found such evidences of osteomyelitis as to render amputation at the shoulder-joint necessary. He did well and recovered, but even months later a sinus existed, doubtless the result of necrosis of some fragments of periosteal bone produced by that irritated structure. Had the head of the bone been excised when the man was first injured, a useful arm would have probably resulted. *May* 14, 1885.

II. THE DIGESTIVE APPARATUS.

1. *Very large ulcer of the stomach, with unusual features.*

Exhibited by Dr. C. W. Dulles.

The specimen which I have to show you came from the body of a patient of Dr. Edward L. Anderson, who had had Dr. J. H. Musser to see her in consultation during life, and who asked my assistance in making the post-mortem examination because of Dr. Musser's temporary absence from the city. To the clinical notes of Dr. Anderson and my notes of the autopsy, Dr. Musser will, no doubt, add his own impressions of the case, which has appeared to me to be of singular interest and instructiveness.

The following are Dr. Anderson's notes:

Mrs. M., æt 35 years, her husband living, the mother of five children, one of whom died of stricture of the pyloric or cardiac end of the stomach. Both her parents died before their fiftieth year.

May 12, 1883, at my first visit, she was confined to bed and stated that since the birth of her last child she had not been well, having more or less dyspepsia and growing steadily worse for the last six months. She complained of a constant burning pain in the region of the stomach which nothing seemed to relieve. She vomited daily, sometimes immediately after a meal, but oftener not until evening, when it seemed to her all the food she had taken during the day would be ejected. The matter vomited was intensely sour, dark, and frothy, having the appearance of yeast. There was always pain after vomiting, and at all times irregular pains over the abdomen. She was anæmic, emaciated, and had a weak but regular pulse. Upon physical exploration I could find no tumor. Her heart and lungs were normal, and, as I afterward learned, the urine likewise. The abdomen was resonant. She was placed on a milk diet, with pepsin and ten drops of sulphurous acid every three hours. She took two quarts of milk daily and did not vomit until the 22d of May, a period of ten days. On this day she vomited a small quantity of food. May 23, the period of her menstruation (though she did not menstruate from April until the time of her death), she ate a fritter for supper. This indiscretion brought on an attack of vomiting

and sufficient prostration to cause considerable alarm to her family and cause them to send for me. I found her much exhausted, only able to speak in monosyllables, with a pulse of 104, and respirations 40. She complained of intense, burning pain in the stomach. External heat and sulphurous acid internally gave relief. This was the first time I was able to see the vomited matter, and I found it to be digested blood, about two quarts in amount. Dr. J. H. Musser kindly examined the material microscopically and found blood corpuscles, pus globules, and epithelial cells. I was told she had vomited similar material prior to my first visit. The vomiting was repeated on May 25th, 26th, 27th, and 28th, and several times there were free hemorrhages. She was treated with bismuth and carbolic acid, with enemata of milk, whiskey, and eggs, and inunctions of cod-liver oil. Hemorrhages occurred again on June 6th, 7th, and 8th. On June 10th, Dr. J. H. Musser saw the case in consultation. He thought he detected a tumor. We came to no positive diagnosis, but wavered between carcinoma and ulcer. It was only when the patient was placed in the knee-elbow position that a tumor could be felt, and this a little to the right of the median line. The treatment was changed to one drop of hamamelis every twenty minutes, and a pill, containing one-fourth of a grain of oxide of silver, three times daily. June 17th and 18th hemorrhages again occurred, but from this time until her death, about six weeks later, there were no more hemorrhages, little inclination to vomit, and very little pain. This was notwithstanding the fact that I have reason to believe that, for about a month before her death, she paid no particular attention to her diet, while the only part of the treatment carried out was the taking of the oxide of silver pill. About three weeks before her death a troublesome cough set in, but it was easily controlled by opium. Her death followed a large meal and free draughts of coffee and water. The act of death was quiet and gradual, entirely unaccompanied by pain or alarm.

The notes of the autopsy are as follows:

September 2, 1883. Body of Mrs. M., æt. 35 years, thirty hours after death; rigor mortis absent, body much emaciated, right hand puffy with œdema, bruise over middle of right shin.

Examination of thorax, abdomen, and pelvis: There was no fluid in either pleural cavity. Both lungs were attached, at the upper part, to the parietal pleura by adhesions which broke down easily. The upper lobe of each lung was frothy, well solidified with chronic catarrhal deposits, and quite soft. In each upper lobe there was a cavity; that in the right lung was as large as a hen's egg, that in the left about the size of a pigeon's egg; both were ragged, and contained

dirty grayish detritus. The lower lobes of both lungs contained a number of small nodules of caseous degeneration. The heart was very small and firm, about the size of a goose's egg; its valves were normal, and it contained but a small quantity of fluid blood in its right cavity.

The abdomen contained about one-third of a pint of slightly turbid serous fluid. There was not the slightest injection of the peritoneum anywhere, nor any other evidence of peritonitis. The pelvic organs were all normal in appearance, except the uterus, which, though of normal size, was in a state of marked retroflexion. The bladder contained about two fluidounces of urine. There was no omental apron. The liver was of normal size and appearance. The gall-bladder was normal in appearance, and contained about half a fluidounce of saffron-colored bile, but no gall-stones. The spleen was normal. The kidneys were of normal size, rather hard, their capsules adherent, their surface a little granular; on section their cortex was found somewhat diminished; the suprarenal capsules were very tough, the right more so than the left. The pancreas was of normal appearance at its left end, but at its right it was attached to the stomach, and was decidedly indurated; here it was embedded in a quantity of delicate bands, which united into a bundle its own duct, the end of the ductus communis choledochus and the pyloric end of the stomach. The intestines were collapsed and empty, except the duodenum, which contained a small quantity of thick, bile-stained chyme.

The stomach itself presented features of the greatest interest. It was much enlarged by dilatation, its walls were thin and pale, its vessels along the greater curvature much enlarged, and full of dark blood; it occupied a slanting position from above downward, and from left to right; it contained about *two quarts* of grumous, sour-smelling fluid ingesta, and with this it was not nearly filled. At the upper part of the pyloric entrance it bore a firm, puckered induration, looking like a cicatrix, about two-thirds of an inch in diameter. Close by this was a large ulcer about two and a half inches long, and over an inch wide, with indurated, thickened, and in part perpendicular edges; this ulcer passed through all the coats of the stomach. Nevertheless, the large quantity of fluid contents of this viscus had not escaped from its cavity, because the ulcerated part of the stomach was applied against the adjacent pancreas, and attached to it by adhesions; this attachment, however, was extremely delicate, and would not bear the gentlest handling; it gave way while the viscera were still in the abdomen, upon an attempt being made to lift the pancreas up, while the stomach was held aside;

this disclosed what seemed to be a loose connective tissue mesh between the stomach and pancreas, in which a small quantity of the ingesta was found. The pyloric orifice of the stomach was at the edge of the induration surrounding the ulcer, and was so contracted as barely to admit the passage of a grooved director. *September* 13, 1883.

---

2. *Tubercular ulceration of the intestine, with tubercular infiltration of the lungs and spleen.*

Exhibited by Dr. H. M. Fisher.

E. H., æt. 43 years, married, was admitted to the Episcopal Hospital July 16, 1883. The following notes were taken by Dr. George M. Boyd, the resident physician:

The patient stated that she had been ill since last April. Her trouble began with vomiting and purging, which it seemed impossible to check. No cough was complained of and there appeared, on admission, to be no marked dulness on percussion over either lung, but in consequence of the patient's statements a careful physical examination of the lungs was not made. She was very pale and much emaciated. At first almost all nourishment was rejected, but, after a few days, the stomach became more tolerant of ingesta. Pain was complained of in the left inguinal region, where there seemed to be an undue degree of fulness; but the pain was relieved by poulticing, and the diarrhœa was relieved to a certain extent by opium and astringents. Four or five thin, dark, and watery passages occurred every twenty-four hours, in spite of treatment. Sometimes small clots and shreds of coagulated blood were seen in the passages.

The diarrhœa became again more profuse and the emaciation more extreme. About a week before her death the patient began to complain of cough, and auscultation then revealed tubular breathing and gurgling below the right clavicle. Death occurred on August 30th.

The post-mortem examination was made fifteen hours after death. Rigor mortis hardly yet well established. The body was extremely emaciated, the omentum being almost destitute of fat. Heart weighed four ounces, tissue pale.

The apices of the lungs presented numerous cheesy nodules, with catarrhal pneumonic thickening. The right lung presented at its apex

a cavity with smooth walls of the size of a pigeon's egg. Spleen: weight two and one-half ounces; its section shows numerous cheesy nodules.

Left kidney: weight two ounces; capsule adherent, and cortex diminished. Right kidney: weight four ounces. Liver fatty.

The small intestine was almost empty and contracted; its mucous surface was everywhere injected, and about eighteen inches from the ileo-cæcal valve it presented two or three small round ulcerations, which did not penetrate quite to the peritoneal investment. The mesenteric glands were everywhere swollen and the veins dilated. The large intestine presented throughout its entire extent thickening of its submucous layer, and other indications of chronic inflammation. The inflammation had caused, in the descending, and a portion of the transverse colon complete, or almost complete destruction of the mucous membrane for a space of about three feet. The muscular layers were thickened, and the mesenteric glands swollen, and there were some thickening and undue opacity of the walls of the vessels, but no tubercular granulations could be detected with the naked eye. *September* 13, 1883.

---

3. *Cancer of the liver.*

Exhibited by Dr. H. M. Fisher.

S. A., æt. 65 years, single, was admitted to the Episcopal Hospital July 31, 1883.

The following notes were made by Dr. Claxton, the resident physician: While at work, six weeks ago, the patient began to experience pain in the epigastric and right hypochondriac regions. Two weeks later he noticed that he was jaundiced, and that there was a lump (or swelling) in his abdomen.

Upon admission to the hospital the patient was much emaciated and very feeble; skin and conjunctivæ intensely jaundiced, of a deep saffron hue. There was marked bulging noticed in the right hypochondriac and epigastric regions; the tumor, which could be plainly felt through the thin abdominal wall, was found to extend four inches below the xiphoid cartilage, and two inches to the left of the linea alba. The mass occupying the right hypochondriac region was found to be distinctly nodulated, and very hard. Some of the nodules appeared to be umbilicated.

The patient presented a markedly cachectic appearance; tongue thickly coated with a dirty, yellowish-brown fur; his bowels were constipated

and there was anorexia. Purgation failed to influence the size of the tumor. The patient complained of insomnia, but did not seem to suffer much. Mental action was sluggish. The patient became rapidly weaker, and for fully a week before his death it was noticed that his extremities were very cold, and for three days before his death his pulse was so weak as to be almost imperceptible. Death occurred on August 16th.

The post-mortem examination was necessarily a hasty one, as the body was removed from the hospital within two hours of the patient's death. The new growths appeared to involve, however, only the liver and the pancreas; the common bile-duct was completely occluded by a hard nodular mass, which had its apparent origin in the pancreas. Above the occlusions the cystic duct and the gall-bladder were distended with dark olive-green bile.

The liver weighed five pounds six and a half ounces; section of the organ showed complete infiltration with cancer nodules, and little or no normal hepatic tissue could be seen. The spleen was markedly atrophied, weighing one and a half ounces. The kidneys were deeply stained with bile, and seemed somewhat contracted. The heart was very small, and its muscular tissue flabby. *September* 13, 1883.

---

4. *Carcinoma of stomach and ovaries.*

Exhibited by Dr. W. T. Eskridge.

Mrs. A., æt. 32 years, married, born in Germany, had done hard service work all her life. She had had two children, both living and healthy, three and two years old respectively. Her husband was a drunken, dissipated fellow. Her children were born at term. Neither she nor they presented any evidence of syphilis. She had had no abortions. Her confinements had been normal. After the first she remained in bed ten days, but after the last only five, as she was compelled to go out washing to earn bread for herself and children. Until her last confinement she had always felt well, and weighed two years ago one hundred and forty pounds, but soon after the birth of the child she began to lose flesh and strength. So far as she knew, none of her relatives had suffered from cancer or tuberculosis. In the latter part of the year 1882 she fell on her abdomen and hurt herself considerably. Soon after the accident her abdomen became painful, and began to swell. In March, 1883, she was admitted to the Episcopal Hospital. She remained in

that hospital several weeks, and during her stay there her abdomen was twice tapped, a large quantity of a straw-colored serous fluid being drawn off each time. She entered the Hospital of the Jefferson Medical College very much emaciated, July 1, 1883. Dr. Getchell twice drew off large quantities of fluid similar in appearance to that obtained from her while she was in the Episcopal Hospital. She came under my care July 17th. She was very weak, and her appetite was poor, but her stomach was tolerant, and had been so during her entire illness. Her abdomen was greatly distended, and slightly painful to palpation. No nodules could be felt in any portion of the abdominal cavity. No heart or lung trouble was detected. The urine was normal in appearance and quantity. The temperature over the abdomen was a little higher than in the axillæ, where it was 98.4° in each.

A few days later about three gallons of a yellowish serous fluid were drawn from the abdominal cavity. After the operation the abdomen was flaccid and tolerant of manipulation. A tumor just below the ensiform cartilage was felt, which was thought to be connected with the stomach. A tumor, much larger on the right side than on the left, was observed in each ovarian region. The liver and spleen presented, so far as I was able to detect, no evidence of disease. Occasionally she was troubled by diarrhœa. She grew weaker, and her abdomen more tender. She died from asthenia August 1, 1883. Her stomach remained tolerant to the last. From July 27th to August 1st, her temperature ranged from 100.4° to 102°. She was treated mainly with anodyne and supportive measures. Antisyphilitic treatment was at one time employed, but without any improvement.

Sectio cadaveris, twenty-one hours after death.—Body greatly emaciated, the adipose tissue being almost completely absorbed. Parietal layers of peritoneum thickened, opaque, and quite firmly attached to the abdominal muscles. Its internal surface was very rough, and presented a rugose appearance, almost as well marked as the mucous membrane of a healthy stomach. The rugosed surface was made up of firmly adherent lymph, and was studded throughout by deposits of pigment. The peritoneal cavity contained about one and a half gallons of a straw-colored serous fluid. The bowels were distended with gas and variegated externally by deposits of old lymph. The stomach was distended with fluid; it was very small—capacity not more than a pint; it was firmly bound to all adjacent structures by bands of old and recent adhesions; externally it presented the appearance and feel of an old cystic kidney; its length was about eight inches; greatest breadth three inches; the walls of the pyloric two-thirds of the stomach varied from three-fourths

of an inch to one-fourth in thickness, the calibre of this portion not being more than one and a half inches; the mucous surface was smoother than normal, and anæmic in appearance. While the growth encircled the stomach at its pyloric two-thirds, its thickest portion was along the lesser curvature. The walls at the cardiac end of the stomach were thinner than normal, easily torn, and presented several ecchymotic spots. The pyloric orifice was greatly dilated, and admitted all the fingers of one hand up to their second joints.

The calibre of the upper portion of the duodenum was two or three times larger than normal. The walls of the bowel at this point were thickened, but the thickening did not extend more than two or three inches, when the bowel resumed its normal appearance. General adhesions were found binding together the greater and lesser intestines, but at no point were their calibres materially lessened. The caput coli was much enlarged, and its appendix was curled upon itself, presenting a snail-like appearance. The bladder was healthy. The kidneys were nearly normal in appearance. The spleen was small, soft, and pulpy. The liver was slightly enlarged; the edges of incisions made in it were slightly prominent; the capsule was easily detached without tearing the hepatic substance; the interior of the organ was dark, pulpy, and very soft, being almost as easily torn with the finger as a healthy spleen. The gall-bladder was distended with a fluid similar in appearance to that found in the general peritoneal cavity; it also contained three angular stones about the size of a hickory-nut.

A spherical growth about five inches in diameter was connected with the right ovary. About two-thirds of the tumor were formed by a cyst, the walls of which were an eighth of an inch thick; the inner surface presented a cheesy appearance, from broken-down exuded lymph; the contents of the cyst were a dark, muddy liquid. The remainder of the tumor was made up of a caseous-like substance, in which a cyst about the size of a walnut was found. Connected with the left ovary was an ovoidal growth, about three inches in length and two in breadth. The tumor was made up of a fibro-fatty substance. The uterus was quite small, and apparently was not the seat of any disease.

The stomach seemed to be the point of chief interest in the above case. The absence of nausea, vomiting, eructations, and other symptoms of gastric indigestion in a contracted stomach, of which the pyloric two-thirds of its walls were infiltrated by a neoplastic growth, can be explained only, I think, by the presence of the enormous dilatation at the pyloric orifice. This condition of affairs permitted undigested food to pass readily from the stomach into the bowel. Gastric digestion was

apparently almost nil, the fluids in the intestine performing their own function and that of the gastric juice.

It is probable that the growth in the stomach was secondary to those of the ovaries, and that the peritonitis followed by ascites, was occasioned by the fall received eight months before the death of the patient.

September 27, 1883.

---

5. *Small spindle-celled sarcoma of the rectum.*

Exhibited by Dr. W. G. MacConnell.

J. McG., æt. 43 years, merchant, from upper portion of the State, three years ago noticed a sense of pain and discomfort which he located in the rectum and about the anus; the pain was accompanied by more or less tenesmus; he was very much constipated and had to use purgatives aided by enemas to induce a motion; bleeding rarely occurred, and when it did happen it was due to hardened fecal matter. One year after he first began to suffer, he became sick—says it was caused by an inflammation which occurred about the parts. About this time he suffered from temporary retention of urine; these attacks of retention would last from two to three days; they were repeated with varying degrees of severity from that period until the time of the operation. At the end of the second year he first noticed a tumor, which was about the size of a walnut; he discovered it by passing his finger into the rectum, a habit he had become accustomed to, with the view of relieving the pain and tenesmus he suffered.

The tumor, he states, was hard and firm, and continuously tended to enlarge until it had assumed the size presented at the time of the operation, which was about that of a small fœtal head. The tumor seemed to be slightly globular and nodulated; its attachment was sessile. Toward the last he became greatly depressed in health and spirits. He could by bearing down cause the tumor to protrude. The appearance presented might be likened to the pressure of the head on the female perineum during labor. The tumor would have weighed from one to one and a half pounds. It was soft and elastic. Microscopic examination showed it to be a small-celled spindle-celled sarcoma. *September* 27, 1883.

6. *Case of typhoid fever, with abortion in the third month; death; ulceration of Peyer's patches and highly fatty kidneys.*

Exhibited by Dr. H. M. Fisher.

L. K., æt. 43 years, married, German, was admitted to the Episcopal Hospital, September 15, 1883. The following notes were taken by Dr. George M. Boyd, the resident physician:

She stated, on admission, that she had been ill two weeks, that the trouble began with general lassitude and headache. Her bowels had been loose and she had passed blood in small quantities. The abdomen was somewhat tympanitic on percussion, and there was pain complained of on pressure over the right iliac fossa, and gurgling on pressure over this region. The patient seemed unusually prostrated. Tongue was coated with brownish fur and very dry.

September 17. Temperature this evening 103°; bowels loose; she complains of pain in both lumbar regions, apparently along the course of the colon.

19*th.* Evening, temperature 101°; heart's action weak, but otherwise seems to be doing well.

20*th.* Temperature 103°; heart very feeble and irregular. Patient presents all the symptoms of profound shock. Menstruation stated to have come on suddenly this morning with much loss of blood. Vaginal examination reveals widely open os, and large uterus. Several large clots were removed, but it was impossible to remove placenta, which was tightly adherent, Hot water injections and ergot were ordered with alcoholic stimulants, but no reaction took place and the patient died at nine o'clock the same evening.

The post-mortem examination revealed numerous enlarged and ulcerated Peyer's patches in the lower portion of the ileum, inflammation also of the solitary glands and swollen mesenteric glands. The uterus seemed about the size of a uterus at the beginning, or middle of the third month of pregnancy.

The kidneys were highly fatty.

N. B.—An embryo, it seems, had been passed, but was unfortunately thrown away by the nurse with the other discharges.

September 27, 1883.

7. *Cylindrical-celled epithelioma of cæcum.*

Exhibited by Dr. W. E. Hughes.

The patient was a man æt. 46 years, whose family history, so far as it could be learned, was good; no history of malignant disease. The only incident in his past life, bearing on the present trouble, was a frequently recurring, generally easily checked diarrhœa, with which he had been troubled off and on for years. When he came under observation he offered the usual constitutional symptoms of malignant disease. The abdomen was slightly tympanitic, but neither abnormality nor tenderness could be detected upon the deepest pressure; a very thorough examination was impossible, as the ribs extended almost to the crest of the ilia. The diarrhœa improved under treatment, but after a few days he was seized with a chill, followed by fever (temp. 102°), and died in a few hours, apparently from failure of the vital forces. In the cæcum, completely surrounding the gut, but producing no obstruction, was a ragged, ulcerated neoplasm developed apparently from the mucous membrane. Microscopical examination showed it to be a cylindrical-celled epithelioma. The other organs were comparatively healthy, but gave evidence of wear and tear, due to the exposed life the man had led as a car-driver and laborer. Sudden death is quite common in chronic diarrhœa due to cancer, possibly caused by a sudden disturbance of the vasomotor centres, the cause acting through the abdominal sympathetic.

November 8, 1883.

---

8. *Large intestines from two cases of chronic dysentery; one of them showing pseudo-polypi.*

Exhibited by Dr. J. H. Musser.

Case I.—The patient had chronic dysentery; further clinical information cannot be given. No record of autopsy preserved. The specimen is from the museum of the Presbyterian Hospital, and I present it to-night on account of its rarity. It is a part of the large intestine fourteen inches long. To the naked eye it shows thickening of the mucous and submucous layers and hypertrophy of the muscular layer. On the surface of the mucous coat innumerable polypoid growths are observed, some pedunculated, some sessile. The sessile growths are

from the size of a millet-seed to that of a chestnut, round or ovoid. The others also vary in size from a pea to a large bean; their pedicle is generally from one-sixteenth to one-eighth of an inch long. The reporter remembers seeing the specimen when recently removed and knows there were more pseudo-polypi than are here visible, many having fallen off from handling, etc.; there was scarcely any healthy mucous membrane; in this part of the intestine there was almost complete ulceration of the mucous coat. At one point a large stellate cicatrix, depressed in the centre, is noticeable, while all over the surface cicatricial lines are observed, most distinct about the bases of the growths.

Remarks.—In connection with this specimen I would like to call the attention of the members to a minute description of a similar specimen by Dr. Woodward. His article may be found in *The American Journal of the Medical Sciences* for January, 1881, and is entitled "Pseudo-polypi of the Colon; an Anomalous Result of Follicular Ulceration." According to this writer, the origin and development of these polypi are as follows: 1st. A granulating ulcerated surface of the intestine. 2d. Numerous islets of mucous membrane on this surface. 3d. "The formation of cicatricial contractions commenced in the infiltrated submucosa constricting the margins of the islets of mucous membrane, which were further transformed by hyperplastic inflammatory processes until ultimately they acquired the form of pedunculated excrescences and projected into the lumen of the intestine like so many little polypi"—being pushed out by the contraction of the connective tissue. Although the surface of the mucous membrane appeared to the naked eye healthy, with the microscope it showed it was submucous connective tissue infiltrated with lymphoid elements. The pseudo-polypi were composed of a central portion of connective tissue and a peripheral portion of diseased mucous membrane, the former continuous with the submucous layer, the latter limited to the surface of the growth. The histological changes in the mucous and submucous layers resembled those of chronic inflammation. The remainder of the bowel showed follicular ulceration. I am unable to say what was the condition of other parts of the bowel in the specimen exhibited.

Case II.—For this specimen I am indebted to Dr. Gittings, of West Philadelphia, for whom I made the autopsy. It was removed from a well-known druggist of this city who had been a sufferer from chronic dysentery for some time. The bowel affection was especially severe during the past summer. He had been ill of an acute exacerbation for about one week when Dr. Gittings was asked to see him. The symptoms were those of an acute dysentery but not alarming. The effect of the

habit of using chloroform, chloral, and alcoholics to excess, which habit he continued during his illness, complicated the clinical features. About the tenth day of his illness the typhoid state suddenly developed and he died in coma two days thereafter. His temperature was never higher than 102°; tormina and tenesmus were marked; bloody and mucous discharges were excessive.

Autopsy, eighteen hours after death.—Rigor mortis marked. Body well nourished. On section the abdominal walls were loaded with fat, and large deposits of this tissue were found in the great and lesser omentum, the mesocolon, and the epiploic appendages. The mesenteric and lumbar lymphatic glands were not enlarged. The cæcum was surrounded by old lymph, the appendix bound down by adhesions and thickened. The cæcum was dilated, the transverse and descending colon contracted; the walls of the entire colon were thickened. On opening the large intestine it was found to be extensively ulcerated. The mucous membrane and the ulcers were strikingly anæmic and of a pale cream color; there were no points of hemorrhage. The walls were thickened; the mucous membrane swollen; the ulcers were most numerous and largest in size at the cæcum. The smaller ulcers were the size of a dime; some of the larger extended around the gut, and were one-half of an inch to an inch wide. The edges of the ulcers were regular, bevelled, and thickened, the floor rather clean; the deepest did not extend beyond the muscular coat, the more superficial included only the mucous membrane. The larger ulcers were on the top of the folds of the intestine. A tenacious, thick mucus covered alike the ulcers and the adjacent structures. Microscopical examination revealed the changes in the intestine to be those of chronic inflammation and that the ulceration was of a simple nature and not due to tubercle.

The liver was enlarged and fatty. The kidneys were markedly cirrhotic. The spleen was normal. The heart was slightly hypertrophied.

November 22, 1883.

---

9. *Tubercular ulcers of intestines, with perforation.*

Exhibited by Dr. W. E. Hughes.

William T., white, æt. 30 years, was admitted to the University Hospital, April 16, 1883. His mother and a sister died of phthisis. He always took cold easily and was never strong. Two years ago, after lifting a heavy weight, he had several slight pulmonary hemorrhages, but

no cough. Four months before admission he took a heavy cold. From that time up to his admission he had a dry, hacking cough with mucous expectoration, some dyspnœa, pleuritic pains on the right side, and a few small hemorrhages. He lost in weight twenty pounds. On admission there was in the lower part of the right pleural cavity an effusion localized in the posterior half. Over the lung of that side the respiration was somewhat roughened, with an occasional bronchitic rhonchus. The left lung was normal. Under treatment the effusion subsided, but consolidation commenced at the apex of the lung. The consolidation went on to breaking down and the same process commenced at the left apex. He gradually failed, with the usual phthisical history. One month before death uncontrollable diarrhœa developed with severe colicky pains and intense tenderness throughout the abdomen. He died December 26th, of gradually increasing asthenia.

Autopsy, three hours after death. — Great emaciation. The right pleural cavity was completely obliterated by firm old adhesions; on the left there were some adhesions at the apex; no fluid. The right lung had numerous small cavities in the apex, the lower two lobes were riddled with miliary tubercles and small cheesy masses. The left lung was at the apex indurated with tubercular and cheesy deposits, in all other parts it was healthy. The bronchial glands were enlarged. The heart weighed four and a half ounces. The aorta was slightly atheromatous. The liver weighed two and a half pounds, and was somewhat nutmeg in appearance. The spleen weighed two and two-thirds ounces. The kidneys were normal in size and appearance. The intestines were everywhere adherent to each other and to the abdominal walls, and scattered through the adhesions and over the peritoneum were a few miliary tubercles. The small intestine contained tubercular ulcers strung along its length from the lower part of the duodenum to the ileo-cæcal valve. They were about as numerous in the upper part of the intestine as in the lower. Several of these ulcers had perforated the peritoneal coat, but the contents of the intestine were prevented from exuding into the abdominal cavity by adhesions which had formed around the perforations to the neighboring peritoneal surfaces. There were a few tubercular ulcers in the colon. The mesenteric glands were enormously enlarged. *January* 24, 1884.

10. *Some statistics of hepatic diseases: an analysis of cases presented to the Pathological Society of Philadelphia from* 1857 *to* 1881, *inclusive; with a detailed study of the fatty, the cancerous, and the cirrhotic liver.*

Read by Dr. J. H. Musser.

The collective method of studying disease, so much in vogue at the present time, can be resorted to in the study of pathological anatomy by utilizing fully the careful records of the past as well as by waiting for the opportunities of the future. Such studies, however, must be confined to the period which includes the employment of the instruments of precision of the present day.

The writer has been interested for some time in the study of hepatic disease. He had occasion to review all cases of such nature that were reported to the Pathological Society of Philadelphia. The following pages are the result of this study. It embraces not only an analysis of cases of actual disease of the liver, but also a study of the relation of various diseases of the economy to the hepatic structure. The period of time included in these studies is from the foundation of the Society, in 1857, to the publication of the *Transactions* in 1881, including the volume of that year.

In the various reports to the Society the condition of the liver was recorded four hundred and thirty times—one hundred and eighty-four times as normal, and two hundred and forty-six times as having undergone some pathological change. The following classifications show the various affections causing death in which the liver was found to be normal. The first division of the table shows the cases in which hepatic disease would not generally be expected; the second, the cases in which hepatic disease is frequently found:

Table I.—Causes of Death, Liver Normal.

Disease or condition.	No. of cases.
a. Accidents and acute inflammatory disease	47
b. Aneurism and atheroma	11
Carcinoma of various organs	37
Tuberculosis and phthisis	21
Continued fevers	14
Bright's disease	7
Gastric ulcer	6
Ulceration of intestine, including rectum	6
Organic heart disease	5
Pyæmia	5
Stricture of the pylorus (fibroid)	5
Cirrhosis of the pancreas	3
b. Ovarian disease	2
Cerebral and renal embolism	2
Cerebral softening	2
Cerebral tumor	2
Cerebral abscess	2
Addison's disease	2
Hodgkin's disease	1
Syphilis	2
Diabetes mellitus	1
Purpura hæmorrhagica	1
Total	184

Now, it was found that not all the cases that were reported and would be classified under subdivision *a* yielded normal livers. In truth, the cause of death being accident, etc., in many cases the liver was found diseased. In other words, hepatic disease was present, although not recognized during life and not a secondary condition of the primary disease causing death. Table II. briefly indicates the relative frequency of the various forms of hepatic change under these circumstances.

TABLE II.—CAUSES OF DEATH ACCIDENTAL OR ACUTE DISEASES; LIVER ABNORMAL.

Disease.	No. of cases.
Fatty degeneration	15
Congestion	8
Cirrhosis	3
Nutmeg congestion	2
Total	28

It was impossible to analyze these cases to show the conditions of life previous to the accident, etc., which caused death, which conditions were no doubt the cause of the hepatic disease.

Table I. is worthy of fuller study. It is seen that there are many instances in which secondary hepatic change of some kind would be expected, such general or local disease being present. It would be of interest, therefore, to compare the hepatic changes in the more prominent of the primary hepatic conditions in order to show their relative frequency. For this purpose Table III. was constructed:

TABLE III.—RELATIVE PROPORTION OF THE NORMAL TO THE DISEASED LIVER (AND THE FORM OF DISEASE) IN VARIOUS AFFECTIONS.

	No of cases.	Liver healthy.	Fatty.	Cirrhosis.	Congestion.	Amyloid degeneration.	Anæmic.	Pigment.	Red atrophy.	Abscesses.	Gumma, syphilis.	Secondary cancer.	Tuberculosis.
Carcinoma	83	37	10	4	1	...	...	...	...	...	...	31	...
Phthisis	53	21	18	1	...	2	1	1	...	...	...	...	9
Organic heart disease	36	5	9	8	13	...	...	...	1	...	...	...	...
Pyæmia	10	5	1	...	...	...	...	...	...	4	...	...	...
Syphilis	10	2	...	2	1	...	...	...	...	...	5	...	...
Bright's disease	27	7	11	7	...	2	...	...	...	...	...	...	...
Fevers	23	14	6	1	2	...	...	...	...	...	...	...	...
Gastric ulcer	8	6	...	1	...	...	1	...	...	...	...	...	...
Ulceration of intestines	10	6	2	1	...	...	1	...	...	...	...	...	...
Diabetes mellitus	4	1	1	2	...	...	...	...	...	...	...	...	...

A closer study of the elements of Table III. presented many features of interest; and, first, the relation of carcinoma to hepatic disease will

be considered. The following table shows the relation of hepatic change to the original seat of the disease:

TABLE IV.—RELATION OF HEPATIC ALTERATION, AND ITS ABSENCE, TO THE SEAT OF CANCER.

Seat of disease.	No. of cases.	Secondary deposits.	Normal liver.	Fatty.	Cirrhotic.	Congestive.
Stomach	32	12	14	5	1	...
Pancreas	9	4	2	1	2	...
Intestines	7	1	4	2	...	...
Uterus	7	1	4	2	...	...
Œsophagus	3	...	3	...	...	...
Bladder	3	...	3	...	...	...
Kidney	2	...	2	...	...	...
Peritoneum	4	1	3	...	...	...
Breast	4	3	1	...	...	...
Suprarenal capsules	1	1	...	...	...	...
Mesenteric glands	1	1	...	...	...	...
Parts outside portal area other than breast	10	7	1	...	1	1
Total	83	31	37	10	4	1

It is at once observed that the ratio of infection of the liver to non-infection is about as five to three, while the ratio of the infected and the healthy livers is almost equal. We would expect, therefore, secondary hepatic carcinoma in about thirty-seven and one-half per cent. of all cases of carcinoma. It was noted that in all cases of secondary metastasis to this organ other glands were involved. The cases were too few to affirm the frequency of metastasis without hepatic involvement. Thus, the liver was normal in three instances of cancer of the stomach and one of the œsophagus in which lymphatic glands were secondarily infected. Remark, too, the frequency of infection from sources outside of the portal area—one-third of the secondary carcinomas being from that source (breast included). On the other hand, it is seen in what a large proportion of cases of carcinoma within the portal area the liver is not infected.

So infrequently was the variety of malignant disease mentioned that it is scarce worth while to estimate the ratio of metastasis of the many forms. It was learned, however, that the encephaloid carcinoma was more frequently deposited in the liver, the scirrhus next, the epithelioma next, and the colloid the least frequently.

The liver in phthisis and tuberculosis.—Fifty-three cases of phthisis are recorded in which the state of the liver was mentioned. Phthisis and tuberculosis are taken together, as it is assumed that the former is tubercular. One example of probable non-tubercular phthisis is included

—fibroid. Twenty-one times the liver was found healthy. One-half of the number had gland involvement, and six of these were examples of general tuberculosis. Of the remaining half, in four the tubercles were diffused in both lungs or other organs, six were localized to one lung. In nine cases the liver was the seat of tubercular deposit, and the same deposit was found to be universal; especially was glandular infection pronounced. It is thus seen that the liver is more likely to remain unaffected when the process is localized, and still more likely to remain so if the lymphatics escape the infiltration. Continuing the series, eighteen times the liver was fatty, twice the seat of amyloid disease, and once each cirrhotic, anæmic, and pigmented. The pigmentation in the latter instance was a coincidence, as it was due to associated malarial disease. The cirrhosis was due to the habits of the patient, and so was also coincident.

Organic heart disease.—The following will show the serious changes which take place secondary to this disease. In fact, there is no other organic disease in which the proportion of healthy to diseased liver is less than in this affection. Five times the liver was normal; nine times it presented the appearance of nutmeg-congestion; four times of ordinary congestion. Nine times it was fatty; eight times cirrhotic; once it had undergone red atrophy.

Pyœmia.—Liver healthy five times; fatty once; the seat of metastatic abscesses four times. In three of the five instances in which the liver was healthy, the lungs were the seat of a purulent deposit. Only once were the liver and lungs both affected. Thus each organ is liable to purulent infection an equal number of times, while the ratio of non-involvement to involvement of the liver is as six to four. It is worth adding to these observations that in the two cases of ulcerative endocarditis reported the liver was noted as congested and softened, and in the same number of cerebral abscess as normal, there being other purulent deposits and capillary emboli in the former cases and capillary emboli alone in the latter.

Syphilis.—The relation of this disease to liver disease cannot be truly expressed by the knowledge derived from the records of the Society. Thus, twice the liver was healthy, twice cirrhotic (intemperance combined), once congested, and five times the seat of syphilitic gummata, in ten cases of syphilitic constitution or history reported. The proportion is too high for the gumma, and hence, as it was impossible to cull every record for a syphilitic history, the statement must be received with allowance.

The relative frequency of liver disease.—This is shown by the following table, and well represents the proportion in this climate.

TABLE V.—RELATIVE FREQUENCY OF ALTERATIONS OF HEPATIC STRUCTURE.

Variety.	No. of cases.	Variety.	No. of cases.
Fatty	80	Hemorrhage into liver	2
Carcinoma	41	Pigment liver	3
Cirrhotic	38	Amyloid liver	2
Congestion	24	"Diseased" liver	3
Congestion, nutmeg	13	Leukæmic, "atrophied," red atrophy, chronic hepatitis, cavernous angioma, myeloid tumor, one each	6
Abscess	13		
Tuberculosis	9		
Syphilitic gumma	5		
Hydatid disease	4	Total	246
Rupture of liver	3		

The various accounts of the cases and the anatomical and histological appearances were so interesting that it was thought a more extended analysis of some of the more important diseases would be of value. I have therefore, carefully studied in this way the three most important classes —the fatty, cancerous, and cirrhotic cases—the results of which will appear in the second part of this paper.

Fatty Liver.

Fatty degeneration and fatty infiltration will have to be included in the following summary, as at no time were they separated in any individual report. It is presumed, however, that a fatty infiltration alone was present in those cases in which obesity was an accompaniment; and, as a table is presented showing the proportion of cases in which diminution or increase of the adipose tissues accompanied the liver change, there will be no necessity for further reference to the question. The liver was noted as fatty without any other change—at least any pathological change that exceeded the fatty—eighty times. As the liver was examined four hundred and thirty times in all, it will be seen that about nineteen per cent. had undergone this change. Again, in two hundred and forty-six cases of liver disease fatty degeneration was found in nearly thirty-three per cent. of all the cases. But then in secondary carcinoma, cirrhosis, and other pathological states the liver was also fatty, and unless this degeneration be due directly to the primary change, as in advanced cirrhosis, etc., in reckoning a percentage the frequency under these circumstances should be included. Thus, in cirrhosis of a slight degree the liver was decidedly fatty three times, in carcinoma of a similar degree eight times, raising the percentage slightly.

The causes of fatty degeneration, predisposing and exciting, will next be considered. And first as to the *age* of the patients. Arranging the cases in decades, we find that the frequency of occurrence is least at the extremes of life. The age of the patient was not given in ten of the cases, thus limiting the number analyzed to seventy. The following figures represent in their order the frequency in each decade respectively, beginning with the first—3, 3, 10, 14, 13, 14, 9, and 4; total 70. When it is remembered that the causes of fatty degeneration are more distinctly operative in the middle period of life, it will not be wondered at that the extremes are found so barren. It is interesting to study the age in connection with these causes. Without going into detail at present, we may say that in the first four decades tuberculosis or phthisis was the chief etiological factor eighteen times out of thirty. The well-known cause, intemperance, occurred eight times in forty-one cases, in the fourth, fifth, and sixth decades. As age advanced, tuberculosis gave way to carcinoma as a cause, and was found nine times in the sixth and seventh decades.

Sex.—In one case the sex was not given. In the remainder the male sex was noted forty-seven times, the female thirty-two. In the early decades—first, second, and third—the sexes were of equal frequency. In the fourth, fifth and sixth periods the males were largely in excess (twenty-eight to thirteen). In the last two periods there were nine females recorded to four males. Studying sex in relation to cause, it was found that in the cases of carcinoma the females exceeded the males, in organic heart disease the males the females; in phthisis the former were slightly in excess, while the cases in which fatty degeneration of the liver was due to the habits of the person were largely male.

Habits.—In nineteen of the cases the habits of the patient were given: in three of them as good, in sixteen as intemperate. Of the sixteen, the habits were considered as the exciting cause in ten; associated disease, together with the habits, in the remainder of the cases. Occupation had scarcely anything to do with the development of the disease, for of the twenty-five males in whom the occupation was mentioned, save soldiers (four) and sailors (six), it was duplicated only three times—farmer, huckster, and laborer. Or it may be said that twenty-one were laborers or artisans; only four were professional men or merchants. Three of the female cases had served respectively as nurse, dairy-maid, and housekeeper.

Hereditary influence.—This bore no part whatever in the development of the disease, save in one idiopathic (?) case. In the cases where any such tendency was noted, it related more especially to the primary cause of the

disease than to the liver degeneration. The same remarks apply to the presence or absence of a *diathesis* and to previous *diseases*. The latter may be modified in one or two instances, as in two cases that died of pleuro-pneumonia secondary to measles. The former affection, in all probability, shared in the production of the disorder of the liver. Finally, it was recorded individually that four of the females were married and one single, and that the colored race had but one representative out of the eighty.

Turning to a consideration of those causes which may be termed exciting, or from which the fatty degeneration developed secondarily, it is found that they are numerous as well as variable, but that in the main they corresponded with the testimony of others. In three of the cases the patients died violent deaths and the liver was found fatty. Of course, no exciting cause could be determined in these cases. It is possible that the liver was in the transition-period of fatty infiltration at the time of the accident, as in cases reported by Frerichs. As mentioned above, the habits of the individual were the sole exciting cause in ten of the cases. The associate causes of the remaining six were equally divided between phthisis, organic heart disease, and carcinoma. This latter disease was a frequent factor in the causation—ten times. Phthisis and tuberculosis occurred the most frequently, eighteen times in the eighty cases. Organic heart disease, including pericarditis and dilatation of the heart, was also potent, having been found nine times. The degeneration was secondary to carcinoma nine times. The remainder of the causes—one or two to each reported case—were those which lead to prostration and wasting of the body. One of the cases I have noted as idiopathic simply because the exact cause cannot be given. It is probable that diet and a personal tendency to fat-infiltration were the exciting causes. The specimens were presented by Dr. Thomas, and were removed by him from a man, æt. 40, who died of acute dysentery. The reporter remarked upon the absence of an exciting cause, and laid stress on the influence of the very large liver on the fatal termination of the intestinal disease. Another case is worthy of notice, the origin of which is classed as idiopathic, for the truth of the remarks of its reporter, to the effect that the degeneration preceded the general development of tuberculosis. Presented by Dr. S. Weir Mitchell, his narration of the case was that the male child, aged five and a half years, had died, after six days' illness, from an attack of vomiting and purging. The child during life was readily prostrated by a slight catarrh. At the autopsy two or three pea-sized tubercular masses were found at the apex of the right lung, but further than this the only lesions were the extreme fatty degeneration of the

liver and a considerable deposition of carbonate of lime in the renal tubules.

Another of the cases is worth placing in bold relief. It is that of a female who had been in the habit of ether-drinking. The heart was found fatty and the aorta atheromatous, in addition to the liver-change, showing the known tendency of this stimulant, used persistently, to cause degenerative changes.

Pathology and pathological anatomy.—In none of the reported cases were any remarks made upon the pathology of this disease. The results of this analysis are the only contributions that can be given to this part of the subject, and in the main they bear out the observations of others. It is interesting to read that Dr. Woodward remarked (vol. i. p. 201) that the peculiar color of the skin in the cancerous cachexia may be due to the fatty degeneration of the liver, because of its occurrence only when this alteration is present. Observation does not seem to have confirmed this statement. The cases of Mitchell and Thomas, in relation to etiology, have been alluded to. Some discrepancies appear to exist in the relative frequency of the etiological factors: thus, the male exceeded the female sex (there were eleven males to seven females that died of phthisis in some form). The females, as is well known, exceed the males under the above circumstances, and hence the apparent disagreement with the known facts. When it is remembered that the specimens are derived generally from hospital patients, where the males are always more numerous than the females, this variance is not truly correct.

It is difficult—in fact, some say impossible—to draw the line between fatty degeneration and infiltration, unless cases be followed up and a chemical analysis made. It has been said that in the former instance there is an absence of fat in other portions of the body, while in the latter it is present to a marked degree.

The following analysis of the relation between fatty liver to the presence or absence of fat in other parts of the body is presented to throw some light on the question. In twenty-eight cases of the eighty in which any facts were brought to bear on this subject the frequency of each condition was equal.

Fatty liver, with fat in other portions.—In the fourteen cases the association of this hepatic change with the deposition of fat subcutaneously or in the mesentery and other organs occurred four times in which the cause of the degeneration was alcoholism, twice each in carcinoma, phthisis, general debility from age, and chronic disease, and once each in organic heart disease and an acute disease, while in the fifteen cases in which emaciation was striking the cause of the fatty liver differed:

thus, five times it was phthisis, three times carcinoma, once each Bright's disease, erysipelas, chronic diarrhœa, diabetes, alcoholism with syphilis, and in two cases of idiopathic origin.

The well-known description of the anatomical appearances—gross and minute—was not departed from in the observations, and it is not worth while to refer to them in this paper, which is to deal with numerical statements chiefly. It may be remembered that in one of the cases the liver was "nearly white, and seemed almost like a mass of tallow." This was the only instance in which such a description was made, and, as it was probably due to the fat being chiefly stearine, it is worthy of more extended notice. The patient from whom it was removed died of cancer of the rectum at the age of 59. In addition to the fat in the liver, there was an "enormous accumulation of fat in the abdomen," and the kidneys were fattily degenerated.

In one of the cases (child, æt. 2, died from pericarditis and pleuritis) the fatty degeneration was noted in curious irregular spots of a very light color on the surface and involving the substance. In a case not included in the table (a boy, æt. 11, dying from peritonitis), the same localized degeneration was noted. These circumscribed changes are said to be due to local alteration of the circulation in the parts. It is difficult to determine the cause of such a change in the first instance. It is strange these isolated cases should be among the youngest. These changes are common in cirrhosis, amyloid disease, carcinoma, etc., of the liver, due to a similar local nutritive disturbance. In the beginning attention was called to the frequency of this association.

Concerning the degree of degeneration, it was recorded as slightly fatty eighteen times, fatty forty-six times, and very fatty sixteen times. The proportion of the cause to the degree varied very much. For instance, take the last class, and it is found that three times in typho-malarial fever, twice in carcinoma, phthisis, and organic heart disease, and once each in alcoholism, old age, gastro-intestinal catarrh, dysentery, and erysipelas, this extreme degree was noted. Belonging to the same class were two cases, one entered as of idiopathic and the other of doubtful origin. From this it is seen that the degree is not strictly related to the cause, although in deciding upon the degree the personal equation is an antagonizing factor in each case.

The size of the liver was recorded approximately thirty-one times, definitely eight times. Of the entire number, thirty-nine, thirty were classed as enlarged or large, five as very large, two as of the natural size, one as swollen, and one as small. Of the very large class, in three the cause of the degeneration was alcoholism, in one tuberculosis, and

one is recorded as idiopathic (Thomas's case). The heaviest liver weighed nine and one-half pounds. The single small liver that had undergone fatty change was removed from a female (æt. 77) who had had jaundice during life and a supposed cancerous tumor in the right hypochondrium. The duration of her illness was seven weeks. At the autopsy an enormous gall-stone (eighty-two grains) was removed from the distended gall-bladder; but it is recorded that there was no obstruction of any duct, and that the heart and kidneys were healthy, the suprarenal capsules markedly degenerated. The cause of the degeneration was probably the jaundice, especially as there was atrophy of the liver.

The size and texture of the *spleen* alternate so frequently with changes in the liver for obvious reasons, that it will be of interest to scan any related changes. This should not necessarily be the case in fatty liver; and in fact it was not the case, for in every instance in which splenic alteration was recorded it could be explained by invoking the cause of the fatty liver. Thus, it was small in cancer of the rectum; large in diabetes, typhoid fever, and dilated heart; large and soft in organic heart disease (twice), interstitial nephritis, yellow fever, and a case of general burn; soft and pulpy in yellow fever (one); soft and pale in two cases of measles. On the other hand, the times (nine) it was recorded as normal varied as much as to causation. The frequency of alteration of the kidney was great, its condition being recorded sixty times—in ten instances as healthy, ten as congested, nineteen as fatty, four anæmic, nine organically diseased (cirrhosis, etc.), three tubercular, one each as amyloid, suppurative, flabby, and "surrounded by fat." The only form of alteration of special interest in this connection is the one recorded as fatty and large. Its frequency shows the ofttimes coexistence of these similar changes in these glands, while the cause, if studied, is found to be a coincident one. Thus, tuberculosis in six, carcinoma in four, organic heart disease in five, and intemperance in two cases, and old age and extrauterine pregnancy in one each, were the exciting causes.

The other organ of the body that undergoes fatty degeneration at the same time that this process is going on in the liver—the heart, has also been studied in the instances in which its condition was recorded, with the following results. Excluding the eight cases of organic heart disease (two of which were fatty), twenty-four examples are given, which may be classified as normal in five, fatty in twelve, covered with fat in four, and hypertrophied, dilated, and small in one each of them. Of the twelve instances in which the heart was fatty, the kidney was cirrhotic four times, fatty three times, congested twice, not recorded twice, and normal once. The causes of the conjoined cardiac and hepatic change

varied very much,—twice each in alcoholism, carcinoma, and tuberculosis, and the remainder of instances in different causes. In no instance was fatty heart recorded in the clinical notes as detected during life.

The symptoms of fatty liver, even when the most pronounced, are so obscured by the more decided symptoms of the primary disorder that it is seldom any clinical note is made of them during life. Hence the paucity of observation in the cases just analyzed. Apart from the note of the size of the liver, made in only a few instances, we can contribute nothing to its symptomatology.

Carcinoma of the liver.

Forty-one instances of this affection were reported in two hundred and forty-six cases of hepatic disease. Of the forty-one, nine were primary, thirty-one secondary, and one was not classified with either division. Pursuing the same outline as when considering fatty liver, we find, in studying the causal condition, that *sex* was not a prominent factor. Thus, of the cases in which the sex was given, when primary, four were males, four females; when secondary, nineteen males and eleven females.

The *age* had much influence in the development of this disease. With the exception of one case in a child aged eighteen months and one of a female aged twenty-two years, all the primary cases occurred after forty; 3 from forty to fifty; 2 from fifty to sixty; and 1 from sixty to seventy. Save 4 cases in early adult life (twenty-seven to thirty-five), all the secondary cases occurred in the middle or later periods of life: thus, from forty to fifty, 11; fifty to sixty, 9; sixty to seventy, 4 cases; and after eighty, 1 case. Prior to forty there were three females to one male; from forty to fifty, six males to one female; from fifty to sixty, eight males to one female; from sixty to seventy, three males to one female; and the patient that was over eighty years old was a female. The females, then, were in excess in the early, the males in the later periods of life.

Neither the *occupation* nor the *habits* seemed to have any determining influence on the disease. The occupation of but one patient who had the primary disease was given—a laborer. Fifteen in whom the disease was secondary were of the lower classes of society, with the exception of a "manufacturer," who was possibly of the better class. Regarding the habits of the individuals, again but one primary case was recorded, and that one was intemperate; while four of the secondary were intemperate, two were temperate, and one was of sedentary habits. The same may be said of the *previous health*. In no instance did it have any apparent

influence. One primary and four secondary cases are recorded with previous good health; one of the secondary had had uterine disease, another rheumatism, and a third dyspepsia.

Race and *marital relations* showed similar negative influence. Two females and one male were colored. Five females and one male were married.

In the instance of *heredity* we have but little of decided value. One male, one female, and one whose sex was not recorded, in whom the disorder was primary, were noted as without hereditary tendency. The same tendency was absent in eight of the secondary cases. But two of the cases are positively affirmative. In the case of the female aged twenty-two, it was noted that her father had cancer of the breast, and in a man aged fifty-four the mother had had the disease in her face. In both the disease was primary. Compared with other statistics, these are complete: thus, of nine primary cases, heredity was noted as present or absent four times, twice in each instance. There were no cases in which nervous depression of any kind, a preëxisting constitutional change, or any previous local injury, irritation, or degeneration of the liver (in the primary cases) was recorded which could be looked upon as causal.

Pathological anatomy.—In the above remarks the term carcinoma is used in a generic sense to include all forms of malignant diseases as they are embraced clinically. The series of forty-one cases includes examples of the hard and soft, the colloid, the melanotic, and the hæmatoid cancer or carcinoma telangiectodes, and two cases of cylindrical epithelioma. To specify: five of the nine cases of the primary disease were of the encephaloid variety, one was a cylindrical epithelioma, one a hæmatoid cancer, and three were not classified. In the secondary variety twelve belonged to the encephaloid, twelve to the scirrhus groups, and one to the colloid and the melanotic; one was a cylindrical epithelioma, and three were not defined. Table VI. shows the relation of the various forms to the age and sex of the patient.

The striking feature of the table is the fact that the soft cancers are so much more frequent from forty to fifty years of age, the hard in the succeeding periods, while the epitheliomas are in the earlier periods of life.

Metastasis.—In connection with primary carcinoma of the liver, reproduction in other organs was noted in but two instances. The glands in the fissure of the liver were found to have undergone a similar degeneration in a case of encephaloid of that organ, and a tumor was found in the brain and a similar invasion of the pancreas and some mesenteric glands observed in a case of cylindrical epithelioma. In the

TABLE VI.—SHOWING THE AGE (ARRANGED IN DECADES), THE SEX, THE SEAT OF THE PRIMARY DISEASE, THE PRESENCE OR ABSENCE OF SECONDARY DEPOSITS, AND THE CHARACTER OF THE NEW GROWTH, IN CASES OF SECONDARY CANCER OF THE LIVER.

Decade.	Age.	Sex.	Seat of primary deposit.	Seat of secondary deposit in addition to liver.	Variety.
3d.	27	F.	Breast and skin.	Kidneys, mesenteric glands, and ovaries.	Epithelioma.
4th.	35	M.	Suprarenal capsule.	Mesenteric glands, lungs, and spleen.	
	31	F.	Stomach.	Mesenteric glands.	Scirrhus.
	35	F.	"	Glands of lesser curvature.	
5th.	45	M.	Pancreas.	No other secondary deposit.	Scirrhus.
	40	M.	" and mesenteric glands.	Right kidney.	Encephaloid.
	48	M.	Orbit.	Cervical and post-sternal glands.	Melanotic sarcoma.
	45	M.	Stomach.	Pancreas.	Encephaloid.
	49	M.	Pancreas.	Glands in the hepatic fissure.	Epithelioma.
	40	M.	Stomach.	Mesenteric glands.	Encephaloid.
	46	F.	Uterus.	" " and pleura.	
	46	F.	Labium.	" " and glands of groin.	Encephaloid.
	45	F.	Leg.	No other secondary deposit	"
	49	F.[1]	Skin.	Mediastinal glands, lung, and kidney.	"
	40	F.	Breast.	Uterus and pleura.	Scirrhus.
6th.	54	M.	Epithelioma of hand.	Lungs and spleen.	Encephaloid.
	58	M.	Rectum.	General.	Scirrhus and melanosis.
	56	M.	Stomach.	Mesenteric and bronchial glands.	Scirrhus.
	54	M.	"	" glands and spleen.	"
	52	M.	Kidney.	Lung.	Encephaloid.
	59	M.	Stomach and duodenum.	Mesenteric glands.	Scirrhus.
	56	M.	Stomach.	" " and pancreas.	Encephaloid.
	50	M.	"	" "	Scirrhus.
	50	F.[1]	Vagina.	Lungs.	Carcinoma gelatinosa.
7th.	66	M.	Peritoneum.	No other secondary deposit.	Encephaloid.
	62	M.	Stomach.	Mesenteric glands and glands in hepatic fissure.	Scirrhus.
	64	M.	"	Mesenteric glands and lung.	"
	65	F.	Breast.	Glands and osseous system.	"
9th.	81	F.	Pancreas.	Glands and lung.	"
No age reported.		M.	Stomach.	.....	Encephaloid.
		.....	Mesenteric glands.	No secondary deposit	
Total	31	M. 19 F. 11	.....	.....	Scirrhus . . . 12 Encephaloid . . 12 Epithelioma . . 2 Carcin. gelatinosa 1 Melanotic sarcoma 1 No character men. 3 31

thirty-one instances in which the metastatic growth was seated in the liver, the original deposit varied very much in its position. In the largest number of instances the stomach was the primary source, twelve times; ten of the twelve were males, two females. Eight of the twelve

[1] Colored.

cases were of the scirrhous variety, three of the encephaloid, and one was not recorded. In four instances in males the pancreas, in three in females the breast, was the primary seat of the disease. The remaining twelve cases had the growth in as many different organs of the body. In addition to the secondary involvement of the liver, in almost every instance other organs were included, at times the metastasis being general. The mesenteric glands were infected twenty times—six times alone, once each with the osseous system, the ovaries and kidney, the lung and kidney, the spleen, and the pancreas, twice with the pleura, and five times with the lung. Deposits were found also in the kidney and in the pancreas once each, in the lung and spleen once, and in the lung alone twice. To summarize: Along with secondary growths in the liver, similar deposits were found in other organs in twenty-six of the thirty-one instances. In only one instance was the metastasis confined to the liver, in two there is no record, and in the last of the thirty-one the condition was so remarkable as to be worthy of further notice. A case of scirrhous carcinoma of the rectum was presented, with the unusual accompaniment of universal melanosis. The melanotic deposits were found in every organ or tissue of the body, save in the brain, spinal cord, eyes, bones, joints, and muscles. Prof. Gross, Sr., the reporter, said the peculiarities of the case were the extensive distribution of the heterologous matter and the combination of melanosis with scirrhus, etc.

The above statistics correspond very closely with the facts of Frerichs. It may be said, too, that the primary foci in twenty of the thirty-one cases were in the area of the portal circulation. There were no investigations into the cause of the metastasis by any of the reporters; no record of disease of the veins or lymphatics; no observation of the track of the infective material from the original source. Studying the evidence presented, there do not seem to be any facts to warrant one assuming any but a local origin for these tumors.

Macroscopical appearances.—In every instance in which the carcinoma was primarily of hepatic origin the liver was invariably enlarged. The heaviest weighed fifteen and one-half pounds; the lightest one recorded weighed seven pounds fifteen ounces. Primary carcinoma is found in nodes, one or more in number, or as a diffused infiltration, the former appearance being in large excess. In the nine recorded cases, five were nodular, three diffused, and one not described. When in nodes, they were generally confined to one lobe, and did not amount to more than two in any cases save one, in which it was said the surface was studded with nodes, umbilicated and protruding, large in size, measuring from one-half to five inches in diameter. In one instance the node was de-

scribed as spherical, and twice as rounded. The size varied from one-half inch nodule to a mass which occupied the whole left lobe of the liver, or which contained over a quart of fluid, or to one which was five and five-eighths inches in diameter, or one the size of a large fist. One of the nodules was encapsulated; the remaining ones, though tolerably distinctly separated from the hepatic tissue, were not so circumscribed. The appearances on section, the umbilication, the character of the juice, and the retrogressive changes were the same as have been so often described. In one or two instances the extreme degree of central necrosis caused a large accumulation of fluid—one a quart, dark brown, containing pulpy masses. The reporter called attention to the resemblance to abscess. One of the masses was described by Prof. Pepper as being composed of white nodules from a pea to a walnut in size, separated by bands of hepatic tissue, the centre of which was dense and fibrous, the periphery rose-pink with purple-red, and yielding no juice on section, and no points of hemorrhage. The location of the masses varied. Two were found in the right lobe alone, one in the left, and one in both lobes. The diffused primary infiltration is rare, yet, if read correctly, three of the nine were of this variety. In one the surface was studded and the structure infiltrated with the cancerous mass—or the hepatic structure was displaced by circumscribed deposits of medullary cancerous tissue of a yellow-white color marbling the surface, rising in nodules in every direction, soft and compressible. This example probably should be classed as nodular. Again, the yellow masses ranged in size from a millet-seed to a walnut. In neither form was there a note made as to the condition of the veins or the gall-ducts.

The naked-eye appearance of the secondary carcinomatous liver varied much also. Nineteen of the thirty-one cases presented enlargement of liver, four were of normal size, and two atrophied. In one of the last instances the liver weighed one pound fifteen ounces, contained but one nodule, and showed some depressions on its surface from perihepatitis. The disease developed secondarily to carcinoma of the pylorus. Here, too, the disease appears in nodes, but they are multiple generally. In six instances, however, there was but one nodule. In other cases there were three or four (two) or "several" (two) to as many as thirty-five in one lobe, or to innumerable masses. The size varied from that of a pea to that of a cherry, a walnut, or an orange. In their gross characters the nodules resembled the nodules of primary disease. Retrograde change was frequently noted. In one case a dark brown fluid, amounting to twenty-four ounces, was taken from an irregular cavity circumscribed by a membrane of new formation.

There were two or three of the reported cases which deserve a more extended notice. One rare and curious case reported by the late Prof. Gross, which has been tabulated under the secondary variety, presented the unusual phenomena of a carcinoma coexisting with general melanosis. The patient was a male, 58 years old, who had cancer (scirrhus) of the rectum. Later the melanosis developed. At the autopsy—performed by Gross and Richardson (of New Orleans)—in addition to the scirrhus, melanotic tubercles were found underneath the skin, on the peritoneum and omentum, in the liver, pancreas, stomach, bowels, kidneys, suprarenal capsules, prostate gland, bladder, lymphatic glands of groins and pelvis, also in the lungs and bronchial glands, the heart, and thyroid gland, and a small tubercle underneath "the serous coat of the left iliac artery." Prof. Gross remarks on the great extent of the disease, and the combination of the two forms of malignant disease. (See vol. i. p. 286.)

The other example of melanotic sarcoma developed secondary to an injury to the eye. The accident occurred in 1860. In 1865 a small tumor protruded from the eyeball and was removed. Recurrence took place in two years, and its removal was repeated three times. The patient finally died of the general metastasis in 1868, over three years after the development of the primary growth.

The solitary case of carcinoma telangiectodes is very remarkable, especially in the age of the patient in whom it developed. The child was but eight weeks old; the disease was only manifested ten days before death by enlargement and increase in firmness of the abdomen. Pain was the only marked symptom. The liver, at the autopsy, was found to weigh more than eleven and one-half ounces. The capsule was smooth, the color orange yellow. The right lobe was normal. "The left lobe was the seat of a large, rounded growth, which occupied its entire extent, projecting from both surfaces. The tissue composing this mass appeared dark, in places almost blackish, through the capsule." The peritoneum was ruptured on one of its surfaces, over which was a clot of blood, while fluid blood was found in the peritoneal cavity.

The state of the tissue of the liver not invaded by the carcinoma was reported thirteen times. Eight times it was fatty, six of the times the carcinoma being of the medullary variety. Once each the organ was congested (presented the nutmeg-congestion), was cirrhosed, was pigmented, and contained a hydatid cyst.

Microscopical examination was not reported in detail in many of the cases. There were no special investigations as to the histogenesis of the carcinoma; no opinion expressed as to whether the disease developed

from the hepatic cells or the duct epithelium; nor were there any accounts of the influence of veins, arteries, ducts, or lymphatics in the metastasis, save in the perfect report of one case by Dr. Shakespeare. A few of the more complete microscopical examinations are appended.

Prof. Tyson described the microscopical picture in a case of melanosis, saying, among other things, that the pigment was free and enclosed in cells; that the cells were irregular in size and shape, shrivelled, with one nucleus, and with fat-granules; that free nuclei and free oil granules and drops were abundant, and that the pigment was in reddish flakes. The character of the pigment and its presence in the cells were specially commented upon.

The microscopical examination of the carcinoma telangiectodes was also made by Prof. Tyson. The morbid specimen was made up of a large-meshed stroma filled with blood corpuscles and cells. They, the cells, were mostly pale, faintly granular, and generally contained one indistinct nucleus. Few multinuclear cells were present, comparatively. Others of the cells were more highly granular, and others completely fatty. Some free oil was present. The tissue was vascular; there were but few pigmented cells; and the blood was in abundance, apparently outside the vessels.

The case on which Dr. Shakespeare made a microscopical report was very interesting. The primary disease was seated in the stomach, the secondary deposits were in the liver, omentum, and mesentery. On section, they presented the character of scirrhus. The cancerous growths around the vessels entering the liver developed from the endothelial coats of these vessels; and even in sections of the liver itself, to the finest ramification of the artery, this irritation could be traced. These nodules developed in the periphery of the lobe, opening from the tissue around the arterioles of the hepatic artery. The destruction of acini began in portions bounded by the arterioles.

Dr. Formad reported a case of primary cylindrical epithelioma of the liver, which, on section, showed the transformation of such process to a simple glandular carcinoma, as described by Perls.

In addition to the occurrence of secondary deposits in other organs along with similar deposits in the liver, the changes, if any, that these organs had undergone were studied with care, both in primary and secondary carcinoma of the liver. In the primary disease the condition of the spleen was recorded five times, each time as normal; the kidney, five times normal, once fatty; the heart as fatty once and normal once. The spleen was found to be healthy ten times, small twice, enlarged once, and very small once in fourteen cases of the secondary malignant disease.

Under the same circumstances the kidney was recorded normal eight times, cystic twice, and fatty and atrophied once each. In one instance there was found tubercular disease of the lungs accompanying the dissimilar new formation. The case was reported by Da Costa and Woodward, and quite a discussion arose as to the occurrence of these double lesions. In the instance in which the spleen was enlarged there were also enlarged abdominal veins, indicating obstruction in the portal circulation.

The condition of the stomach and intestines was not often recorded. It will be remembered that in twelve instances the stomach was primarily diseased. Five times the organ was noted as healthy, four times as enlarged, twice as congested, once each as inflamed, as small, as ulcerated, as the seat of melanotic tubercles, and as unusual.

In one of the cases the duodenum and small intestine were ulcerated; in another the duodenum was congested; in a third the duodenum and large intestine were highly congested.

An analysis of the symptoms is, in a measure, out of place in this pathological summary, and therefore the hasty sketch will include generally those symptoms which depend on anatomical change in the liver. It is difficult to make a comparative study of the symptoms in the secondary forms, on account of the blending of those of the original lesion with those referable to the liver. Taking the primary hepatic carcinoma for study first: in nine cases, jaundice was present in but two instances; ascites in only one, and that found at the autopsy; the abdominal veins were enlarged in one case; the spleen was not enlarged in any case; pain was present three times (severe in tumor), notably absent in two; emaciation was present in seven cases, absent entirely in one; in two instances cachexia was recorded as absent, in the remaining cases the record is negative; anæmia was noted once; weakness was explicitly recorded only once, but might be inferred in most of the cases; nausea and vomiting each occurred once; the bowels were normal in three, diarrhœa was present in two cases, and intestinal hemorrhage in one case. The most characteristic phenomenon was the change in the shape or size of the liver. Five times out of nine this organ was enlarged, twice it was enlarged and nodular, once it was enlarged hard, and nodular, and once it was recorded as a tumor in the right hypochondrium. Practically, therefore, we may consider that emaciation and prostration, enlargement and nodular bossilation of the liver, with jaundice in a few instances, are the only common signs and symptoms of primary carcinomatous disease of that organ.

The symptoms of the secondary variety could generally be traced as

depending upon the primary lesion. Thus, the jaundice, which occurred five times, was due to the involvement of adjacent organs, as the pancreas, lymphatic glands, or stomach. Ascites was absent nine times, present five times, and its presence could be explained by similar lesions as in jaundice. The spleen was not enlarged. The outline was similarly changed as in the primary disease in twelve of the cases. Emaciation was present seventeen times in the thirty-one cases, prostration in almost as many, while the cachectic appearance was recorded in but three instances, and in two of these the liver was fatty. (See Woodward's remarks on fatty liver.)

It is difficult to determine the duration of the carcinoma at its best, and when histories are not as complete as they should be, nothing but general results can be obtained.

Cirrhosis of the Liver.

The following remarks are based on an analysis of thirty-eight cases of this affection, representing the number of cases reported to the Society in which the chronic inflammation was more decided than any other lesion. Thus, of the eighty examples of fatty liver, in six cirrhosis was also present, but entirely subsidiary to the fatty changes. Dr. Fagge[1] has said that cirrhosis occurs much more frequently than we would expect from the number of times we are brought in contact with it at the bedside. In other words, often serious and extensive granular degeneration of this organ occurs without producing any signs or symptoms. The following analysis supports this view. Thus, seventeen times out of thirty-eight there were no symptoms of the hepatic disease, the patients having died of other affections, acute or chronic. To these must be added four instances in which the hepatic symptoms were present to a minor degree and might have been caused by the more serious accompanying affection which caused death. These symptoms were ascites and jaundice, the latter occurring but once in the four—in a case of cancer of the kidney. The ascites occurred in that case and also in the three remaining cases—two of organic heart disease and one of cancer of the pancreas. It is thus seen that twenty-one times in thirty-eight the disease was without symptoms. The remaining cases, seventeen in number, presented the symptoms of cirrhosis and were recognized as such during life.

Taking the entire number, the ages varied very much, but the time of most frequent occurrence was from the thirtieth to the sixtieth year.

[1] Guy's Hospital Reports.

The table following gives the exact number of cases in each decade. The age was not recorded in two of the cases.

2	from	10	to	20	12	from	50	to	60
2	from	20	to	30	3	from	60	to	70
6	from	30	to	40	4	from	70	to	80
7	from	40	to	50					

The youngest subject was nineteen, the oldest seventy-six. Of the uncomplicated cases, the same proportion to each decade occurred. The ratio of males to females varied very much, there being thirty of the former to eight of the latter. Curiously, nearly half of all the females (three) were over seventy years of age. In all of them, as in the male of that age, the disease occurred concomitantly with disease of other organs, and was a part of the ageing process in all probability. The male was, however, also an alcoholic.

Further study of the predisposing and exciting causes of the disease confirmed the well-known influence of intemperance in this connection. It was distinctly recorded that nineteen of the cases gave a history of intemperance. Two of the intemperate had syphilis, two had organic heart disease, one each had interstitial nephritis, general atheroma, cancer of the pancreas, and similar disease of the kidney. The syphilis, the heart disease, and the carcinoma might have been coexisting causes; the nephritis and atheroma were results of the same cause. The eleven remaining intemperate cases were examples of simple, uncomplicated cirrhosis. Four of the remaining thirty-eight were temperate. The exciting cause in these cases was as follows: in one malaria; in one malaria and organic heart disease; in one female, seventy-three years old, the hepatic disease was a part of a general sclerosis and degeneration; and in another, though but fifty-eight, the disease probably was part of the same process, the kidneys being associated. Nineteen, then, were intemperate, four temperate, and fifteen were not classified. Five of these cases died of acute disease, and there is nothing in the history by which to judge as to the cause. Of the final ten, organic heart disease was the cause of the death of five, diabetes of two, carcinoma of the pancreas, carcinoma cf the stomach, spinal caries, and tuberculosis of one each.

Neither the occupation, the family history, nor the occurrence of previous disease had anything to do with the development of the disease in any instance. In no instance was there any note of obstruction in the hepatic duct being the primary cause.

Pathological anatomy.—The *size* of the liver varied. Ten times it was small or contracted, nine times enlarged, and four times normal or

thereabouts. The largest weight that was given was five pounds, the smallest two pounds two and a half ounces. In one the liver was reduced to the size of two fists, and its left lobe was almost entirely gone. The descriptions of the appearance of the liver varied very much. It was described as completely cirrhotic, four; cirrhotic, thirteen; slightly cirrhotic, two; cirrhotic and fatty, four; in the first stage of cirrhosis, three; and hob-nailed in appearance, four.

The following terms were applied to individual organs to mark their appearance: granulated, nutmeg appearance, the seat of fibrous deposit, nodular, firmly nodulated, irregular in outline, and granular. In one instance there was a combination of cirrhosis and hydatid disease. The *color* was described as brown-yellow in one instance. The *capsule* was noted as thickened, or opaque. The *consistence* was stated as hard, three; firm, three; elastic, one; dense, one; and tough, one. On section, one noted a creaking sensation.

The *spleen* varied considerably in size, the alteration being more noticeable in the simpler, uncomplicated forms of cirrhosis. In these cases five times it was enlarged, and three times normal; once its capsule was thickened. One of the enlarged spleens was firm, another cirrhotic, a third pultaceous. In the complicated cases the spleen was small three times, normal once. The *kidneys* in the primarily uncomplicated cases were healthy twice, cirrhotic three times, congested once, and fatty once. It was cirrhotic six times in the nineteen remaining cases, four times congested, once fatty.

The *heart* was primarily diseased seven times. In the simple cases it had undergone hypertrophy, hypertrophic dilatation, fatty degeneration, and atrophy once each. That the liver is involved in the changes described as arising from arterio-capillary fibrosis there is no doubt. In four instances this appeared to be proved, for in them all there were conjoint atheroma and cirrhosis of the kidneys, and twice the pancreas.

The influence of the obstructed circulation on the stomach and bowels was shown in a few instances. The gastric vein, a branch of the portal, it is well known, anastomoses with the veins in the lower part of the œsophagus. These veins thus in cirrhosis become varicosed; infarcts and ulcers develop; hemorrhages occur, and rarely death takes place. In two of the cases recorded this accident occurred. Thrice the stomach was ulcerated; once its mucous membrane was congested. The histological appearances were not different from those usually seen in cirrhosis. New questions were not raised, and therefore the microscopic changes will be passed by.

Symptoms.—Our analytical study of the symptoms will embrace only

the seventeen cases of simple cirrhosis previously mentioned. In the first place, the insidiousness of the disease is no more plainly seen than in the history of each individual case in reference to the occurrence of symptoms of the first stage. Only *four* times is any record made: in one case there was abdominal pain, in one failure in health, in one slight jaundice, in one biliousness.

The symptoms of the next stage are more complete. Physical examination of the liver revealed enlargement of the organ three times, and diminution in size four times. On palpation, it was determined to be "hard" once. The spleen was enlarged twice, normal twice. The autopsies showed it to be enlarged five times; hence it must have been overlooked. There were no cases in which there was enlargement of the abdominal veins. Ascites alone or with œdema was the most frequent symptom. Alone, it was recorded four times; with œdema, seven times. There was no ascites in three of the cases, and one had hydrothorax; while in two more the presence or absence of the condition was not recorded. Jaundice was marked in two instances, due to enlarged glands in the fissure of the liver probably; in a third and fourth it began during an attack of malaria, which was antecedent to the cirrhosis. Hemorrhage, both intestinal and gastric, took place in two cases. Diarrhœa occurred in six, nausea or vomiting in two, loss of appetite in three, hepatic pain in three cases, and epigastric pain in one case. Emaciation was expressly recorded three times, but could be implied much oftener; while exhaustion was not recorded, but could be inferred. This is especially true, as in every instance death was caused by the hepatic disease alone or some complication of it, as hemorrhage, except in a case which died of peritonitis.

Finally, it may be said there was no evidence to show that the hepatic diseases had any deleterious influence on intercurrent diseases, as similar lesions of the kidneys have.

From this summary of symptoms it is learned that ascites is the most common symptom of cirrhosis of the liver; that gastro-intestinal catarrhs are the next most frequent; that enlargement of the spleen and changes in the size of the affected organ succeed the catarrhs in frequency; that hemorrhages and jaundice may occur; the enlargement of the abdominal veins is not common. If with these symptoms, considered in the sequence as above, the age and habits of the patient are considered, and a degree of emaciation, prostration, and peculiar appearance of countenance taken into account, the diagnosis will not generally be difficult.

March 13, 1884.

11. *Malignant disease of the peritoneum and abdominal viscera.*

Exhibited by Dr. J. B. Roberts.

The patient, a woman of about 58 years, had, four years previous to death, an attack of what was supposed to be gastro-enteritis of malarial origin. From this she never perfectly rallied, but had four or five intestinal hemorrhages, at varying instances. The last one occurred a few weeks before death. Recently she rapidly lost strength and became emaciated. When seen by Dr. Hornet some time in December, 1883, she had a large tympanitic abdomen, and complained of a sense of tension and constipation. Jaundice, flushed cheeks, pulse 100–110, normal temperature, and a tendency to nausea and dyspnœa were the chief symptoms.

Ten days before death the thermometer in the rectum marked 103°; but stood, says Dr. Hornet, below normal in the axilla and under the tongue. Small nodules could be felt through the belly wall, which was less tympanitic than formerly. Death occurred suddenly while at stool.

Autopsy showed nothing important in the chest. The omentum and mesentery were studded with multitudes of tumors varying in size from that of a currant to that of a hen's egg. These were of globular form, firm in consistence, and on section showed a central hemorrhagic clot. The parietal peritoneum was studded with a few small ones, as was the surface of the liver. Dr. Hornet further says that he found in one part of the intestine an ulceration of the mucous membrane corresponding to an internal tumor; and a tumor on each side of the rectum high up. In one place he found a cyst with yellowish serous contents on the surface of a tumor. Most of the nodules were of a pale pink color—one noticed, however, was nearly black. I present a portion of the intestine and mesentery, and a piece of the liver with one of the secondary growths there found. *March* 27, 1884.

12. *Case of epithelioma of stomach and colon, presenting singular difficulty of diagnosis.*

Exhibited by Dr. J. H. Packard.

Dr. Packard stated that this case was placed at his disposal for report by Dr. H. M. Fisher, in whose wards at the Episcopal Hospital the man had been.

Alexander R., æt. 47 years, single, was admitted July 9, 1883. He had for about four months been unable to follow his occupation, that of a wagon-driver. No history of syphilis; none of his family are known to him to have had cancer.

His first symptom was discomfort after eating; later he had loss of appetite and pain in the stomach. Two months afterward he felt a hard, tender mass in his belly on the right of the umbilicus.

On admission the tumor seemed about the size of an orange, and was found to be on the left of the umbilicus. It was not very painful, but annoyed him. He was much emaciated, and in a cachectic state; his bowels were obstinately constipated. Under treatment his condition improved, and he gained notably in appetite and strength. Subsequently a change for the worse took place; the tumor became more painful, he lost flesh and strength, and his appetite failed. As the tumor seemed to be entirely movable, it was decided that an attempt should be made to relieve him of it, and he was transferred to the surgical ward under Dr. Packard.

October 11, 1883. After consultation an incision was made over the tumor, in a vertical direction, and the tissues carefully divided until the abdominal wall proper was reached, when it became clear that there was firm adhesion between this and the new growth for a space of several inches in every direction. The operation was, therefore, abandoned, and the wound closed. Healing took place by the first intention, and the man even thought himself to have been benefited, although this was clearly imagination on his part.

Emaciation steadily increased, and toward the middle of November the stomach became unable to retain food. From this time the symptoms progressed until death occurred, December 29th.

Upon post-mortem examination it was found that there was an epithelioma of the pylorus, which had become adherent to the transverse colon, and the disease propagated to that structure, a communication taking place between the two cavities. Subsequently, by a local perito-

nitis, the affected parts had contracted adhesions to the parietal peritoneum at the point to which they had been displaced. The mechanism of this displacement does not seem to appear clearly.

March 27, 1884.

---

13. *Carcinoma ventriculi.*

Exhibited by Dr. J. C. Wilson.

The specimen was removed from the body of A. C., æt. 58 years, a native of Ireland, and a washerwoman by occupation, who was admitted to the Philadelphia Hospital, March 6, and died June 2, 1884.

The symptoms of the disease first attracted the patient's attention six months before her admission to the hospital, and were indigestion, flatulence, acid vomiting at intervals, constipation of obstinate character; and later, starvation signs—wasting, extreme pallor, a dull, muddy skin, and great feebleness. About the time of her admission a small, hard, oblong tumor made its appearance to the right of the median line just above the navel. This tumor was movable, but not the seat of pain. In fact, pain was rarely present. Death resulted from exhaustion.

Upon post-mortem examination, the stomach was found to be greatly dilated, extending down almost to the pubes. A cancerous mass was evident from the serous surface, presenting a nodule about the size of a hen's-egg. Upon section the pylorus was found to be very much constricted from the new growth, which was a scirrhous cancer undergoing colloid change. The mucous membrane of the stomach showed numerous ecchymoses of varying extent, and the changes due to chronic catarrhal gastritis. No metastasis to other organs could be discovered, and the lymphatic glands were not enlarged. The organs were all much atrophied, otherwise normal.

Slides showing the microscopical appearance of the tumor were exhibited. *June* 12, 1884.

---

14. *A case of intestinal occlusion.*

Exhibited by Dr. T. D. Dunn.

Eliza Hazzard, colored, æt. 57 years, sent for me August 1st. She was suffering from an attack of diarrhœa, with some pain, vomiting, and epigastric tenderness. Morphia, a powder of bicarb. of soda, ipecac.,

and calomel, and externally a mustard plaster and large mush poultice were prescribed. The day following her condition was much improved, though the pulse was still weak and rapid, and tongue heavily coated; the temperature was not elevated. She was given a prescription of aromatic spirits of ammonia, wine of ipecac., and muriate of ammonium, to be taken every two hours, and remained comfortable through the day, taking some liquid nourishment, beef-tea and milk. The next day she was seized with violent pain, cramps, and vomiting, rapidly sank, and died twelve hours afterward.

Directions were left to send for me if the patient was not doing well the day after I saw her, but hoping to secure relief by use of domestic remedies, the message was not received by me in time to reach her before death. She was subject to violent attacks of indigestion, for which I had frequently attended her.

Autopsy, fifty hours after death.—The body was very thin and badly nourished; no jaundice.

Pleura slightly adherent over posterior portions of the right side.

Lungs highly pigmented.

Heart somewhat hypertrophied; no valvular disease.

Spleen atrophied and adherent to left lobe of liver, which was drawn to the left side. The liver was also extensively adherent to the omentum and diaphragm; otherwise healthy.

Stomach and *intestines* distended with gas, the mucous surface injected.

A knuckle of about eight inches of the ileum near the ileo-cæcal valve was strangulated, and was very dark and inflamed. The inflammation extended to other portions of the gut, and some lymph had been thrown out. The portion strangulated had passed through the broad ligament of the left side, and had twisted upon itself; the round ligament served as a cord, which tightly constricted it. The peritoneal covering of the uterus, broad ligaments, and pelvic walls was thickened and very rough. I think this accident can be accounted for by supposing that the pelvic peritonitis had been quite extensive, and had resulted in perforation of the broad ligament of the left side. The peristalsis accompanying the several loose movements of the bowels probably led to a hernia of the knuckle of intestine, and its subsequent twisting and strangulation. The condition of the patient when last seen, thirty-six hours before death, was so greatly improved from that of the previous day that the diagnosis of an attack of indigestion was confirmed. Had she been seen on the 3d, when the pain, vomiting, and cramps returned, and intestinal strangulation recognized, the case would have been a favorable one for laparotomy. *March* 12, 1885.

15. *Intestinal stricture.*

Exhibited by Dr. E. O. Shakespeare.

The patient was admitted to the Philadelphia Hospital one week previous to her death, under the care of Dr. Evans, the house physician. She had obstinate constipation, followed by stercoraceous vomiting. She suffered acutely, lapsed into an unconscious state, and died, all treatment proving ineffectual.

At the autopsy the thoracic organs were found apparently normal. In the right iliac fossa a lobulated tumor was apparent on opening the abdominal cavity. The colon was distended with gas in the transverse portion, and in the descending portion was narrow. The ascending and transverse portions contained hardened feces. There was a double twist of the intestine, and two strictures; one in the ileum, two inches above the ileocæcal valve, and one two inches below the valve. They would not admit the finger. There was a ring of hardened tissue in each stricture. There was congestion of the mucous membrane in the small intestine, and adhesion of the first part of the ascending colon on its under surface to the abdominal parietes. The kidneys were normal. A large tumor of the right ovary was also present, attached to the uterus.

Dr. Formad, who made the autopsy, remarked that acute peritonitis had, in this case, become chronic, and that it was the contraction which made the strictures. The cause was probably the abdominal tumor. He was not aware that there was a case on record where a tumor produced stricture. The constriction was due to outside pressure.

April 23, 1885.

---

16. *Encephaloid disease of the stomach.*

Exhibited by Dr. J. K. Mitchell.

The facts of the case from which the specimen presented to the Society was taken are as follows:

J. M., an Irish teamster, æt. 63 years, was admitted to the Episcopal Hospital, November 28, 1884. His family history was good, and the important facts in his own were that he had always been a drinking man, and had had lead-poisoning four years previously. For two months before admission he had suffered constant pain in the epigastrium. For

a week his abdomen had been swelling, and he had complained of an ache in the back. No cardiac murmur could be heard. The resonance of both lungs was generally impaired; breath sounds were absent at both bases for a space about four inches deep. There were percussion flatness and marked ægophony over the same extent of surface. A general atheroma of the vessels was present. His bowels were constipated, his urine very scanty, measuring about eighteen fluidounces daily —sometimes less—alkaline in reaction, dark colored, and malodorous. Not a trace of albumen could be found after repeated examinations by picric acid, Heller's test, or heat. After several trials, Dr. Lewis, in whose charge the patient was, found pale hyaline casts containing pus-cells.

Basham's mixture, digitalis, occasional diaphoresis produced by means of pilocarpin, elaterium to evacuate the bowels, and liquid diet made up the treatment. The man would take no solid food, but drank large quantities of milk. The œdema lessened for a time, but recommenced at the end of about six weeks, and about the same time he began to complain that everything taken into the stomach produced a painful sense of fulness. Nevertheless he continued to take from three to four quarts of milk daily. A portion of this was given to him pancreatized, and the feeling of distention was thus for a time relieved. At the end of January he had a severe and obstinate seizure of diarrhœa, and failed rapidly.

Autopsy, fourteen hours after death.—Frame emaciated; belly greatly distended. Right leg œdematous. On opening the abdomen, the omentum was found very hard, much thickened, quite white, and covered with small, pale yellow nodules closely packed together; the whole was tightly adherent to the neighboring structures, so that to move it moved both stomach and intestines. The liver was small and pale, but of natural consistence and appearance on section. The gall-bladder was firmly fastened by adhesions to the liver and to the intestines. Both kidneys were small, very little congested, the capsules easily stripped off, and, except that in each were one or two small cysts filled with clear, watery fluid, showed no signs of disease. The abdominal cavity contained about sixteen pints of clear, yellow fluid. The heart was small; its cavities were filled with little red and white clots, and the valves were all perfectly competent. The lungs were much congested at the bases, and somewhat compressed by the abdominal distention, but had no other evidence of disease.

The stomach which I here present to you was small, very hard to the touch, and externally felt rough. On opening it nearly the whole

internal surface—but more especially the posterior wall about its middle —was found covered with masses of hard, elevated nodules, grayish-red or black on their tops, with diffuse inflammation surrounding the base of each. Among these some were softer than others, and in some the most elevated portion was ulcerated. The walls of the organ were very hard and firm.

The appearance suggested to me a diffuse carcinoma, and, on making some sections and examining them microscopically, I was still more inclined to this view. Dr. F. P. Henry, who also examined some sections, found no evidences of cancer; and Dr. J. H. C. Simes also, after examining specimens, thought cancer possible, but doubtful.

The pyloric orifice does not appear closed at all, but there is a slightly increased induration about it which may prove to be the scirrhus from which the formation on the posterior walls has spread. The growth had all the macroscopic appearance of encephaloid, and occupied the more usual seat of that disease. The thickening of the walls of the stomach may too be due to that hypertrophy of the muscular coats which not uncommonly occurs when an extended growth of carcinoma exists; and adhesions such as I have described are also frequently found in such a condition.

I should like to submit the specimen for the consideration of the Committee on Morbid Growths, who will, I hope, determine its character.

Drs. Henry and Simes, having both examined sections microscopically, were unable to detect anything beyond atrophy of the glandular elements, with hyperplasia of the connective tissue.

Dr. O'Hara asked if there had been any symptoms of stomach disease.

Dr. Mitchell replied that there had been almost complete absence of stomach symptoms; the patient complained of a feeling of distention after taking food, but vomiting had never occurred, except after the administration of jaborandi.

Dr. W. A. Edwards inquired whether the nodular omental masses had been examined microscopically, and also what was the condition of the other glands throughout the body, as a knowledge of the condition of these structures would throw some light on the case.

Dr. Osler said that, in the absence of evidence of carcinoma, he thought that the case must be referred to general cirrhosis of the stomach, of which he had seen two cases—one involving the stomach alone, the other both that organ with the cæcum, and a small portion of the colon. In both cases the actual presence of carcinoma could be excluded. He thought Dr. Mitchell's case was possibly one of those rare diseases characterized by atrophy of the glands and increase of the fibrous stroma.

He thought, however, that the omental nodules should be examined, for it is well known that in some cases of carcinoma of the stomach with much thickening around the pylorus, etc., we could only be certain of the diagnosis by examination of the secondary nodules. In his cases there had been no adhesions of the stomach to other viscera.

Dr. Mitchell said that he was unacquainted with cirrhosis of the stomach, but that if his specimen were regarded as one of that disease, it left unaccounted for the actual or impending ulceration of one-third of the posterior wall of the stomach. *May* 14, 1885.

---

17. *Abscess of the pancreas and thrombosis of the portal vein.*

Exhibited by Dr. J. H. Musser.

W. B., male, æt. 42 years, born in England, single, shoemaker, was admitted to the wards of the Presbyterian Hospital, May 12, 1885, and died June 6th following. He was under the care of Dr. Patterson.

Nothing could be learned of his family history. His antecedent history, regarding health, was good; regarding personal habits, very bad. He was addicted to intemperance, and was known as a "dead beat." For years he had been an outcast; was exposed to all kinds of weather, and often for long periods was poorly nourished. The duration of the present illness is not known, but from his story and that of some cronies, he had been "going down" all spring. He had never received any injury. He was haggard and emaciated. He vomited once only, on the first day of admission. Marked ascites was observed, but nothing else noted. During the entire period he was under observation he lay in a perfectly apathetic, listless state, taking but little food and exhibiting no signs of suffering. At no time was there fever or sweats. Pain was absent. In addition to ascites, a painless, ill-defined tumor was observed in the epigastrium, and the spleen and liver were determined to be normal. The urine contained a small amount of albumen, but no casts were found. He never had any bloody discharges.

The ascites was so great as to warrant tapping, and this was accordingly done by Dr. Greenawalt, the resident physician. The abdomen was thirty-six inches in circumference at the umbilicus before tapping. Within eighteen hours succeeding the tapping, it had filled entirely, and in twenty-four hours measured thirty-six and a half inches. Without the development of further symptoms he died of exhaustion.

At the autopsy, it was learned by inspection that rigor mortis was present in only the inferior extremities, that post-mortem discoloration of the posterior portion of the trunk and the extremities, and of the neck and shoulders, was marked, that the body was emaciated and bloodless, the face bronzed, the abdomen distended, and the ankles slightly œdematous. By palpation a fixed mass was detected in the abdomen extending from the right mammary line, one inch above the umbilical level, directly across to the corresponding line on the left side. Its upper margin was not well defined, but it appeared to be two inches wide.

On section the abdominal cavity was seen to contain a large amount of clear serum, in which some lymph floated. The intestines were matted together by recent lymph; the parietal and visceral layers of the peritoneum were deeply injected, in parts the seat of small hemorrhages, in parts covered with light lymph. Corresponding to the position of the mass indicated by palpation, the omentum was found matted together with its inferior border turned upward and lying across the stomach. This organ was fixed and dilated; its inferior border extended to the umbilicus; its pyloric orifice was seen two inches below the ribs in the right mammary line. The liver occupied its normal position. The transverse colon extended across the abdomen along the lower margin of the stomach, thus permitting the omentum to occupy the position indicated above.

Further study of the relations of the abdominal organs revealed the formation of a large cavity containing about a quart of pus. This cavity was formed by the posterior wall of the stomach in front, by the pancreas, the duodenum and transverse colon below, and by an extension of the peritoneum, or rather distention, behind and above. Certainly the pus did not fill the retro-peritoneal space or extend into it, and was not in close apposition to the diaphragm or brim. It was situated in the duodeno-jejunal fossa. Adhesions prevented communication with the abdominal cavity and the retro-peritoneal space.

The above indicated collection of pus was seen to communicate with a large abscess in the pancreas. The abscess was the size of an orange and was seated in the head of the organ, its points of rupture into the duodeno-jejunal fossa being in the middle and upper part. The remainder of the pancreas was made up of dense connective tissue, throughout which were innumerable pus pockets varying from a pea to a pecan nut in size. The secreting tissue of the organ was not discernible to the naked eye. The ducts were not occluded, but rather dilated, and calculi were not present. The pus was creamy and inodorous, and did

not contain any curd-like masses. The portal vein folds of the peritoneum contained a considerable amount of fat, in which were readily detected hard cords representing branches of the superior and inferior mesenteric veins. In a section of the mesentery the vein was distinctly seen filled with clotted blood. The trunk of the portal vein was surrounded by dense fibrous tissue apparently of comparatively recent formation. The mesenteric branches, for a short distance, coursed through a similar structure. The thrombosis was due to the pressure of this adventitious formation, causing obstruction, but not occlusion, of the vein. On close examination of the portal vein its trunk was seen to contain a soft purulent clot, portions of which were free and portions adherent to the walls, which were inflamed, the intima being of a grayish-yellow color, roughened and opaque. No point of ulceration was found, and it was evident that inflammation had just commenced. The dilated hepatic branches of the portal vein were readily traced, and the same changes were present though, possibly, not so advanced. The splenic vein was partially occluded by a soft thrombus. The superior and inferior mesenteric veins were completely blocked by a firm, reddish-brown, laminated thrombus, which was removed with difficulty. In the proximal portions of the vein the centre of the clot was soft and yellow. The walls of the veins were undoubtedly thickened and the calibre increased.

The liver weighed three pounds and one ounce, and was normal in shape. The capsule was opaque, in parts thickened. On section its tissue resisted the knife, and the appearances indicated slight cirrhosis. Portions of the organ were congested. No abscesses were seen, but the portal vein, as noted above, was distinctly traceable, and almost to the periphery showed evidences of recent inflammation. Bile oozed from the cut ducts. The hepatic artery and its branches were unusually prominent. The gall-bladder was distended with unusually fluid bile; the ducts were pervious.

The stomach was dilated. The mucous membrane was intensely congested, mammillated, and in numerous points the seat of submucous ecchymosis due to infarcts. The entire surface was covered with mucus.

As previously noted, the peritoneum covering the intestines presented a high degree of inflammation. The mucous membrane of the large and small intestine was intensely congested; the glands were not enlarged; ulcers were not found; hemorrhagic infarcts were very numerous in the course of the small intestine.

The kidneys were slightly congested and fatty. The capsule was readily removed. The cortical portion was normal.

The spleen was under size, soft in texture, but apparently normal. The suprarenal bodies were normal.

The pleural cavity did not contain serum. The right lung was the seat of hypostatic congestion behind; its apex was adherent; corresponding to the adhesions, punctured cicatrices were noted, with areas of sclerosis in the parenchyma. No cavity was observed. The left lung was congested. Mediastinal glands normal. The heart weighed five and a half ounces. The posterior leaflets of the aortic valve were fused. The mitral valves were thickened, and the anterior leaflet was contracted. One leaflet of the pulmonary valve was somewhat thickened and indurated.

Brain and spinal cord not examined.

On microscopical examination the pancreas was found to be made up of old and young connective tissue; in the large interstices of the bundles of old tissue, the glandular structure of the pancreas could be readily made out, and the tubules were seen to be in a state of catarrhal inflammation. The intertubular connective tissue was crowded with young cells.

The liver was highly fatty; surrounding the portal vein a crowding of young connective tissue elements was observed, invading the interlobular spaces and extending between the hepatic cells. Sections of one of the branches of the vein which was the seat of thrombus showed an endophlebitis of somewhat long standing. The walls of this vein were thickened. The endothelial cells of the intestine were abundantly proliferated. The muscular wall was hypertrophied, and showed slight leucocytic infiltration. The young cell infiltration was, however, much more marked in the adventitia, and extended into the surrounding peritoneal structure. The endothelial overgrowth penetrated somewhat into the clot, which, however, showed no attempts at organization, and was merely a laminated, compact mould of corpuscles entangled in fibrin. Some necrotic changes were observed in the centre of the clot.

The *clinical indications* of abscess of the pancreas in this case, as frequently occurs, were so meagre that the revelations of the autopsy were surprising; and when one observes the extensive disease and alteration of structure, the wonder is not that the abscess was not recognized, but that it could be present with so little discomfort to the patient. The pain, the gastric disturbance, and the fever frequent in abscess in this situation were absent entirely. Emaciation, constipation, a tumor, and pressure symptoms were present, it is true; symptoms and signs, however, due to so many causes so much more common than pancreatic disease, and which affection quite plausibly, therefore, was excluded.

The latency of the symptoms appears to point to the chronicity of the abscess. The histological appearances of the pancreas, and the sequence of the pus formation, peritoneal adhesions, and thrombosis (from pressure), confirm this view.

Reviewing the symptoms present during life in the light of the post-mortem study, some interesting features may be glanced at. The emaciation was very decided, and although almost always present in disease of the pancreas, was thought to be due to want of food and to gastritis and cirrhosis of the liver. Had the intestinal symptoms of pancreatic disease been present, some other explanation for the emaciation would have been given. But constipation was present, and this is often the case in this disease. Its presence alone, however, was not sufficient to point to a correct diagnosis, while it is true the absence of chronic diarrhœa did not permit us to exclude lesions of the pancreas.

Nor was the doubtful presence of a tumor a sufficient indication of the disease. Its ill-defined character, amounting at times to only a sense of resistance, its nearness to the surface, and its painless nature, left one in doubt as to its nature, and certainly did not warrant the consideration of its being the pancreas. The autopsy showed that it was due to the omentum, which had been involved in and fixed by inflammatory adhesions.

The pressure symptoms sometimes present in disease of the pancreas, caused in this case the venous thrombosis and consequent ascites. The ascites was thought due to hepatic cirrhosis, but it differed from the ordinary serous accumulation of that disease in rapidly returning after tapping. The absence of enlarged spleen, of enlarged veins in the abdominal walls, and of the diarrhœa and gastric symptoms of portal occlusion, would lead us to exclude that affection. The autopsy showed that the one symptom, ascites rapidly recurring, is sufficient for one to infer its presence.

Roberts (Quain's *Dictionary*) tells us that patients suffering from grave pancreatic disease are often low-spirited and despondent, although he doubts the truth of the relationship. Apathy and despondency were quite marked in this case, but might be explained in other ways. In my notes of the autopsy it may be seen that a bronzing of the skin of the face was observed. This has been seen in other cases of pancreatic disease in which the sympathetic system was anatomically involved. Our dissection showed the matting together and involvement of the solar plexus in the diseased process.

It is to be regretted that the urine was not examined for sugar, although it has not usually been present in similar cases. It is worthy

of record that, in spite of the severe gastric catarrh, sialorrhœa was absent.

Pancreatic disease occurs most frequently in men, in the middle or later periods of life, and in those of strumous diathesis. A predisposing tendency may be inherited. Alcoholism and mechanical injury are exciting causes of the inflammatory changes. The habits of our patient would appear to confirm this one point. The sex and the age correspond to the usual statistics.

It may be gathered from the preceding remarks that the diagnosis of the patient's affection was cirrhosis of the liver. Even with the most careful scrutiny, it appears to me there were not sufficient grounds for making any other diagnosis. The habits and age of the patient, the emaciation, the anorexia, the ascites, and the absence of renal and cardiac disease, would direct our attention to this hepatic lesion. From the preceding review of the clinical history of this case, the following train of symptoms would permit us to infer that some form of pancreatic disease was present. They are progressive emaciation, despondency, bronzing of the skin, without the asthenia of Addison's disease, constipation, and thrombosis of the portal vein. In the latter instance other causes of thrombosis must be excluded. If the other symptoms of thrombosis, viz., diarrhœa, enlarged superficial veins, and enlarged spleen, be present, I cannot see how a differential diagnosis from hepatic cirrhosis could be made. A long duration of the disease and the physical signs of cirrhosis of the liver, both uncertain elements, would favor that affection.

The comparatively slight alterations in the hepatic structure lead one to infer that portal obstruction was not of very long duration. Phlebitis of the portal vein and its hepatic branches was certainly comparatively recent. It is of interest to note that, in spite of the cutting off of a considerable amount of blood supply, bile was freely secreted. The enlarged hepatic arteries are evidence that this vessel compensated for the loss of portal radicles. The thrombus, from its laminated appearance, formed slowly, no doubt; on account of pressure on the vessel the blood current was slackened. The dissection distinctly showed that there was no pressure on the splenic or gastric vessels, and hence the absence of the symptoms thereof. It is to be regretted that the course of the collateral circulation was not observed.

The rupture of the pancreatic abscess and its limitation to the duodeno-jejunal fossa are believed to be unique. So far as I have examined the subject, a similar case has never occurred. Treves, in his lectures on the anatomy of the peritoneum, states that this fossa is of no prac-

tical importance and is not concerned in the production of internal hernia. On the other hand, Allen (*System of Anatomy*) quotes Treitz, who believes that many cases of retro-peritoneal hernia have their point of origin in this locality. A number of other authorities quite agree with Allen. None of them refers to abscess in this locality.

Nothing has been said of the peritonitis. It was, no doubt, due to extension from the pancreas. It did not present any clinical phenomena during life, save the previously noted tumor. The excessive gastric catarrh was due more probably to the habits of the patient than to any effects of obstruction of the gastric vein. The intestinal catarrh was, no doubt, due to the venous thrombosis.

Complicated as this case was, I will finally observe, how much more complicated it would have been had the abscess burrowed into the retro-peritoneal space down to the groin or to the buttock. Verily, the problem of the recognition of disease of the pancreas has not been solved.

What means could have been employed to cure our patient? Had the diagnosis been made, unquestionably, laparotomy should have been performed, and one can see that it alone could have been of service. Without a definite diagnosis, in this advanced day of abdominal surgery, an exploratory operation should have been done. Since the admirable paper of Senn, it would be culpable to neglect resorting to operative measures for certain diseases of the pancreas.

In conclusion, it may be stated, from the present study, that abscess of the pancreas may occur in persons of intemperate habits, of the male sex, and after the age of forty. It may be almost entirely latent, or present the only positive symptoms of emaciation, constipation, and pressure phenomena, and, doubtfully, of despondency and skin bronzing.

June 25, 1885.

III. THE VASCULAR SYSTEM.

1. *Absence of parietal pericardium; malposition of liver.*

Exhibited by Dr. W. E. Hughes.

C. L., white, æt. 33 years, was admitted to the University Hospital July 21, 1882. He had been previously in the Philadelphia Hospital, under the care of Dr. E. T. Bruen. By occupation a carpet weaver, of late years he had done general laboring work, often much exposed to the weather. He had been a moderate drinker and user of tobacco. There was a distinct history of asthma in the family, both mother and maternal grandfather having been affected, but no phthisis. When eleven years old he had pneumonia, and since then winter cough. Till three years before being seen he was well and strong, then the cough became continuous, and flesh and strength began to fail. A year afterward dyspnœa developed; at first produced only by exertion, it soon became constant, and the most urgent symptom in the case. In the fifteen months preceding admission to the hospital he had had two or three attacks of excruciating pain about the fifth interspace to the right of the sternum. The attacks would begin suddenly, last a few minutes, and disappear as suddenly as they came, leaving him completely exhausted. On admission to the hospital he was weak, somewhat emaciated, breathless; face sallow, with a circumscribed flush on left cheek. Expression cheerful. Left pupil larger than right, either one responding well to light. Cough constant, rather dry, some muco-purulent expectoration in the morning. Dyspnœa constant, with marked exacerbations on exertion. Appetite and digestion poor, bowels irregular. On the right side of the chest was a distinct prominence, reaching its greatest elevation at the fifth interspace, midway between the sternum and nipple. Over right chest poor movement, with flattening at the apex. At the apex of the lung there were evidences of a cavity, while from the third rib to the base, and from the sternum to the anterior axillary line (over the area of prominence just spoken of), there was flatness, with absence of vocal resonance and fremitus; posteriorly dulness with mucous râles and scattered friction sounds. On the left resonance was impaired at the apex, and respiration blowing, elsewhere normal. The apex beat of the

heart was in the fourth interspace, one-half inch outside of the left nipple. With the systole could be noticed a slight localized retraction of chest wall immediately inside the apex beat. Cardiac dulness extended from the right border of sternum two inches to the left of the sternum in the second interspace, two and a half inches in the third, three and a half inches in the fourth. First sound weak and valvular, second pulmonary sound accentuated and reduplicated. Liver dulness extended to the margin of the ribs anteriorly, continuous above with the flatness in the chest, posteriorly it was normal. A diagnosis of chronic plastic pleurisy, with consequent phthisis, was made, and the needle of an aspirator introduced about the middle of the area of flatness with negative results—the needle, as was shown after death, must have punctured the liver. While in the hospital his condition remained much as it was on admission. His most interesting symptom was one connected with the pupils. They were usually unequal, sometimes the right sometimes the left being largest. Whenever the pupils were unequal there was invariably a flush, limited to the cheek corresponding with the largest pupil. March 15, 1883, after a fall, he had a slight pulmonary hemorrhage and died in five minutes of apnœa, the heart continuing to beat after the respirations had ceased.

Autopsy, twelve hours after death.—The upper lobe of the right lung had been converted into a cavity with contracting walls; the upper part of the middle lobe had undergone marked fibroid change. The rest of the middle lobe and all of the lower were collapsed, congested, and pushed back by the liver, which lay in front of them. The lung was universally adherent to the chest wall and diaphragm. The left lung had small masses of cheesy deposit at its apex, with the remaining substance healthy; it was less adherent than the right. The heart was normal in size and position; the valves and great arteries were normal. What lends the case its chief interest was a complete absence of pericardial sac, the heart lying free in the left pleural cavity, its surface in contact with the left visceral pleura. Toward the apex there were a few fibrous bands connecting the heart with the lung and diaphragm (evidently the results of old pleurisy), while toward the base it was impossible to separate the heart and lung on account of the density of the adhesions. The serous covering of the heart was directly continuous with the visceral pleura. From the diaphragmatic pleura immediately beneath the heart sprang a fold of serous membrane one inch broad and three inches long, apparently an abortive attempt at the formation of a pericardial sac. No such formation could be demonstrated at the base on account of adhesions between the heart and lung. The liver presented a curious departure

from the normal position: the right lobe about its middle turned sharply upon itself and, carrying the diaphragm with it, extended upward to the third rib; this accounted for the prominence and dulness in the chest before noted. The gall-bladder was carried with the liver, its fundus pointing upward; the left lobe was very small and was not carried up with the right. On section the liver showed a nutmeg appearance. The other organs were normal. *September* 27, 1883.

---

2. *Enormous hypertrophy of the heart (weighing forty-eight ounces).*

Exhibited by Dr. C. W. Dulles.

The patient from whom this specimen was obtained, was a man æt. 18 years, who came under my care in February, 1882, in an attack of muscular rheumatism principally affecting the shoulders. I found at that time, great oppression of breathing, a heart dilated and hypertrophied, with harsh, strong, mitral systolic, and presystolic murmurs. His urine contained bile coloring matter, great excess of urates, great lack of chlorides and phosphates, and no albumen or sugar. In the sediments only amorphous urates were found. The treatment employed included the administration of infusion of digitalis, with iron and strychnia. At one time, believing it might benefit the violence I attributed to the real hypertrophy, I gave him veratrum viride. But it did no good. I did, however, get apparently good and prompt relief from some of the symptoms by the use of iodide of potash, in twenty grain doses, thrice daily. After using this for a week, I noted in my case-book: "Sleeps well; eats well; feels well; cough very slight; urine clear; pulse better; *cannot hear the old murmur!* (perhaps barely); both heart sounds audible and pretty clear; action of heart fair." (It had been very tumultuous.) After six weeks of doing well, the patient had a new attack of uneasy stomach, dyspnœa, and more or less cyanosis. On the night of May 10th he had a frightful attack of dyspnœa. I gave him gr. one-fifth of muriate of pilocarpine hypodermically (in the left arm), under the influence of which he sweated, but had no salivation.

The next day he had a large œdematous swelling of the left side of the neck, below the jaw, and reaching to the middle line in front. This increased up to the evening and gradually subsided in three days.

About this time fluid began to accumulate in the abdomen and thorax,

and there was, of course, œdema of the feet and legs. There was also heard now a most beautiful water-hammer pulse over the femoral arteries below Poupart's ligament. The pulse here was intermittent and had a reduplicate sound like this .—, .—, .—, .—, etc.

Three weeks later another severe attack occurred, and again about three weeks after this. There was now in his urine considerable albumen, and hyaline tube casts. When his attack came on, which was at night, I gave him gr. one-third of the muriate of pilocarpine hypodermically, which produced free sweating and brought out about f℥ ij of saliva. His pulse came down from 140 to 100 in half an hour. But the dyspnœa abated only temporarily; the restlessness continued; the cyanosis increased; the respiration varied from 35 to 60 per minute; then his bowels moved involuntarily, his lungs seemed to fill up with œdema, and he died asphyxiated.

The autopsy was made the next day, with the assistance of Dr. Formad and Dr. J. H. Musser. The points of interest were as follows: General œdema of feet and legs; the face, neck, and chest covered with purpura-like spots and patches. The abdomen contained about two quarts of clear serum; each pleural cavity nearly as much. The lungs were normal, but small, and occupied the upper part of the chest. They were quite œdematous. The liver was slightly fatty. The spleen was of normal size but very hard and rough. The kidneys were large, congenitally lobulated, and in a state of cyanotic hypertrophy.

The heart was enormously hypertrophied, weighing, when all the adherent parts were removed, forty-eight ounces. The pericardium was so uniformly attached to it that it could not be removed, and there was absolutely no pericardial cavity. The right ventricle contained about six ounces, and the left ventricle about two ounces, of soft post-mortem clot. After the heart had been opened and well washed it weighed forty ounces. All the valves and bloodvessels were healthy. The tricuspid and aortic valves were quite competent. The mitral orifice was enormous—measuring two and a half inches across. Every part of the heart was hypertrophied and all to about the same degree. The whole organ, which I here show, was about the size of that of a bullock.

The points of interest in this case—aside from the curiousness of the specimen—seem to me to be the comparative immunity of the kidneys; the absence of signs of adherent pericardium; the benefit derived from the use of iodide of potash; the temporary disappearance of the very strong mitral systolic and presystolic murmurs; and the parotid swelling following the hypodermic injection of pilocarpine in the arm of the same side.

Dr. J. H. Musser remembered distinctly the case both before and after death. He had marked out on the chest the dimensions of the heart and made it out as enormous, extending especially to the right. Furthermore, he thought that there was a double mitral murmur. The only apparent cause for hypertrophy was the adherent pericardium. He would like to know what Dr. Henry thought of the correctness of this explanation.

Dr. F. P. Henry said that the heart presented was remarkable, not only for its enormous size, but also for the absence of the usual causes of cardiac hypertrophy, there being neither valvular disease nor obstruction in any part of the circulation. During his student days he had seen some very large hearts in the collection which Prof. Alonzo Clark was accustomed to show to his class, but would not trust his memory so far as to affirm that any one of them was as large as the one just shown.

Dr. MacConnell had seen a case in a member of the Modjeska troupe, where post-mortem examination showed an enormously hypertrophied heart with adherent pericardium, and markedly granular kidneys. In this case the hypertrophy was clearly due to the kidney trouble.

Dr. Formad thought that Dr. Dulles's case was unique as to size. Dr. Robinson, of New York, had recently reported a case of hypertrophied heart weighing fifty-six ounces, but Dr. Dulles's specimen was weighed after removal of clots, etc.

Dr. Musser asked whether other members of his patient's family had not hypertrophied hearts without valvular lesions. If such was the case, taking into consideration the age of the patient, it would be well to consider the probability of the hypertrophy being in part secondary to the pericardial adhesions, in part idiopathic in origin.

Dr. Dulles said that there was a tendency to hypertrophy of the heart in one sister, and that the murmur at times was double.

December 13, 1883.

---

3. *Calcified pericardium; double mitral disease.*

Exhibited by Dr. W. E. Hughes.

Ella S., white, æt. 23 years, was admitted to the University Hospital in September, 1880, complaining of palpitation and dyspnœa, and suffering from an œdematous and eczematous condition of the lower extremities. She was of regular habits, somewhat exposed to changes of weather an to wet, but doing no very hard work. She had had the diseases

peculiar to childhood, but neither rheumatism nor chorea. Her father had had acute articular rheumatism and died suddenly; beyond this there was nothing peculiar in the family history. Three years before admission she first noticed slight palpitation and dyspnœa on exertion. For some time before that she had been subject to frequent attacks of epistaxis. One year afterward dropsy appeared in the ankles and spread upward. The palpitation and dyspnœa became more troublesome, her flesh and strength failed, and she was compelled to quit work and come into the hospital. When first seen she was pale, anæmic, weak, breathless on exertion. The heart's apex beat was in the seventh interspace, one inch outside of the nipple line; action strong and heaving. Best heard over the apex beat, but transmitted freely up toward the base of the heart and well out into the axilla, was a loud, blowing, systolic murmur. There was no pain in the heart or tenderness on pressure over it, nor had there ever been. Over the lungs were scattered moist râles; the respiratory murmur was harsher on the left than on the right; cough was slight with some mucous expectoration. The lower extremities were œdematous, and the abdominal cavity about half filled with fluid. The liver was slightly enlarged. The urine was normal in quantity and contained neither albumen nor casts. Under treatment the urine became copious, the œdema gradually disappeared, and the heart action became stronger and more regular. In a few days friction sounds appeared at the base of the right lung. Any slight exposure would bring on an attack of intense congestion of the lungs, with dyspnœa that often threatened life; and with these attacks there was often congestion of the kidneys with suppression of urine. Between the attacks the heart retained its power well, though it slowly dilated; at intervals she complained of dull pain in the hepatic region. The rough respiration noted at first over the left lung became more and more marked, till finally over a small area just below the spine of the scapula it had developed into bronchial breathing. Friction sounds came and went. There were always moist râles scattered through the lungs. The expectoration was mucous or rarely muco-purulent. Three months after she came under observation there was developed at the second right intercostal space and carried out into the arteries of the neck, a systolic murmur differing in pitch and tone from the mitral systolic. About this time, too, she complained of pain in the heart whenever its action was excited. Soon afterward albumen was found in the urine, but no casts; this was the only time it was ever detected. Fourteen months after she was first seen there was noticed, just inside the apex beat and carried indistinctly toward the base, a harsh, short murmur, immedi-

ately preceding the systolic murmur and separated from it by an exceedingly short but appreciable interval. This murmur was noted on several occasions afterward, but was much more frequently absent than present. Its appearance and disappearance seemed to be attendant on no definite conditions. Soon after it was first noticed she had several attacks of epistaxis, and afterward occasional slight hemorrhages from the lungs. She was discharged in March, 1882, and was readmitted last September. She had been gradually losing ground; seven months before she took cold, the dropsy returned and persisted. When seen the whole body was œdematous and the abdomen enormously distended. The apex beat was in the fifth interspace in the mid-axillary line. The systolic murmurs were, perhaps, louder, but beyond this had not changed. Over an area between the left nipple and the sternum was heard a harsh, low-pitched presystolic murmur. It was much more apparent than the former presystolic murmur, but had the same characters. Its point of maximum intensity was just to the left of the sternum. It was constant. The respiratory murmur over the left lung was very much harsher than over the right. Below the spine of the scapula the breathing was sometimes blowing with mucous râles, sometimes cavernous with gurgling râles. The expectoration was mainly frothy mucus. She died three weeks after admission in a fit of dyspnœa.

Autopsy, seven hours after death.—General dropsy, most marked in the lower extremities and genitals. On the lower part of the abdomen there was a marked varicose condition of the cutaneous lymphatics. The cavity of the pericardium was completely obliterated by adhesions. The two pericardial surfaces and the fibrous tissue connecting them had been changed into a calcareous plate three inches broad, completely encircling, about its middle, the heart, with the exception of a space one inch wide on the posterior surface of the left ventricle. This calcified condition extended for one inch on the anterior surface of the pulmonary artery. The heart, with the calcified pericardium, weighed twenty-eight ounces. The auricles were dilated, their walls thinned. The ventricles were dilated, their walls thickened and undergoing fatty degeneration. The leaflets of the mitral valve were thickened and rigid; the mitral orifice very decidedly narrowed. In the inner surface of the left auricle were several calcareous patches. The aorta was very small, scarcely admitting the index finger, and showed patches of atheroma. The lungs were chronically congested and œdematous, the condition being most marked on the left; there was no breaking down of their substance. The abdomen contained five gallons of straw-colored serum. The peritoneum was thickened and roughened. The liver weighed three and one-half pounds

and was cirrhotic. Its capsule was much thickened and adherent to surrounding structures. The mucous membrane of the stomach was mamillated and thickened. The kidneys showed cyanotic induration.

December 13, 1883.

---

4. *Atheroma, dilatation, and aneurism of the aorta; atheroma of some of its branches; death from rupture of the aneurism into the left pleural cavity; congenital deformity of the stomach; malposition of the transverse colon and right kidney; irregular shape of the kidney; anomalous origin of the renal arteries and of the ureters.*

Exhibited by Dr. J. H. Musser.

This series of remarkable specimens illustrates how serious a disease can be in progress within the body without any manifestations. The patient had been under the care of Dr. Ludlow in the Presbyterian Hospital, complaining of and being treated for nasal catarrh. He complained, also, of a slight bronchitis, but not being very decided, the nasal trouble alone was treated. A white man, æt. 63 years, well nourished, of temperate habits, and by occupation a wheelwright; he was under observation ten weeks. No previous illness. He slept well the night before his death, until 5 A.M. He then told the night nurse he was very cold; being covered, he went to sleep, apparently; an hour afterward he was found dead. The writer made the autopsy about twelve hours after death.

Inspection.—Rigor mortis well marked; body well nourished; no scars or bruises; no ecchymoses; abdomen moderately distended; in the right lower quarter a decided swelling was noticed, almost filling that area and resonant on percussion.

Section.—Abdominal cavity first examined. The above described swelling was due to the cæcum and transverse colon. The ascending colon extended about half way the usual distance, and this turned at a sharp acute angle into the transverse colon. The latter descended parallel to the former into the right iliac fossa, and thence diagonally upward across the abdomen to the usual place of junction with the descending colon. The omentum contained a considerable amount of fat. The right lobe of the liver could not be seen until removal of the ribs, when it was found two inches above their margin, and to be only two and one-half inches in length in the nipple line. In the

median line this same perpendicular length was three and one-half inches. More of the left lobe was visible than the right. Along the edge of the left lobe, from the median line, four and one-half inches in length, extended the *stomach*. It appeared to be small in size. When removed it was found to be divided by a constriction five inches from the fundus; from this constriction to the pylorus the length was four and one-half inches. The first or cardiac end was much smaller than normal, the walls and mucous membrane healthy. The second portion was a mere tube with thick walls. The thickening was due to the hypertrophy of the longitudinal muscular layers, and to the folds into which the mucous membrane was thrown. These folds were very marked, longitudinal, and in thin curls, congested. The peritoneum was opaque and thickened. The *liver* was smaller than usual. The capsule was thickened and opaque along the edges of the right lobe; on the convex surface there were cicatrices and a firm adhesion at one point to the diaphragm. On section the tissues were firm. The gall-bladder projected one inch below the liver margin in the nipple line. The left *kidney* was found in its normal position. It was much enlarged, five inches long, two inches thick. The pelvis was filled with fat; the substance pale, hard on pressure, with a contracted cortical portion. The capsule tore off easily. The right *kidney* was found in the pelvis at the right sacro-iliac articulation; it was small in size, irregular in shape. Parallel to the sacrum the portion dipping downward tapered to a point, being one-half inch in width; the upper portion was two inches wide. The pelvis of the kidney was filled with fat. Toward the small end of the kidney the pelvis divided, one part extending upward one inch along one side of the organ, the other the same length on the other side; or it might be said a portion of the kidney dipped into the pelvis, separating it for an inch. The renal artery arose from the normal position of the middle sacral. One inch from the point of origin it divided, one branch, two and a half inches long, entered one lateral hilus, if it may be so termed, the other divided two and a half inches from the main trunk, one subdivision entering the remaining lateral hilus, the other running across the floor of the pelvis to the normal end of the kidney. The ureter arose by three branches—two from the upper end and one from one of the smaller pelves.

Thoracic cavity.—Left pleural cavity almost filled with blood, the lung floating on the fluid. The lateral surface was adherent to the aneurism. On its removal the collapsed sac was seen on the left side of the vertebral column. The heart and aorta were removed entire. Heart enlarged, left side especially; weight eleven and a half ounces;

measurements of left ventricle, near base one and an eighth inch thick, in the middle seven-eighths of an inch thick, at the apex one-half inch thick; mitral valves a little thickened, aortic healthy. Atheromatous processes were present in the aorta from its beginning to the cœliac axis, and extended into the latter vessel and also the innominate and carotid arteries. These processes included the sclerotic changes shown by innumerable small, smooth, firm elevations of this surface, the degeneration changes, fatty and calcareous, and also the atheromatous. One calcareous plate was found in the cœliac axis. From its origin to the middle of the transverse aorta, the vessel was dilated and the characteristic fatty changes of the proliferated cells of the intima lemon-yellow colored, smooth, soft elevations were marked. Opposite the trachea the calibre of the aorta diminished to almost normal size, and here the sclerotic changes were most marked, as well as around the mouths of the vessels. At the junction of the transverse and descending aorta, the lumen was again closed; here the aneurism originated. It was five and a half inches long, and when distended twelve inches in circumference. It was of the true variety, but from it sprang four false aneurisms, varying in size from a filbert to a small egg. Organized clots covered the surface of portions of the wall, and on dissection it was found that these clots were either in the false aneurisms or clinging to atheromatous ulcers. Rupture of the sac took place behind the pleural adhesions, and the blood leaked into the cavity, finding its way through the adhesions. The vertebræ were not eroded, and although the sac was in contact with the left bronchus, there were no evidences of decided pressure upon it, while the relations to nerves, other vessels, and the œsophagus were such that the usual pressure symptoms could not arise. It is thus seen that by physical examination alone could this aneurism have been detected. There were absolutely no subjective symptoms and the autopsy reveals the reasons of this. *December* 27, 1883.

---

5. *Aneurism of the left ventricle.*

Exhibited by Dr. W. E. Hughes.

To the kindness of Dr. M. B. Musser I owe the clinical history of this case and the privilege of presenting the specimen to the Society. Mr. P., æt. 58 years, healthy with the exception of slight pain in the region of the heart on vigorous exercise, was attacked September 20th with left hemiplegia. Motion was completely lost, sensation somewhat impaired

but by no means lost. The attack was rather sudden and was preceded for some days by slight dizziness. There was no loss of consciousness. After treatment, lasting over more than a month, he so far recovered as to be able to walk with the assistance of a cane, when he was seized, one night while in bed, with a frightful attack of angina pectoris. During the next two or three days the attack was repeated several times, and at the end of that time there was a very plain double pericardial friction sound heard over the whole cardiac area. From this time on, the anginal attacks were neither so frequent nor so violent as before. He fell back dead November 15th while sitting up in bed to take a glass of water. Before the pericarditis developed the heart had been carefully examined with the result of finding no murmur. The area of cardiac dulness was enlarged and the heart's impulse weak and diffuse. The pulse was weak, ranging from 75 to 80 in the minute, and very little accelerated during even the severest angina. The urine contained a small amount of albumen; no microscopic examination was made. There was at no time any œdema.

Autopsy, thirty-six hours after death.—Body very fat. Rigor mortis moderately well developed. Abdominal and thoracic organs decomposing rapidly. Brain is larger than the average, very heavy and much convoluted. All its larger arteries are atheromatous, in places converted into rigid tubes, but nowhere is there any interruption of their lumen. No lesion of the brain substance. Some opacity of the pia mater, more marked over the right hemisphere anteriorly. In the meshes of the pia mater a large amount of straw-colored serum, most abundant about the motor areas on the right, and here the serum is tinged with blood though there is no true clot. Very little serum in the ventricles. Lungs are congested; no lesion of their substance. About a quart of serum in the left pleural cavity; less fluid in the right and firm adhesions over its upper half. Universal pericarditis; cavity of the pericardium is almost obliterated by easily torn adhesions, where it is not obliterated there is a small effusion of flaky sanguinolent serum and the pericardium is ribbed by a deposit of lymph. Heart is large, left auricle dilated, ventricle enormously dilated and hypertrophied, its wall one and a half inches thick; right side very little changed. In the left ventricle, involving the interventricular septum and the wall about the apex, is a saccular dilatation capable of holding at least two fluidounces developed by a giving way of the heart wall. This cavity was filled by a firm old clot containing a cavity as large as a filbert, filled with grumous pus. The endocardium in the aneurism had been totally destroyed and the clot was in places firmly adherent to the exposed and

thinned muscular tissue. In the anterior wall the tissues had completely given way over a very small area, but the rupture was filled by the clot, which projected slightly into the pericardial sac. A similar condition existed in the septum, the clot here projecting one-half inch into the right ventricle. Owing to the clot filling these ruptures there was no communication between the cavity of the left ventricle and that of the right ventricle or of the pericardium. Heart muscle was fatty. Aorta was slightly atheromatous and its valves rather rigid, though competent. Other valves healthy. Coronary arteries not atheromatous. Liver enlarged, congested, slightly cirrhotic. Kidneys enlarged, congested, cortical substance increased in volume, small spots of fatty degeneration, capsule stripped off easily.

Dr. Bruen thought it was of great interest to note that the location of the aneurism was in the septum toward the apex. This is an unusual site because when due to ulcerative endocarditis, as was probably the case here, the aneurism is usually situated at the base of the heart abou, the attachment of the aortic valves. He had seen a case three or four years ago of aneurism of the heart, the result of ulcerative endocarditis which was situated at the apex, but it extended toward the left and did not affect the septum. In this case the pericardial cavity was completely obliterated at the site of the aneurism when the pericardium formed the aneurismal wall. I tapped at this joint for a pleural collection, but only withdrew an ounce of blood, when I desisted. Instead of doing harm the tapping afforded relief, and the pleural and other dropsical effusions were absorbed. The patient died fully two years after the operation.

Dr. Tyson thought that the disease being situated at this point, it pointed rather to endocarditis of the cavity than to the ulcerative form. This had resulted in the formation of one of the so-called tendinous spots, which gradually yielding, the aneurism had formed. The rupture might have been of some standing, as these interventricular ruptures are stated to be not very dangerous and compatible with considerable prolongation of life.

Dr. Hughes said that there really had been no communication between the heart cavities, as the opening was blocked by a clot which was evidently old. *February* 14, 1884.

6. *Rupture of one of the aortic leaflets during severe muscular strain.*

Exhibited by Dr. M. J. Lewis.

F. L., æt. 40 years, married, laborer, was admitted into the Episcopal Hospital under my care February 21, 1884. His family history was good, and his own health, previous to his present indisposition, excellent. He denied ever having had syphilis or rheumatism.

His work compelled him to handle very heavy casks, and he had the reputation among his fellow-workmen of being a particularly strong man, he being able to lift unaided 500 pounds. Three weeks before admission he was subjected to heavy strains in lifting and, although no history of sudden cardiac pain or palpitation could be elicited, he did admit feeling a sense of tightness across his chest and some dyspnœa after his day's work. These symptoms gradually increased, and cough accompanied by bronchitic expectoration soon made its appearance. On admission the patient presented all the appearances of a remarkably well developed and powerful man; he was suffering from great dyspnœa which was much increased upon exertion. Percussion showed impaired resonance over both lungs posteriorly, which was not altered by change of position, and auscultation revealed numerous moist râles. The apex beat of his heart, although perfectly regular in its rhythm, was extended in its area and in the nipple line in the fourth left interspace. Auscultation revealed a loud, high-pitched musical murmur, systolic in time, with its point of greatest intensity over the upper part of the sternum, this was also audible over the whole chest. The peculiarity of the murmur was its decidedly vibratory character, like a torn sail flapping in the wind; even the patient himself noticed this. With the diastole there was a second murmur of much lower pitch and not musical or vibratory in its nature—this had its point of greatest intensity over the aortic cartilage. There was no apex murmur. Slight œdema of the legs and feet was present. The urine contained no albumen.

The patient was placed in bed and given digitalis, while counter-irritation and dry cups were applied to his chest posteriorly. Under this treatment he rapidly improved and was soon considered well enough to be about the ward, the dyspnœa only showing itself after any unusual motion or excitement. The murmurs remained in much the same condition as on admission, although the intensity of the musical murmur had lessened.

On March 20th, in the evening, after a day as well as usual, he was seized with a severe attack of dyspnœa with congestion of the lungs; he was considerably relieved by the application of dry cups; the next morning it was noticed that the œdema of the legs had increased, the dyspnœa was still present to a slight degree, and the only change perceived in the cardiac signs was a lowering of the pitch of the musical murmur.

On the 22d the dyspnœa had increased again, and for the first time a low, long apex systolic murmur was detected; this was conveyed plainly into the axillary line. The musical murmur was of still lower pitch than before, and at the aortic cartilage the murmurs were much more plainly of a see-saw character.

Irregularity of the heart's action occurred now for the first time.

On the 23d the area of cardiac dulness was as follows: In the horizontal line, at height of nipple, the dulness began in the middle of the sternum and extended to the left to a point half an inch beyond nipple. In the perpendicular line, drawn midway between the sternum and left nipple, the cardiac dulness began in the third interspace and extended downward till lost in dulness of left lobe of liver.

The area of dulness was not triangular with the base downward. Impaired resonance was now present over the whole chest both anteriorly and posteriorly, and no cardiac sounds could be heard on account of the great stridor and the violent movements of the chest. The apex beat could not be detected for the same reason. After this the patient became more and more cyanotic and short of breath, and died on the same day, viz., March 23, 1884.

Autopsy.—Each pleural cavity contained several ounces of serum. The pericardium contained about one and a half ounces of serum in which several shreds of lymph were discovered. In both ventricles were large clots, partly chicken-fat; extending through the semilunar valves. Weight of heart after being emptied of clots and blood one pound ten ounces. The walls of the left ventricle were enormously hypertrophied, measuring seven-eighths of an inch at thickest part; the cavity appeared slightly distended as did also the mitral orifice, which would allow the tips of three fingers to pass. The right anterior leaflet of the aortic valves was torn at its posterior insertion into the aorta, thus leaving a free pointed end about three-eighths of an inch long to float in the blood current. The left anterior leaflet presented two fenestrations, the posterior one the smaller and near the insertion of valve in aorta at its upper margin, the anterior one, the larger, and situated some distance down from the free border of valve.

The aorta at its origin was atheromatous in places and slightly dilated, a patch existing at the point corresponding to the former insertion of the torn valve. The valves were normal except for slight thickening. The coronary arteries were not atheromatous.

Remarks.—In this case the atheroma at the point of insertion of the torn valve must have been the cause of the rupture during a heavy strain; should a fenestration have existed near the point of insertion, as exists in the left anterior leaflet, this would be a further reason for the rupture occurring at this point.

Frequently repeated great bodily exertion was the probable cause of the atheroma, as the man was a moderate drinker and denied rheumatism and syphilis. A point of interest in the case was the peculiar character of the *systolic* aortic murmur which was, as before mentioned, decidedly musical and vibratory.

As the patient did not suffer from sudden palpitation and dyspnœa at the probable time of the rupture, and as this murmur gradually diminished in pitch while the regurgitant murmur became slightly more pronounced, it is probable that the tear at first was slight and gradually increased under the great strain thrown upon it. *March* 27, 1884.

---

7. *Rupture of the heart.*

Exhibited by Dr. T. D. Dunn.

Clinical history.—William H., æt. 58 years, on the evening of November 3, 1883, invited his daughter to take a walk. While she put on her wraps he reclined on a sofa. A few minutes afterward his wife heard a faint groan; she immediately went to his side, only in time to witness his last gasp. With the exception of occasional dyspepsia, he had enjoyed good health. He was a man of leisure, full habit, and apparently robust and strong. He had been a constant though moderate drinker for some time, but seldom carried it to complete intoxication. He had never complained of any heart-trouble.

Autopsy, seventy hours after death.—Owing to objections of friends the brain was not examined. The muscular system was well developed, and there was a large quantity of subcutaneous fat. The lungs and pleura were healthy with the exception of a few old pleuritic adhesions poste-

riorly. There was a large deposit of fat in the mediastinum, and over the entire surface of the heart. The pericardium contained about one ounce of recently clotted blood. The heart was adherent to the pericardium by two small bands—one near the apex of the left ventricle, the other midway between the apex and auriculo-ventricular groove. Externally on the left side of the left ventricle below the auriculo-ventricular groove there was a linear rupture about one inch in length. On opening the heart no valvular disease could be detected, and there was no evidence of atheromatous disease of the large vessels. There was an ulcerated surface about the size of a silver dollar, irregular in outline, and communicating with the external linear opening. This ulceration extended through fully two-thirds of the heart muscles, the muscular tissue of the outer third seemed recently lacerated or separated. The stomach and liver were normal. The left kidney was somewhat enlarged, the capsule slightly adherent, and cortical substance relatively increased; the right appeared healthy.

Microscopical examination revealed fatty infiltration of the fasciculi, but no degenerative changes of the muscular cells could be detected, nor was there any atheromatous change of the vessels of the heart. The interesting feature of this case, in connection with those presented to this Society during the past year, is the suddenness of the attack, without any premonitory symptoms, resulting almost instantaneously in fatal syncope. *April* 10, 1884.

---

8. *Aneurisms of the aorta; empyema.*

Exhibited by Dr. W. E. Hughes.

J. H., white, æt. 35 years, a shoemaker, was admitted to the University Hospital under the care of Dr. E. T. Bruen, December 26, 1883. He had used alcohol decidedly to excess, but had never been much exposed to weather, and had never done any hard work. There was no history of venereal disease. There was a distinct family history of rheumatism, and he himself had, twelve years ago, acute articular rheumatism; since then he has had several occasional fugitive pains, principally in bad weather. Fifteen months ago he caught cold, and soon after began to feel slight pains along the crest of the left ileum. The pain increased for four days, when it became almost unendurable, and extended from the left loin along the crest of the ilium into the groin, his urine was passed frequently and painlessly in small quanti-

ties, and contained no blood. The pain was ameliorated by treatment, but not wholly removed, though there was not enough to keep him from following his usual occupation; it was almost invariably aggravated by damp weather, and was not decidedly influenced by motion. Twice, since then, he had had paroxysms of severe pain, and each time, after taking a mixture containing oil of turpentine, urination had been frequent and painful, and the urine had contained blood. For the last two months he had had more or less stitch-like pain at the base of the left chest and a hacking cough. His general health had been failing only slightly; he thought he had lost about ten pounds of flesh. On admission his face was pinched and anxious, his breathing rapid and shallow, with intense pain at the base of the left lung. Physical examination showed friction sounds at the base of the left lung, with evidences of a small amount of fluid in the left pleural cavity, collected posteriorly; the respiratory murmur over the upper part of the left lung was not quite so distinct as that over the right. The apex beat of the heart was not ascertainable with certainty, but seemed to be a little outside the normal point, the sounds at the apex were indistinct, and synchronously with the systole was a rubbing sound, heard only during inspiration. Toward the base of the heart was developed a harsh systolic murmur, best heard over the upper bone of the sternum, conducted feebly into the carotids, and not heard posteriorly. The heart action was too strong, the whole præcordium heaving. The normal area of aortic dulness over the upper bone of the sternum was somewhat widened. He complained of a constant dull pain running from the left loin along the crest of the ilium. Urination was normal, and the urine contained no abnormal constituents. Under the use of salicylate of sodium the pleuritic pain was quickly relieved—the lumbar pain completely disappeared after a course of alkaline diuretics. The fluid in the left pleural cavity slowly increased for a while, then remained stationary till one week before his death, when there was a rapid increase. The pleural friction sounds came and went. The friction sounds heard over the heart were even more variable, sometimes systolic, sometimes double, occasionally dependent on the respiration, and again occurring regularly with every beat of the heart. Gradually to the left of the sternum, in the second and third interspaces, a new centre of pulsation developed, apparently distinct from the cardiac impulse, and over this area resonance was impaired. Two months after he was first seen a systolic murmur was detected about the middle of the posterior border of the left scapula, distinct from the murmur heard anteriorly. Coincidently with the development of these conditions there was a steady decrease in

the amount of air passing into and out of the left lung; there was no other pressure symptom. For a month before he died he had irregular rises of temperature, with profuse perspiration, and lost flesh rapidly. April 22d, Dr. Wharton introduced a tube into the left pleural cavity, through which a large amount of sero-pus drained off. He died April 27th.

Autopsy, twenty-four hours after death.—Body much emaciated. In the sixth interspace, one inch to the left of the mid-axillary line, is an opening leading directly into the left pleural cavity, which is filled forward to the anterior axillary line, and upward to the spine of the scapula, with a sero-purulent liquid surrounded by walls covered with a pyogenic membrane. The lung occupies the remainder of the pleural cavity, and is everywhere closely adherent, it is compressed, the fibrous tissue is increased, and there is slight catarrh of the bronchial mucous membrane. The pericardium is dotted with scattered patches of recent lymph, and its cavity contains three ounces of flaky serum. The heart is somewhat enlarged, the valves perfectly normal. The aorta is dilated, its endothelium proliferated, roughened, and in places calcareous. Springing from the arch, posteriorly to the origins of the left carotid and subclavian arteries, is an aneurism the size of a filbert, extending back into the connective tissue to the left of the trachea. At the end of the descending part of the arch is another aneurism as large as a peach, springing from the right posterior surface of the aorta, eroding the anterior faces of the fifth, sixth, and seventh dorsal vertebræ, pressing forward and almost occluding the left bronchus. It has ulcerated through the wall of the bronchus, but exudation of blood has been prevented by a firm, laminated clot, which fills this opening. There is no pressure on the œsophagus or on nerves. At the origin of the cœliac axis is another aneurism, half as large, pretty well filled with laminated clots. Kidneys and other organs healthy. *June* 12, 1884.

---

9. *Aneurism of the left ventricle communicating with the aorta.*

Exhibited by Dr. W. E. Hughes.

T. C., white, æt. 39 years, a ship carpenter, was admitted to the University Hospital, under the care of Dr. E. T. Bruen, March 6th. He had always worked hard, and been much exposed to weather. He was a fairly temperate man, and had never had syphilis. He had had several slight

attacks of articular rheumatism, but during none of these attacks had there been any symptoms referable to the heart. There was nothing of moment in the family history. Three years ago his strength, which had never been excessive, failed somewhat, and it became impossible for him to work constantly. Previous to this, while he had never been very robust, he had yet been able to work regularly. There was with the failure of strength more or less dyspnœa on exertion, with a tendency to take cold on slight exposure, but no pain over the heart, and very little palpitation. Six months ago he was very much exposed, and since then has been much worse, palpitation now, for the first time, becoming troublesome. When first seen, the slightest exertion caused the most intense dyspnœa and very annoying palpitation, his hands and face were congested, and his lungs filled with moist râles. The apex beat of the heart was in the fifth interspace in the nipple line, its action strong and heaving. Over the aortic cartilage could be heard a strong, blowing double murmur. He died April 15th, of gradually increasing dyspnœa, due apparently to congestion of the lungs. He had never complained of pain in the heart. There had been no œdema.

Autopsy (*by Dr. Barber*), *six hours after death.*—Pericardium normal; heart large, its left ventricle moderately hypertrophied and dilated, right normal; muscular tissue apparently normal. Between the posterior leaflets of the aortic valve was an oblong opening with smooth, rounded edges extending one-quarter of an inch above the point of juncture of the leaflets into the aorta, and one-half of an inch below into the walls of the left ventricle, much wider in the ventricular than in the aortic wall. This opening prevented the approximation of the leaflets, holding them at least one-quarter of an inch apart, and permitting free regurgitation of blood into the ventricle. The leaflets were attached along the opening—in fact, above, they formed its edges. This opening led back into a cavity about as large as a walnut, lying between the base of the aorta and the upper part of the left ventricle, on the one hand, and the right auricle on the other, bulging decidedly into both auricle and aorta. Its lining membrane was continuous with the endocardium, and was thickened and roughened, but not calcareous. The endothelium of the posterior wall of the aorta covering the projection was also somewhat thickened and roughened. Between the upper part of the sac and the aorta, where the separating tissue was very thin, composed apparently of only two layers of endothelium, there was an irregular tear permitting free intercommunication between the sac and the aorta, between this tear and the upper margin of the opening described above, was a bridge of firm aortic tissue. The endothelium of the right auricle over the sac

was rough and thickened. The wall of the sac was formed of connective tissue and endothelium; it contained only some recent coagula—none that were laminated. The coronary artery arose immediately above the sac, and was not involved in it. The leaflets of the aortic valve were perfectly healthy. Other valves normal. The endothelium of the heart showed no spots of degeneration except that mentioned in the right auricle. The aorta, above the sac, as well as the coronary arteries, was not in the slightest degree atheromatous. Both sides of the heart contained some chicken-fat clots. Lungs deeply congested. Other organs normal. *June* 12, 1884.

---

10. *Notes of a case of infectious, so-called ulcerative endocarditis.*

Exhibited by Dr. John H. Musser and Dr. George A. Piersol.

The following case of endocarditis of the infectious or ulcerative variety is presented for your consideration, to-night, on account of its comparative rarity, and the extreme interest that is aroused by some striking features in its cause, its course, and its anatomical characters. The patient was under the care of Dr. Ludlow in the Presbyterian Hospital, and our obligations are due him for the privilege of this presentation. The following is an abstract of the ward notes of Dr. Hamaker:

Case.—Infectious endocarditis secondary to acute rheumatism; intermitting fever; sweats; diarrhœa; pneumonia. Death. Proliferative endocarditis; micrococci; renal emboli.

W. J., white, æt. 30 years, baker, was admitted to the medical wards of the Presbyterian Hospital, October 3, 1884, suffering from rheumatism, localized in the left knee and the right shoulder and elbow. He stated that he had been feeling badly for some time, losing flesh and strength. Previous to the present illness, he had had smallpox, syphilis, and gonorrhœa.

In addition to the joint pain, it was found he had a temperature of 104°, oppression behind the sternum, with pain aggravated by a slight cough. His face was pock-marked; he had the appearance of a drinking man, and was extremely anæmic. No cardiac murmur detected.

On October 10th, one week after admission, it was noted that the cough and substernal distress had disappeared, the temperature had

fallen to normal, the joint pains were much relieved. The joints had not been swollen or red, but were painful. It was, at this time, thought worthy to note the occurrence of profuse sweats, both day and night.

Oct. 21. Fever and joint trouble recurred; sweating continues; occasional diarrhœa; soft systolic murmur noted at the apex.

25*th.* Nose bled profusely, requiring plugging of the right nostril.

Nov. 1. Pneumonia of lower lobe of right lung. Mitral and aortic murmur heard. No joint pains.

19*th.* Resolution of the pneumonic consolidation; return of joint symptoms.

Dec. 9. Joint symptoms increased in severity and became general. The fever has continued intermitting in type (*see* Chart), the sweating more marked, the pulse and respirations extremely rapid. Past two days, congestion of both lungs. Death at 6 P.M., to-day (9th), or about ten weeks after admission.

Autopsy, twenty-two hours after death.—Head and joints not examined. Bloodless appearance of face and extremities; emaciation of slight degree; marked rigor mortis; large ecchymoses on back of trunk and legs; pin-head size purpuric spots over trunk and extremities, anterior.

Thorax.—Lungs œdematous, and at bases, posterior, the seat of hypostatic congestion; pieces float on water; a few hemorrhagic infarcts are seen in the middle lobes.

Microscopical examination.—The results of an inflammatory action are everywhere present. The interalveolar connective tissue, especially in the immediate vicinity of the bloodvessels, is greatly increased, and contains a notable number of new cells, as well as quantities of dark pigment. The alveoli are generally distended, being partially filled with shed proliferated lining epithelium, while their walls are thickened.

The pleuræ were healthy in appearance. The pericardium was normal; its sac contained a small amount of serum.

Heart.—Slightly hypertrophied. Its exterior appeared normal; on section the walls were normal, and but slightly increased in thickness. In both ventricles, ante-mortem clots were seen extending far into their respective vessels. On removal of the clot from the left ventricle, a portion of the inflammatory exudate was torn off, the fibrin having been intermingled with it. After this removal the auricular surface of each segment of the mitral valve was seen to be fringed with grayish-white outgrowths. They were quite soft and varied in size from a bead to a cherry, and were irregular, warty, or roughened in appearance. A few outgrowths were also seen on the ventricular surface of the valve

segments, and some were attached to the chorda tendineæ. (Fig. 1.[1]) No extension of the inflammatory process was seen on the endocardium of the auricular or ventricular walls. On removal of the vegetations, a roughened appearance of the valve was observed, but no ulceration. The aortic valves were similarly encrusted with these vegetations, apparently springing from the corpora arantii. The pulmonary valves

Fig. 1.

Mitral valves, showing inflammatory outgrowths.

were normal. The aorta was healthy, save near its origin, where a few small spots of atheroma were detected; small aneurisms observed by others were absent.

Microscopical examination.—The outgrowth examined was taken from the posterior curtain of the tricuspid valve. Its general appearances and arrangement, as seen in longitudinal section under low amplification, are accurately shown in the accompanying photo-micograph. (Fig. 2.)

[1] Three photographs and four micro-photographs, taken by Dr. Piersol, were exhibited. The photographs showed the outgrowths on the mitral, tricuspid, and aortic valves respectively. The micro-photographs showed sections of the valves and masses of micrococci, × 200 and × 700 respectively. The woodcuts were cut from the photographs.

The upper surface of the valve is covered with irregular, dense masses, forming a broken, but complete investment. The under surface is generally free, some sections showing a few small areas of the same nature. By their intense and tenacious staining with methyl-blue, as well as by other characteristics, these masses appear composed of large zoöglœa tracts of micrococci. Examination under a power of 1000 diameters (Zeiss $\frac{1}{20}$) confirms this supposition, suitable parts of the

Fig. 2.

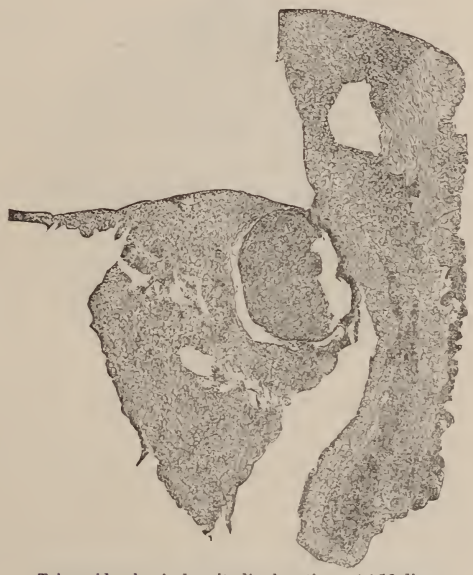

Tricuspid valve in longitudinal section. × 18 diam.

masses being readily resolved into the individual cocci. These masses of micrococci apparently rest *upon* the endothelium; in places, however, they penetrate to the subjacent tissue by processes, which recall strongly the penetrating pegs of epithelioma. The micrococci are arranged in groups, varying greatly in size, and generally distinctly limited. In several places, the micrococci occur in the connective tissue layer of the valve, as circumscribed, well-defined, oval masses, as seen in the photograph. (Fig. 3.) The subendothelial tissue in many fields is filled with diffused micrococci; the cell proliferation in this layer, however, being pronounced in but few places. The bulk of the growth is due to a very marked proliferation of the elements of the central, connective tissue layer of the valve. The fibres are separated and crowded apart by numerous small round and oval cells. On the under surface of the

valve, about one and a half millimetres from the edge, exists a large oval mass—slightly less than one millimetre in diameter—composed principally of micrococci, among and dividing which are delicate septa, in connection with the delicate capsule surrounding the entire mass. Embracing this mass, and extending along the valve to and beyond its edge, is a thrombus. The surfaces of this are invested by a distinct membrane. Throughout

Fig. 3.

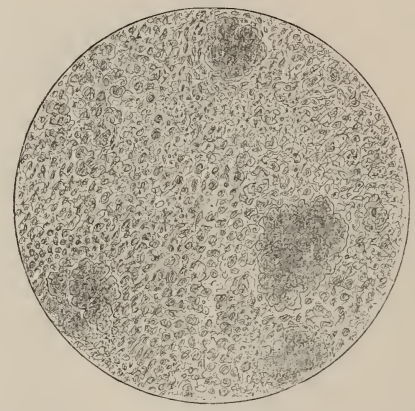

Masses of micrococci in the substance of the valve. × 200 diam.

the thrombus, among the well-preserved blood-cells, minute masses of micrococci are to be seen.

Examination of the wall of the left ventricle shows the muscular tissue itself to be unchanged; in the intermuscular connective tissue, especially near the endocardium, however, there is an increase in cellular elements.

Abdominal cavity.—*Liver* weighs four pounds ten ounces. Fatty and slightly cirrhotic. Gall-bladder and ducts normal. *Spleen* weighs one pound five ounces, soft and pulpy. Malpighian bodies very marked, capsule thick and opaque. Neither organ contained hemorrhagic infarcts. *Kidneys,* each weigh ten ounces. Both have the appearance of the large white kidney. In the left a small cyst is seen, and in the right a very large hemorrhagic infarct.

Microscopical examination of the kidney.—The intertubular connective tissue is everywhere increased, and contains great numbers of small cells, this being especially marked around the larger bloodvessels and Malpighian bodies. These latter present conspicuous changes. From a condition where the glomeruli are simply swollen, distending the

capsule, with, perhaps, an increase of nuclei, all stages of glomerulitis may be found—the capsule disappearing in the surrounding mass of inflammatory cells; finally, the complete atrophy of the Malpighian body. The uriniferous tubules of the labyrinth are distended with swollen granular cells; frequently they are occupied with plugs of degenerated epithelium, blood-cells, and granular débris. The blood-vessels are engorged; in places near the Malpighian bodies partially absorbed extravasations are to be noticed. The larger vessels show some thickening of their walls. In a few vessels, in transverse section, micrococci were distinctly seen entangled among the blood-cells and proliferated endothelium.

Remarks.—During the period of observation—viz., ten weeks—the sequence of events was, acute articular rheumatism, the symptoms of which ameliorated in one week; a period of uncertain convalescence characterized by profuse night sweats; a recurrence of the rheumatism after ten days, with coincident endocarditis; a second remission of the joint symptoms, of twenty days duration, during which a pneumonia ran its course to almost complete resolution; a third relapse of rheumatic symptoms, with aggravation of the endocardial mischief, terminating fatally.

The somewhat meagre clinical history above detailed represents to a fair degree the course of infectious endocarditis. The points of especial interest are worthy of more distinct mention, and are as follows:

a. The cause of the disease in this case was undoubtedly rheumatism. There was no focus of infection in any portion of the body. This is contrary to the general rule, for the cases analyzed by Prof. Osler more frequently originated from other causes than rheumatism.

b. The occurrence of pneumonia in the course of the disease is worthy of remark. Frequently pneumonia occurs synchronously with the development of the cardiac inflammation, or even anterior to that process; so that the question has been discussed whether the pneumonia is not the primary infective process. Developing in the middle period of the disease, our case would lead one to infer that it was probably an accidental complication, more liable to occur on account of the disturbances in the circulation; markedly more so, if the right heart, as in our case, was involved.

c. The usual characteristic symptoms were present to a high degree, —intermitting fever, sweats, diarrhœa, dyspnœa, and rapid pulse. The course of the fever was so distinct and is so instructive that it is well worth while to give it in full. It is characterized by marked inter-

mittency. It is appended with the record of the pulse and respiration during the last three weeks of the patient's illness.

Record of temperature.

	A.M.	P.M.	
Oct. 3,		104°	
" 4,	$102\frac{2}{5}$°	$102\frac{4}{5}$°	
" 5,	$102\frac{3}{5}$°	$102\frac{4}{5}$°	
" 6,	102°	$103\frac{3}{5}$°	
" 7,	102°	$98\frac{2}{5}$°	
" 8,	$99\frac{2}{5}$°	$100\frac{1}{5}$°	
" 9,	$97\frac{4}{5}$°	$97\frac{3}{5}$°	
" 10,	$96\frac{3}{5}$°	$96\frac{4}{5}$°	
" 11,	$96\frac{2}{5}$°	99°	
" 12,	98°	98°	
" 13,	97°	$99\frac{3}{5}$°	
" 14,	$98\frac{3}{5}$°	$99\frac{2}{5}$°	
" 15,	$99\frac{2}{5}$°	101°	
" 16,	$98\frac{2}{5}$°	$100\frac{1}{5}$°	
" 17,	$97\frac{4}{5}$°	$99\frac{2}{5}$°	
" 18,	$98\frac{2}{5}$°	$100\frac{3}{5}$°	
" 19,	99°	$101\frac{3}{5}$°	
" 20,	$101\frac{3}{5}$°	$100\frac{3}{5}$°	
" 21,	$102\frac{2}{5}$°	$100\frac{4}{5}$°	Endocarditis.
" 22,	$100\frac{1}{5}$°	$100\frac{3}{5}$°	
" 23,	100°	$100\frac{3}{5}$°	
" 24,	$100\frac{2}{5}$°	$102\frac{2}{5}$°	
" 25,	$101\frac{1}{5}$°	$100\frac{4}{5}$°	
" 26,	$100\frac{3}{5}$°	$101\frac{2}{5}$°	
" 27,	$101\frac{2}{5}$°	$101\frac{3}{5}$°	
" 28,	$102\frac{3}{5}$°	$98\frac{1}{5}$°	
" 29,	$100\frac{1}{5}$°	$100\frac{1}{5}$°	
" 30,	$100\frac{4}{5}$°	$102\frac{1}{5}$°	
" 31,	$101\frac{3}{5}$°	$98\frac{1}{5}$°	
Nov. 1,	$99\frac{4}{5}$°	$102\frac{2}{5}$°	Pneumonia.
" 2,	$99\frac{1}{5}$°	102°	
" 3,	$99\frac{1}{5}$°	$100\frac{1}{5}$°	
" 4,	$102\frac{3}{5}$°	$102\frac{4}{5}$°	
" 5,	$102\frac{3}{5}$°	$103\frac{3}{5}$°	
" 6,	$103\frac{1}{5}$°	103°	
" 7,	$101\frac{2}{5}$°	$101\frac{4}{5}$°	
" 8,	$99\frac{1}{5}$°	104°	
" 9,	103°	$101\frac{3}{5}$°	
" 10,	102°	104°	
" 11,	$98\frac{3}{5}$°	$98\frac{2}{5}$°	
" 12,	$99\frac{2}{5}$°	$103\frac{1}{5}$°	
" 13,	$101\frac{2}{5}$°	$99\frac{2}{5}$°	
" 14,	$98\frac{4}{5}$°	$98\frac{2}{5}$°	

			A.M.			P.M.
Nov. 15,			$98\frac{2}{5}°$			$101\frac{2}{5}°$
" 16,			$101\frac{1}{5}°$			$100\frac{1}{5}°$
" 17,			$101\frac{4}{5}°$			$102\frac{1}{5}°$
" 18,			$101\frac{4}{5}°$			$102\frac{1}{5}°$
" 19,			$102°$			$103\frac{3}{5}°$
" 20,	Resp.	Pulse.	$101\frac{4}{5}°$	Resp.	Pulse.	$98\frac{2}{5}°$
" 21,	28	124	$102\frac{1}{5}°$	32	140	$103\frac{4}{5}°$
" 22,	25	100	$96\frac{2}{5}°$	30	112	$99\frac{1}{5}°$
" 23,	28	124	$102°$	30	117	$101\frac{3}{5}°$
" 24,	32	112	$101\frac{2}{5}°$	28	115	$103\frac{2}{5}°$
" 25,	28	108	$101\frac{1}{5}°$	20	100	$101\frac{4}{5}°$
" 26,	28	108	$101\frac{1}{5}°$	28	148	$102\frac{3}{5}°$
" 27,	24	100	$100\frac{4}{5}°$	26	106	$102\frac{4}{5}°$
" 28,	30	121	$100\frac{4}{5}°$	34	112	$102\frac{3}{5}°$
" 29,	30	112	$101\frac{4}{5}°$	40	118	$102°$
" 30,	28	100	$100\frac{3}{5}°$	38	156	$103\frac{3}{5}°$
Dec. 1,	28	110	$99\frac{4}{5}°$	24	114	$98\frac{3}{5}°$
" 2,	28	108	$99\frac{1}{5}°$	44	132	$102\frac{1}{5}°$
" 3,	32	120	$102°$	34	140	$103\frac{2}{5}°$
" 4,	30	120	$101\frac{4}{5}°$	30	126	$103\frac{3}{5}°$
" 5,	21	106	$100\frac{4}{5}°$	32	144	$103\frac{3}{5}°$
" 6,	30	130	$103°$	38	168	$103\frac{3}{5}°$
" 7,	30	135	$103\frac{2}{5}°$	48	150	$103\frac{3}{5}°$
" 8,	42	150	$104°$	44	138	$103\frac{3}{5}°$
" 9,	36	120	$103\frac{3}{5}°$			

d. The appearance of the inflammatory lesions is remarkable. It was found on careful examination that no actual ulceration took place, but that the process was proliferative in nature, it being represented by the outgrowths on the valves.

Lancereaux described some cases which presented this appearance. Attention should be called to the occurrence of micrococci in the inflammatory products, not only of the endocardium, but in the glomeruli of the kidneys as well. The occurrence of the inflammation in the right ventricle is also worthy of remark. The absence of inflammation in this cavity has been said to be due to the absence of oxygenated blood. This case, as well as others of a like nature, certainly shows that a septic inflammation, to say the least, can take place in this locality.

December 11, 1884.

11. *A case of cardiac aneurism.*

Exhibited by Dr. J. S. Neff.

William N., colored, æt. 40 years. Family record good. No evidence of venereal disease. His previous history showed nothing of importance until two and a half years ago, when he had acute inflammatory rheumatism. I could not obtain any satisfactory history of endo- or pericardial inflammation at that time. He appeared to make a good recovery and remained well until one and a half years ago, when he noticed palpitation of the heart and dyspnœa upon slight exertion, soon followed by cough, which was rather persistent. There was no œdema at this time, at least not sufficient to have attracted his attention. He improved upon rest and some medication received at a dispensary. After this first attack, until admission to the Philadelphia Hospital, he was able to work, although always susceptible to palpitation and shortness of breathing upon extraordinary exertion, with one exception, which was one of his so-called attacks, and described as "catching cold," which would increase the above-named symptoms to such an extent that he was compelled to remain in the house for several weeks last August. Here, again, there was no sudden exacerbation of the symptoms alluded to.

He was admitted to the medical ward of the hospital on the 25th of November, 1884, at which time he presented the following conditions:

Orthopnœa intense, cough persistent and troublesome, accompanied by hæmoptysis, palpitation of the heart excited by moving in bed, general anasarca, skin on limbs and scrotum cracking in place from distention, deep pitting on pressure even on chest, face, and forehead. Bowels constipated; urine scanty, containing one-tenth of one per cent. of albumen; no casts. Pulse weak and frequent, although the peculiarity known as Corrigan's pulse was distinguishable.

Physical examination revealed marked and peculiar pulsations of the great vessels of the neck. Impulse of heart seen disseminated over an area of about two inches. Cardiac dulness extended from upper border of third rib, on left side of sternum, to liver, and horizontally on a line of fifth rib, from three-quarters inch to the right to four and a half inches to the left of sternum—the apex beat being felt in the seventh interspace (one and a half inches to the left and two and a half inches below the nipple). Upon auscultation, a loud blowing diastolic murmur was heard, commencing immediately below the aortic valves on a level

with the third rib, and transmitted downward and toward the left, being quite loud at the ensiform cartilage and apex, with its seat of greatest intensity over the left side of sternum on a level with the fourth costal cartilage. This murmur was not transmitted in any other direction. As to its exact time, I should state that it commenced immediately after the first sound, lasting through the second, and continuing almost through the period of rest.

A systolic murmur was also heard at the base of heart, and was transmitted toward both infraclavicular regions and at times was heard in the carotids. It commenced with the first sound, but did not last through it. It was not heard over the body of the heart. In the region of the apex a third murmur—systolic—was heard, which could be clearly separated from the preceding, as being less harsh and occurring later in the systole. It was also heard over the left auricle, and as far to the left as the axillary line. It was not audible posteriorly.

Physical examination of the lungs showed a condition of passive congestion. There were no nervous phenomena excepting some slight delirium, lasting for a short time and due to imperfect aëration of blood.

The diagnosis was undoubted aortic insufficiency with dilated hypertrophy of left ventricle and some mitral regurgitation. Under treatment improvement commenced at once and continued until December 11th, when he was able to walk around the ward without discomfort. Cough had disappeared, no shortness of breathing or palpitation without undue exertion. Dropsy almost entirely absent. The urine still contained a trace of albumen. Physical signs of the heart were unchanged, save an impulse increased in force. Pulse was 78, strong, and retaining to a marked degree the "trip-hammer" characteristic.

The general condition remained unchanged until December 30th, when it was noticed that the œdema was making headway, returning dyspnœa, etc. This gradual increase in severity of symptoms continued, and on Jan. 5th there was considerable hæmoptysis, the physical signs being the same again as on admission, excepting dulness and bronchial breathing over both bases of the lungs posteriorly. Patient gradually grew worse and died on Jan. 19, 1885.

Autopsy made by Dr. Shakespeare, the pathologist of the hospital, the notes of which were written by my resident, Dr. Hickman, and are as follows:

External appearances.—General anasarca, especially of lower extremities, most marked in the left.

Heart.—Pericardial cavity contained some serous fluid but no evidences of pericarditis. The heart was greatly enlarged; the enlargement being

principally in left ventricle. *Right ventricle* contained dark clotted blood, the wall being a quarter inch in thickness, very firm, and marked post-mortem staining present. Nothing else noteworthy on this side. *Left ventricle* was greatly dilated and the wall much hypertrophied, being fully three-quarters of an inch thick. The endocardium was intensely stained post mortem. Ventricular wall was quite soft. The ascending aorta also showed intense post-mortem staining of inner lining, and the latter was in a condition of moderately extensive arteritis.

Coronary arteries appeared normal at their mouths, the right being somewhat dilated and more or less atheromatous. Mitral orifice appeared normal, also the surface of the auricle. The ventricular endocardium presented nothing noteworthy except post-mortem staining.

There were on anterior leaflets of mitral valve at base a few endocardial yellow streaks running horizontally. At juncture of left cusp of aortic valve with ventricular cusp there was a mass of cheesy material beneath the endocardium about a half inch in diametor. The mitral cusp showed a rupture through and into the pocket of posterior cusp, where the two joined. The latter cusp was also perforated in its right third, and there was an aneurismal cavity extending into upper portion of septum between the ventricles, the apex of the dilatation corresponding to the upper septum of right ventricle; the aneurismal sac showed a dilatation toward left ventricle and a rupture into the latter by an orifice admitting the end of thumb, the upper border of the opening being formed by the two affected leaflets above mentioned. There were some vegetations upon the under surface of the aortic cusp. The aneurism was the size of a walnut and contained no clots.

Both pleural cavities contained sero-sanguineous fluid. No adhesions except in one point at lower lobe. The two lobes were slightly collapsed; they presented no other abnormal appearance except the existence of two embolic infarcts; one small wedge-shaped, size of a hazelnut, superficial near the inner edge of upper lobe at its anterior surface; pleural surface congested; another, the size of a hen's egg, projecting above the surface at the inner edge of lower and at the outer edge of upper lobe, about two inches from base of lower lobe, at its anterior aspect. The two lobes were adherent at the point of the infarct and their substance appeared to run together. The cut surface showed the infarct to be made up of tissue of both lobes, mainly of lower, and a line of division of the two lobes was quite perceptible. The area of infarct was dark red and granular, sharply outlined. At centre of the pleural surface of this large infarct there was an irregular area of reddish substance. No pleuritic adhesions with chest wall corresponding to this infarct, and no decided pleuritis.

The upper lobe of right side contained two infarcts, size of a hickory-nut, along its anterior lower edge; middle lobe one in a similar position; lower lobe contained four, varying in size. This lung presented nothing else abnormal.

Liver normal in size, flabby and smooth surface, nothing else abnormal except some congestion and probable increase of fibrous tissue, it being extremely difficult to push finger in the cut surface.

Spleen normal in size, pulpy, dark brown in color, with slightly increased thickness of the capsule.

The kidneys were normal in size, and presented no marked unhealthy appearance, these organs being so stained post mortem as to make it impossible to judge accurately of their condition. Amount of cortex appeared normal.

The pathological change seemed to originate at the sinus of Valsalva and penetrate into the septum, then causing a bulging of the two affected aortic leaflets, making a valvular aneurism (secondary) which ruptured into left ventricle. Clinically these cases are of little value, as none have been diagnosed other than valvular disease. It seems quite remarkable, however, that there was no sudden onset of symptoms to mark the ruptures of valves. *February* 12, 1885.

---

12. *Heart from a case of phthisis, with mitral incompetence.*

Exhibited by Dr. H. M. Fisher.

Sarah B., æt. 36 years, widow, was admitted to the Episcopal Hospital February 6, 1885. The following notes of the case were furnished me by Dr. O. Hopkinson, Jr., the resident physician:

Patient has had eight children, and menstruation was regularly performed till about Christmas, when it ceased. Since then she has suffered somewhat from leucorrhœa and painful micturition. None of patient's immediate family appear to have been phthisical, but she herself has never been very strong, and has had slight cough for about a year. The cough has been more troublesome for about six weeks, and six days before admission she coughed up about "a cupful of blood," and had another hemorrhage two days before admission. She was pale, and had a yellowish, earthy hue, and was markedly pigeon-breasted. Her heart appeared hypertrophied, but the extent of the hypertrophy could not very easily be determined on account of the deformity of the chest.

The first mitral sound was thin, and the second accentuated, but when I first examined her I was unable to detect a murmur at the apex. There was increased percussion resonance over the apices of both lungs. Expiration slightly prolonged, and subcrepitant râles under left clavicle after coughing. Fine crackling heard also over upper half of right lung. Ordered elixir ferri, quiniæ et strychniæ f℥j t. d. Expectoration is scanty and cough not very troublesone.

Feb. 20. A systolic pulsation noticed this morning in left external jugular. Apex systolic murmur not very clearly transmitted to axilla. The first aortic sound is rather indistinct. The second pulmonary sound accentuated. Impairment of resonance over bases of both lungs, the percussion note over base of right lung being almost flat; breath sounds here very feeble.

Patient's bladder is very much distended, and almost complete retention of urine since yesterday evening. Urine slightly albuminous, and microscope shows pus cells, and triple phosphates in abundance, but no casts. Ordered tinct. digitalis, gtt. xxx, twice daily; tr. hyoscyam. ♏x; spir. æther. nitros. f℥j; potass. citrat. grs. xv; mist. acac. q. s., ad. f℥ss, ter vel quater in die.

21*st.* Patient had an epileptiform convulsion this evening, which lasted about fifteen minutes, and she remained unconscious about five minutes after convulsive movements had ceased. This was neither preceded nor followed by vomiting.

22*d.* I found patient conscious and complaining of no pain or headache. She had had another convulsion at 6 A. M.

23*d.* After being catheterized this morning had another convulsion. Respirations 13, and there is a pause of two or three seconds at the end of each expiration. No paralysis. Can be roused, but is decidedly apathetic.

24*th.* Died this morning in a comatose condition.

Post-mortem examination four hours after death.—Head: Pia mater everywhere much injected, with subarachnoidal effusion or lymph, most marked over left superior parietal lobules. Lymph channels generally opaque. Slight capillary hemorrhages in substance of pia, one of the most marked of which is just anterior to fissure of Rolando on left side.

Thorax: Both *lungs* show old adhesions; those on the right side being most firm. Cheesy nodules surrounding thickened bronchi in upper lobes of both lungs, with catarrhal pneumonic patches disseminated through both lungs.

Pericardium contains about an ounce of opaque, straw-colored fluid.

Heart: Right ventricle contains black fluid blood, right auricle also, Left ventricle empty; its walls are about an inch in thickness; left auricle contains fluid blood. Pulmonary valve contains a "chicken-fat" clot. The aortic leaflets are somewhat thickened and rigid, and the valve is not absolutely competent. The mitral leaflets are much thickened, particularly the posterior leaflet, which is somewhat adherent to the ventricular wall, and would necessarily have rendered the valve incompetent. *March* 25, 1885.

---

13. *Case of aortic and mitral incompetence.*

Exhibited by Dr. H. M. Fisher.

Michael S., æt. 59 years, night-watchman, was admitted to the Episcopal Hospital January 29, 1885. For the following notes I am indebted to Dr. J. K. Mitchell, the resident physician:

Has always been a hard drinker, and for several years has suffered from occasional attacks of cough and dyspnœa. Three days ago was seized with sudden dyspnœa and orthopnœa. The patient was very fat, and decidedly cyanosed, had short cough, and his legs were very œdematous. An old abdominal hernia was very prominent. On auscultation of his chest sonorous, sibilant, and some moist râles were heard, also a double murmur at aortic cartilage, partially replacing first sound, and entirely replacing second, and a loud systolic murmur at apex. Heart evidently hypertrophied, but difficult to define limits of præcordial dulness, owing to extreme thickness of chest walls. Ordered tr. digitalis gtt. xxxv (= ♏xv) every four hours, and directed urine to be measured; dry cups to bases of both lungs, and strychniæ gr. $\frac{1}{30}$ t. d.

Jan. 30. Passed about 20–25 ounces of urine, which was milky, and showed by usual tests a very large amount of albumen; has very great dyspnœa. Ordered tr. digitalis ♏x hypodermically, and then ♏xxx every two hours.

Feb. 2. Breathing somewhat better. Ordered bases of both lungs cupped again, and scillæ, pil. hydrarg. āā gr. j; pulv. digitalis, grs. ij, ter in die.

5th. Dyspnœa again greater. Tr. digitalis ♏xxx every three hours.

6th. Dropped as he walked across the ward to-day, became purple in the face, and was dying before Dr. Mitchell reached him.

Post-mortem examination, twenty hours after death.—Belly walls show

three inches of fat; no fluid in abdominal cavity. *Kidneys* normal or slightly congested. Enormous masses of fat upon omentum, which half conceal intestines. *Liver* very large, soft, brittle, and much congested. *Lungs* intensely congested. *Heart* enormously hypertrophied, enveloped in fat; vessels very much distended and cavities filled with dark fluid blood, except the right auricle, which was collapsed. Left side of heart much overgrown, and its ventricular walls greatly thickened, but apparently no muscular degeneration. Both left cavities partially filled by very firm ante-mortem clot, extending through auriculo-ventricular orifice, and having the consistence and appearance of muscular tissue. None of the valves would hold; the mitral valve was large enough to admit two fingers easily. There were signs of old inflammation at the commencement of the aorta, and several white fibrinous patches on the external surface of the heart. *March* 26, 1885.

---

14. *Heart showing dilated hypertrophy, from a case of calculous pyelitis.*

Exhibited by Dr. H. M. Fisher.

B. R., æt. 35 years, an Italian tailor, was admitted to the Episcopal Hospital under Dr. M. J. Lewis's care, October 18, 1884. The following notes of this case were furnished me by Dr. J. K. Mitchell, the resident physician. Had rheumatism three years ago and has suffered from palpitation of the heart and dyspnœa for three months. No pain in lumbar region, or increased frequency of micturition, seems to have been complained of and he gave no history of "renal colic." He applied for admission to the Pennsylvania Hospital on account of his dyspnœa and dropsy, in July, remained under treatment there for six weeks and was discharged August 15th.

Upon admission to the Episcopal Hospital it was noted that his abdomen measured thirty-three inches at the navel, and that his chest was large and extremely fat, but apparently not œdematous. The apex-beat of the heart was at the upper border of the sixth rib, five and half inches to the left of the sternum. Heart broad at base, dulness began at third interspace and extended to line of apex-beat, a line drawn horizontally to sternum comprised the base; heart's dulness pyramidal in shape with base downward. No murmurs, sounds muffled and distant, no friction sounds. Posteriorly, right side dull up to line of scapula. Breath sounds and fremitus almost absent on right side. Nasal twang

to voice just below angle of scapula. Effusion in right pleural cavity and pericardium. Base of left lung posteriorly dull on percussion. Œdema of feet and foreskin. Urine: specific gravity 1.010; Heller's test showed a marked ring; boiling and acetic acid gave a distinct cloud of albumen; the microscope showed large pale, granular, and pus casts.

Oct. 20. Soft murmur heard to-day at fourth interspace midway between sternum and nipple and somewhat presystolic in time. Pericardial friction. Measurement from pubes to umbilicus, eight inches. Measurement from umbilicus to ensiform cartilage, ten inches.

21*st.* For first time noticed a flutter in venous pulse, second sound appears to be double, but there is no true murmur. Movement of left chest diminished. Breathing is harsh on left side and expiration prolonged.

22*d.* Over the whole of the præcordial region from midway between sternum and nipple to nipple line below fifth rib a double pulsation corresponding to the two sounds of the heart is felt. The point of greatest intensity is at about the sixth interspace, midway between the nipple and the sternum. Percussion dulness over left chest diminished.

28*th.* Dr. Lewis aspirated twenty-seven ounces of dark straw-colored fluid from patient's right pleural cavity; this gave some relief.

29*th.* Fremitus can be felt over the whole of the base of patient's right lung this morning. Line of absolute dulness from the base up to within half an inch of the angle of the scapula. On the left side there is dulness from the base to a point three inches below the angle of the scapula. Pulse 100; respirations 38; has scanty, mucous, blood-tinged expectoration.

30*th.* Urine scanty during last twenty-four hours. Ordered fluid extract of jaborandi, gtt. xx. This was followed by profuse sweating.

Nov. 4. Urine measured eight ounces. From this time till Jan. 1st, when I came on duty, the œdema was held in check by the administration of jaborandi and punctures of the legs and scrotum. I found him suffering from pretty general anasarca, and on account of the evidences of extreme cardiac dilatation I ordered him tincture of digitalis, gtt. xxxv, every four hours, and, in accordance with Balfour's recommendation, directed that after about five drachms of the tincture (about forty grains of the drug) had been administered, the digitalis should either be temporarily suspended, or given in very much smaller doses. Under this treatment the dropsy was, for a time, considerably reduced, but very free diuresis did not occur.

Jan. 10. Urine in last twenty-four hours, forty-six to forty-eight ounces.

12*th*. Fifty-four ounces. Apex-beat now in sixth interspace, two and a half inches to left of nipple line. In the third space, cardiac dulness extends from one inch to the right of the median line to two and three-quarters inches to the left of it. There is a marked diastolic murmur heard at the xiphoid cartilage, and a systolic murmur at or near the point of apex beat.

Feb. 5. Pleural effusion greatly diminished. Urine varies from forty-eight to fifty-six ounces. Tincture of digitalis intermitted every third day generally for twenty-four hours. Has now and then some abdominal pain. For the last two days has complained of pain in the sixth right interspace and there is a slight yellowing of the conjunctivæ. For the relief of these symptoms he was ordered to be leeched over the region of the liver.

6*th*. Pain relieved and jaundice has diminished.

8*th*. Found dead in bed this morning.

Post-mortem examination thirty hours after death.—Five quarts of bloody serum were removed from the right pleural cavity. The right lung was much compressed by this effusion. A hard white nodule surrounded by cicatricial tissue in lower lobe of right lung. The *spleen* was enlarged, had a nutmeg appearance, and weighed thirteen ounces. *Liver* very large, rather paler than normal, but no spots of infarction could be seen. It weighed five pounds six ounces. The *right kidney* was very small, felt hard and lumpy, weighed four ounces, and was in a state of complete cystic degeneration; a small calculus was found embedded in its substance. The *left kidney* was very large, weighing fourteen ounces, smooth, hard, brittle, and congested; its capsule was non-adherent. The *heart* was huge, weighing just two pounds. Its walls were thickened throughout, even the walls of the right auricle being hypertrophied. Both ventricles were much dilated. The tricuspid valve admitted two fingers and contained a large, firm, white clot. The mitral valve admitted three fingers easily. The aortic valve was not thoroughly competent. There were no marked evidences of recent valvulitis. No clot was found in the left heart.

In examining the clinical history of this case one cannot, I think, fail to be impressed by the extreme latency of the renal symptoms, at least of the symptoms that could have pointed to pyelitis. The disease may have originated with the attack of rheumatism three years ago, perhaps the pain then complained of may have been due to the passage of a calculus along the ureter, but there were no bladder symptoms while he was in the hospital, and there was no pain complained of at that time that could well be referred to the passage of a calculus. The

right kidney being rendered functionally incompetent by cystic degeneration, compensatory hypertrophy of the left kidney appears to have been set up. This organ likewise was impaired in function owing to undue strain perhaps, and the microscope shows that its secreting cells are unduly granular. Though the heart showed evidence of old valvular disease, this alone would, I think, be hardly sufficient to account for the immense dilatation and hypertrophy that here existed. The extreme hypertrophy was, I think, rather secondary to the disturbance in the renal function. *March* 26, 1885.

---

15. *Double aneurism of ascending and transverse aortic arch.*

Exhibited by Dr. Henry Beates, Jr.

A somewhat detailed history is given of this case as the cause of the disease, other than that of a generally poor constitutional condition, is rather obscure. Mr. T. B., German, æt. 37 years, vocation music printer, furnishes the following: Father died suddenly, presumably of cardiac disease, as he had had acute articular rheumatism twenty-five years previously, a time, it may be noted, prior to the conception of the patient from whom this specimen was obtained. The mother succumbed at the age of 71, to an attack of pneumonia (acute ?). Two brothers and a sister died of phthisis, and one brother from insanity (general paralysis ?) which was a sequel of typhoid fever. There is no other instance of nervous disease known in the ancestry of either paternal or maternal side. Mr. B. himself suffered from the usual illnesses of childhood, but has never had rheumatism or syphilis. Twelve years ago while at work at a press, a lever struck him rather forcibly on the chest. This blow, while strong, did not occasion especial inconvenience and developed an ordinary bruise, which soon disappeared leaving nothing remaining. During the summer of 1876 he noticed that his usual exertions were accompanied with shortness of breath and undue cardiac action. Vague symptoms confined to the thorax occasionally occurred, but attracted no special attention. This condition, gradually augmenting, existed until the winter of 1880–81, when he suffered his first attack of dyspnœa. Laboring under an ordinary cold at the time, the disturbance was attributed to it and ignored. Similar paroxysms occurred throughout the year, finally being complicated with neuralgia of the right intercostal and occasionally of the trunks of the brachial plexus. A thoroughly established dry paroxysmal cough confirmed the patient's

belief that he was a victim of phthisis. At this time he was first seen. The physical signs clearly indicated aneurism. The apex beat was in the sixth interspace and to the left of the nipple line. Epigastric pulsation, percussion dulness in second and third interspaces extending to the right as far as the mammary line, expansive bulging of this area, with bruit; expansion being synchronous with apex beat, and other valvular sounds negative, dissipated doubt as to the character of the affection. The area of dulness of the second interspace comparatively rapidly developed toward the axillary line and contemporaneously did the impulse visibly augment. This was considered to be dependent upon a rapid dilatation of a thin portion of the sac. Under rigid treatment of rest and diet this special area ceased to pulsate and materially diminished. Notwithstanding this the aortic systolic bruit remained, and the phenomena of bronchial spasm and paralysis of the vocal membrane steadily progressed until death from suffocation terminated life. The specimen demonstrates advanced atheroma of the ascending and transverse arch with fusiform dilatation extending from its origin to the commencement of the descending portion. Originating from the superior or convex wall of this aneurism, about one inch toward the proximal portion from the innominate artery, is this sacculated aneurism which has attained the size of a lemon. Between this latter and the trachea there exists a portion of the fusiform sac which presses upon and partially occludes the trachea. The secondary aneurism communicated with the primary by a small orifice and the diminution of symptoms in that portion occupying the second interspace is now fully explained. The recurrent laryngeal branch of the pneumogastric is seen to be flattened by pressure of the aneurism against the anterior wall of the trachea and the immediate cause of the fatal asphyxia demonstrated. *March* 26, 1885.

---

16. *Aneurism of arch of aorta, with rupture into the trachea in two places and perforation of the œsophagus.*

Exhibited by Dr. William Osler.

W. J., æt. 54 years, colored, a teamster by occupation, and accustomed to do heavy work, was admitted to the University Hospital January 7, 1885. Had been healthy and strong; no history of syphilis. In August, 1882, he began to suffer with pains in the chest and left shoulder,

but he did not have any serious inconvenience until September, 1883, when he was attacked with cough and thoracic trouble, possibly pulmonary, which kept him in the house and in bed for several months. It was not until May of last year that he was able to work. Since July he has had at times attacks of shortness of breath, with wheezing, and often at night has had to sit up in bed. Within the past three weeks the pains in the shoulder and down the left arm have become very severe and the cough and shortness of breath have increased.

Note on admission was as follows: Well-built man, face thin, general musculature good. Inspiration rough and noisy, expiration long and harsh and often accompanied by a brazen, laryngeal cough. Respirations 18 per minute. Can rest in the recumbent position. On inspection, the left side of the neck is much flattened, especially above the clavicle, and the sterno-mastoid muscle on this side is evidently atrophied. Apex beat visible in normal position, no abnormal pulsation; slight visible pulsation in vessels of neck. Palpation in the ordinary way negative, but on firm pressure with one palm on the upper bone of sternum, and the other on the back, a decided impulse can be felt, and the second sound is accentuated; deep pressure reveals pulsation above sternum and behind left sterno-clavicular joint. Percussion reveals a slight area of dulness in left half of manubrium sterni and beneath left sterno-clavicular joint. Heart's dulness not increased. Auscultation: heart sounds clear. At sterno-clavicular joint, when the breath is held, there is a soft double murmur, the diastolic the loudest, and the second sound is markedly accentuated. These murmurs can be heard over the left carotid and on supra-sternal notch. The tugging at trachea is marked on elevating the larynx; pupils equal.

The left radial pulse is smaller than the right and is slightly retarded. Lungs negative; loud tracheal and bronchial stridor; no pressure signs on either bronchus. Patient expectorates much thin muco-serous fluid which is blood-tinged, and at times there are more consistent sputa containing much blood. He was ordered to take twenty grains of potassium iodide three times a day and rest quietly in bed. No restriction as to diet. On examination, laryngoscopically, the left cord was found immobile.

Within three weeks he was greatly benefited as regards the pains, the cough, and wheezing, and the blood had disappeared from the sputum. Throughout February he remained very well, having occasional attacks of spasmodic coughing at night which were relieved by spt. æther. co. His general health improved and he was allowed to go about the ward. Sputum occasionally streaked with blood. On March 19th he was

shown to the class, and the following changes noted: Slight increase in sub-sternal dulness on firm percussion; more marked accentuation of second sound over this region; persistence of the double murmur, which was now also to be heard just to the right of the sternum and at the aortic cartilage, and at this point it was the loudest. No increase in the pulsation, but in certain lights a slight impulse at the upper part of the sternum was visible.

At the beginning of the month he began to be more wheezy; the stridor was very marked and the dyspnœa became urgent, so that he had to sit up in bed. Sometimes these attacks would come on suddenly. On the 3d and 4th the dyspnœa was severe, aud he got much weaker. On the 5th and 6th he spat up some bright blood, but not in any great amount, and gradually sank, dying at 9.30 P. M. The specimen removed by Dr. Hamaker shows an aneurism of the aortic arch which occupied a position between the first bone of the sternum and the spine, very firm, solid, and about the size of an orange. The entire arch is dilated, but the sac of the aneurism involves specially the upper and posterior part and is lined with dense yellow fibrinous laminæ. The orifices of the innominate and left carotid are free; that of the left subclavian is considerably narrowed by atheromatous ridges. The great veins are not compressed. The left recurrent laryngeal passes round the sac and is much stretched and looks thinned; the right is normal. The trachea is much compressed about the middle of its course, and the aneurism causes a marked bulging on the left side, and here two perforations can be seen. The upper one, about six centimetres from the bifurcation, is only two or three millimetres in diameter, and the tissue about it is puckered and dark, and the mucosa somewhat fibroid. The lower orifice is smaller and looks more recent. Neither of these leads directly into the sac proper, but into a small pocket situated between the dense laminæ of fibrin and the thinned tracheal wall. On inspecting the œsophagus, an oval perforation was found seven cubic centimetres from the cricoid cartilage, which communicated directly with the sac, but was partially blocked with fibrinous clots. The stomach was found distended with fresh clots, and there was much altered blood in the small intestine. Collapse and congestion at the bases were the only changes in the lungs. The heart was not hypertrophied; valves were normal; muscle substance flabby and in a state of fatty degeneration and brown atrophy.

The points of interest in this case were the repeated bleedings extending over several months, and the associated wasting of the muscles of the left side of the neck. At first the bleeding was looked upon as an indication that erosion of the trachea had occurred, but subsequently it

was thought more probable that it came from the swollen mucosa at the site of compression. No doubt the first supposition was the correct one, as the upper of the perforations had probably been the source of the bleeding, but the firm leathery clots effectually prevented any profuse hemorrhage. The final bleeding into the œsophagus also took place very slowly, probably during the last thirty-one hours of life, as there was dark, much altered blood in the ileum.

It is impossible to say upon what the atrophy of the neck muscles depended, as no careful dissection was made of the nerves in that region. Possibly the sympathetic was affected, but there were no differences in the pupils. *April* 9, 1885.

IV. THE ORGANS OF RESPIRATION.

1. *Posterior nasal hypertrophy in situ; together with an exostosis from the vomer.*

Exhibited by Dr. Carl Seiler.

The specimen which I have the honor to present to the Society this evening, came into my possession somewhat unexpectedly, and was discovered to be pathological only by accident, in the following manner:

Being interested in nasal diseases, I was very desirous of obtaining human heads for the purpose of studying the somewhat intricate anatomy of the nasal cavities, and last winter my friend Dr. J. M. Barton, informed me that the head of a subject from the German Hospital was at my disposal. I was unable to learn of what the man had died, or what the symptoms of his disease had been; which was, at the time, very immaterial to me.

The head was placed in a blanket full of salt and ice, and in the course of twelve hours was frozen solid, so that with an ordinary carpenter's saw I was able to cut it in half; carrying the section longitudinally through the nose so as to leave the septum intact.

The anatomical relation of the parts on the right side of the nasal cavity was perfectly normal, and the visible surface of the septum, which was still covering the left side, was also normal. When, however, this partition was removed, a very marked enlargement of the posterior end of the lower turbinated bone, on the left side, was noticed, which on closer examination proved to be a posterior hypertrophy so commonly seen with the rhinoscopic mirror in cases of nasal catarrh. On the left surface of the vomer a projection was also seen, which proved to be an exostosis; the existence of which, in nasal diseases, is denied by some authors.

The histological characteristics of the hypertrophies I have detailed in a paper read before this Society two years ago; suffice it to say, therefore, that this tumor-like projection into the nasal cavity consists of a hypertrophy of the erectile tissue underlying the nasal mucous membrane. Its presence is due to a long-continued catarrhal inflammation, which, by the infiltration of its inflammatory products into this

cavernous tissue, has distended the venous sinuses, and has increased the thickness of the connective-tissue wall of the caverns, so that when they are empty of their blood a perceptible swelling or tumor still remains, as is seen in the specimen.

The reason why these hypertrophies occur more frequently at the anterior or posterior ends of the lower turbinated bones, must be looked for in the fact that the blood, favored by gravitation, distends the caverns of the erectile tissue more easily under the excitement of local irritation in these localities, and that the anterior as well as the posterior ends of the lower turbinated bones, forming the entrance to the ingoing or outgoing air current, are more liable to irritation by irritants contained in the respired air, than any other portion of the nasal cavity.

The history of the case so far as the nasal disease is concerned, may be readily inferred from the pathological conditions present in the specimen; and probably did not differ in the least from that of thousands of cases of hypertrophic nasal catarrh which so frequently come under our notice. *September* 27, 1883.

---

2. *On the pathology of phthisis pulmonalis and its laryngeal complications.*

Read by Dr. Carl Seiler.

In bringing the much discussed subject of the pathology of phthisis again before the Society, an apology is perhaps owing which will be found in the renewed interest which the investigations of Koch in the etiology of this disease have aroused. It is, however, not the purpose of this paper to discuss the bacillus theory of tuberculosis nor to enter in detail into the pathology of phthisis. The main object is to sketch the laryngeal complications of phthisis, and to point out their differences from those noticed in tuberculosis. This can, however, not well be done without first considering, in a general way, the differences between the two diseases themselves, and I will, therefore, in a few words relate my individual views on this subject—views which are not quite in accord with those of many of the authors on pathology, but which have forced themselves upon me by pathological study and clinical observations.

Let us briefly review first the characteristics of the disease known as *tuberculosis.* It may be defined as an auto-infectious disease manifesting itself primarily in the production of minute neoplasms, which may be localized in one organ and invade others by metastasis, as when they occur in

the lung and later show themselves in the larynx, or they may be disseminated throughout the system invading all the organs, as in general tuberculosis. These neoplasms, or miliary tubercles as they are termed, rapidly undergo retrograde metamorphosis which ends in caseation.

Histologically considered, these tubercles consist mainly of a collection of granular lymphoid cells surrounded by a delicate reticulated tissue. Large, often-branched, and multinucleated cells are frequently seen, which, according to some authors, are true giant cells and considered by them as characteristic of tubercle, but which I am inclined to look upon with others as sections of obstructed lymphatics, or lymph spaces, the endothelium of which has proliferated. As the tubercles grow older and the retrograde metamorphosis progresses, the cellular elements become converted into a collection of granular material and finally a cheesy degeneration takes place which involves the whole tubercle, obliterating it as such. The deposit of tubercles in the lungs occurring primarily in the interalveolar connective tissue, gives rise to a variety of changes in the lung tissue itself, the magnitude of which depends upon the number of the tubercles and the rapidity with which they are formed and decay, and also upon the condition of the system at large.

In the first place, a low grade of inflammation is set up in the immediate neighborhood of the tubercle, the exciting cause being the tubercle itself. A small-celled infiltration invades the alveolar walls. The epithelial cells lining the alveoli proliferate and become detached and swollen, thus filling the lumen of the alveoli, causing consolidation of the lung tissue. The pressure exerted upon the capillaries in the alveolar walls by the filling of the alveoli as well as by the infiltration of the connective tissue interferes with the circulation. Nutrition of the tissue being thus cut off and the absorption of the inflammatory products by the lymph channels made impossible, death of the tissue must necessarily set in sooner or later. At the same time the inflammation being cut short no new inflammatory products are thrown out, and those already existing undergo retrograde metamorphosis into cheesy degeneration.

This same pathological picture is found in every organ of the body and is but slightly modified by the histological differences of the tissues in which the tubercle is deposited. Thus, for instance, in the mucous membrane of the larynx it is the glands and follicles which furnish the proliferating epithelium and because the capillary network is spread over a much larger area than is possible in the thin alveolar walls of the lungs, death of the tissue by obstruction of the circulation—*i. e.*, ulcera-

tion—occurs in spots while the surrounding tissue is still in a state of inflammation.

The ultimate result of pulmonary tuberculosis, as we all know, is a rapid breaking down of the lung tissue and death of the individual within a few months from the onset of the disease. There are, however, a few cases in which the deposit of tubercles takes place in a very limited portion of the lung tissue only, and which will, under favorable circumstances, remain isolated, becoming encysted by a wall of fully formed connective tissue, the result of a higher grade of inflammation, to which the tubercular process has given rise in the surrounding tissue. There are also some few cases in which a limited number of tubercles is deposited in various portions of the lungs and which by their presence give rise to an inflammation followed by consolidation and decay of the lung tissue. This consolidation differs, however, from that produced directly by the tubercular process, and is identical with the pathological process seen in phthisis.

The outbreak of tubercle in an organ or throughout the body is, in my opinion, not dependent upon the introduction into the system of infectious material which originates external to it, but is caused by the dissemination of infectious material existing within the system, though it may have remained latent for a long time. This infectious material, however, can only be found under a peculiar condition of the system in the form of cheesy deposits, and this condition is known as scrofula. Scrofula, existing as it does in certain animals and individuals of the human race, depends, according to Dr. Formad, whose theory seems plausible, in an abnormal richness of cellular elements and narrowness of the lymph spaces of the connective tissue. If, then, under these circumstances an inflammation occurs the narrow lymph spaces become clogged by the inflammatory products unusually rich in cellular elements, which, undergoing retrograde metamorphosis, become cheesy deposits instead of being carried off or becoming organized as is the case in the normal condition of the tissue. A cheesy deposit of this kind may remain dormant in the organ in which it has been formed for an indefinite period, but if by any chance portions of it enter the lymphatic circulation, tuberculosis is the result.

The transmission of tuberculosis from one person to another which is occasionally met with, can easily be accounted for by the facts that the person becoming infected was either scrofulous from the start, although the diathesis may not have shown itself prior to the deposit of tubercle, or, what is more likely, the early history of glandular enlargement, and so forth, has been overlooked and the fatigue and privation consequent

to the nursing of the tubercular patient have given the necessary impetus for the production of the disease; or else the vitiated atmosphere, fatigue, loss of sleep, and the mental strain and anxiety prior to and after the death of a husband or wife affected with tuberculosis, reduce a formerly normal constitution to a scrofulous one and render the faithful nurse liable to contract the disease.

Transmission of tuberculosis from patients to nurses or attending physicians, where the latter are not exposed to the evil effects of bad sanitary surroundings and where they are not scrofulous, has, I think, never been observed. In regard to the causation of the disease by the introduction of bacilli or bacteria into the system of healthy, non-scrofulous persons, I am not prepared to express an opinion, since the subject has as yet not been sufficiently investigated, and the experiments on animals are, to my mind, not conclusive enough to warrant the acceptance of the bacillus theory of the causation of tuberculosis.

Scrofula usually is inherited, but it may be acquired, and is then caused by anything which lowers the vitality of the system at large, and particularly diminishes the histogenetic power of the products of inflammation.

Phthisis, on the other hand, may be defined as a progressive consolidation of the lung tissue, due to a more or less localized inflammation, affecting primarily the apices and undergoing retrograde metamorphosis. Phthisis is an inflammatory disease. Histologically considered, this consolidation of the lung tissue consists of an infiltration of the alveoli by inflammatory products, and exudation from the bloodvessels containing a number of leucocytes. Under the microscope it closely resembles the alveolar contents seen in catarrhal pneumonia; that is, it shows a fibrinous structure, intermingled with granular débris, red and white blood-corpuscles. This infiltration begins to soften and undergo a sort of mucoid degeneration when the epithelium of the alveolar walls proliferates. The epithelial cells, on account of a want of vitality, instead of multiplying by division, simply increase in size, and becoming detached, intermingle with the contents of the alveoli, filling them completely. They also undergo degeneration so that they are soon not recognizable as cells. At the same time, a small-celled infiltration occurs in the alveolar walls and in the interlobular connective tissue, which, possessing a certain amount of histogenetic power, changes into a low form of fibrous tissue. This infiltration is noticed, also, very early in the disease, in the peri-bronchial connective tissue. The macerating influence of the semi-fluid contents of the alveoli upon the epithelium soon denudes the alveolar walls of their protecting covering, while the

pressure of the interalveolar infiltration upon the capillaries interferes with circulation, without, however, obstructing it entirely, and thus the first step toward destruction of the lung tissue by ulceration is taken.

The gradual breaking down of the interalveolar tissue merges the contiguous air vesicles into one, and a cavity is formed, which may or may not be surrounded by a wall of newly formed connective tissue, the formation of which depends upon the amount of inflammation excited in the contiguous lung tissue by the ulcerative process, and also upon the amount of histogenetic power possessed by the inflammatory products. If, in the progress of decay, a larger bloodvessel is opened, a hemorrhage is the result. After a time, the interlobular and peri-bronchial connective tissue is largely increased in thickness by a deposit of newly formed fibrous tissue, which gives rise to an alteration of the circulation in the bronchial mucous membrane, causing first inflammation, with proliferation of the epithelium on the surface, as well as in the glands and follicles, and later anæmia by pressure upon the capillaries, and often ulceration. There are, however, many cases in which, by proper nourishment and better oxygenation of the blood, the histogenetic power of the inflammatory products is increased, while the alveoli are evacuated of their contents by expectoration, and the consequence is an isolation of the cavities by a wall of strong connective tissue, and the formation of fully formed fibrous tissue in the interalveolar and interlobular connective tissue, which formative process tends to cut short the retrograde changes in the lung tissue.

The different forms and stages of phthisis, as they are recognized and described by some authors, are merely differences in the degree of the inflammatory process, or in the extent of the retrograde change.

Phthisis is produced by a peculiar condition of the system at large, which may be designated as impaired vitality, and by a peculiar predisposition of the lung tissue to inflammation, which may be termed weakness of the lungs. Both these conditions may be, and mostly are, inherited, but in many cases they are acquired. The children of parents who are phthisical or syphilitic, have been drunkards or suffered from cancerous disease, inherit a lowered vitality, not necessarily scrofula, which shows itself in a want of histogenetic power of the inflammatory products, and also in a weakness of the lungs and upper air passages, predisposing them to chronic inflammation.

Insufficient or inappropriate food, want of exercise and of fresh air, long-continued mental strain, peripheral nervous irritation, and acquired syphilis, are among the most potent factors which will produce this same lowered vitality of the system and its histological elements in individuals

who have not inherited this peculiarity. Thus, for instance, uterine disease will frequently give rise to phthisis, by peripheral irritation and the consequent lowering of the vitality.

Phthisis will be developed in other cases by the prolonged sojourn in badly ventilated rooms or workshops, the air of which is laden with dust or noxious gases, and thus we find that shoemakers, carpet-weavers, cigar-makers, and operatives in cotton mills supply a very large percentage of all cases of phthisis in large cities. Obstruction of the nose by hypertrophic nasal catarrh or by tumors, also may, and often does, produce phthisis in a considerable number of cases, as I have had occasion to observe: because if the nasal cavities are obstructed, and respiration has to be carried on through the mouth, the lungs are not sufficiently expanded, and the inadequate oxygenation of the blood gradually lowers the vitality of the system. And finally, we see phthisis developed often during the convalescence from exhaustive diseases, such as typhoid fever, diphtheria, and others, if the lung tissue is exposed to an injury giving rise to inflammation.

However, both in the inherited and acquired predisposition, it is necessary that an injury should be inflicted upon the lung tissue before the inflammation can be set up. This injury usually consists in exposure to cold—that is, a chilling of the surface of the body; but other factors are also frequently the cause of the initial inflammation, as, for instance, the inhalation of irritating vapors, or of air charged with particles of solid matter, the sucking into the air vesicles of purulent mucus from the bronchioles in a state of inflammation, traumatic injury to the chest walls, the formation of gummata in or around the lungs, and others of a like nature. But these causes are not of sufficient potency to produce phthisis in subjects of vigorous constitution, or cannot produce much destruction of lung tissue if the vitality of the system be elevated.

Thus it will be seen that proper hygienic measures are capable of not only preventing the outbreak of phthisis in subjects predisposed to it by heredity or otherwise, but also are able to cure phthisical patients in whom the destruction of lung tissue has not gone too far.

If, on the other hand, the process of destruction has gone on for a long time and has involved a large portion of the lung, the system gradually loses more and more of its vitality and finally becomes *scrofulous* by the narrowing of the lymph spaces in the connective tissue. When this point has been reached tubercles appear in the affected lung tissue and bring about an early fatal termination of the disease. But be it understood that the low-type chronic inflammation has existed long

before the tubercles have made their appearance and it alone, without the intervention of the neoplasms, may cause death.

It is this complication and intermingling of the two diseases which have given rise to the confusion of terms existing in the literature on the subject of consumption, for we find almost everywhere the terms phthisis and tuberculosis used as synonyms.

The laryngeal manifestations of phthisis are so varied and manifold that is is difficult to give a general idea of their clinical features and pathology, and it will, therefore, be more comprehensive to describe them seriatim. They are never seen to occur prior to the disease of the lungs, although the latter may be so slight as to escape detection by the ordinary methods of diagnosis, and the laryngoscope then furnishes the earliest evidences of phthisis. Those lesions of the larynx giving rise to subjective symptoms occur quite frequently, that is, in about thirty-three per cent. of all cases; while certain changes in the shape of portions of the larynx and in the color of the mucous membrane, not noticed by the patient, are seen very early in the disease in the greater majority of cases. These latter changes consist in an ashy paleness of the mucous membrane which spreads to the pharynx, palate, and mouth, and is different from the anæmia seen in other diseases. This pallor usually persists throughout the course of the disease, but there are cases in which here and there spots of heightened color and patches of ecchymosis are seen, usually in those portions of the larynx which are subject to increase and long-continued irritation, such as the free margin of the epiglottis, the inner surface of the arytenoids, the vocal cords, etc. No tumefaction of the tissues, or ulceration, or even inflammation being present, this condition does not give rise to subjective symptoms, passing unnoticed unless the laryngoscope be used as a means of diagnosis of the lung trouble.

The pathological process in the mucous membrane giving rise to this particular pallor I am not prepared to describe, not having had an opportunity to examine microscopically the tissue of a larynx exhibiting this condition only.

Frequently this anæmia is accompanied by tumefaction of certain portions of the larynx, a swelling which somewhat resembles the œdematous distention of the mucous membrane met with in acute and chronic laryngitis, for which it may be mistaken. The most common seat of the swelling is the tissue around the arytenoid cartilages, extending upward into the ary-epiglottic fold. It thus assumes a peculiar shape resembling a pear, from which resemblance the term "pyriform" swelling has been applied to it. The tumefaction affects either the tissue around both cartilages in an equal degree—that is, it is bilateral; or one side is more

swollen than the other, and if this is the case the greatest amount of intumescence is always found on the side of greatest lung implication. These pyriform swellings at times become so large as to interfere with the approximation of the vocal cords, and to encroach upon the lumen of the laryngeal cavity.

Less frequently, and usually later in the disease, the tissue covering the upper portion of the posterior aspect of the epiglottis also becomes tumefied to a considerable extent, and gives the organ a peculiar rolled-up shape, resembling in the laryngeal image a grub worm. But the swellings are not confined to the localities mentioned, and may occur in any portion of the larynx. Thus there are cases in which the arytenoid cartilages, the epiglottis, and the ventricular bands, and probably also the vocal cords are in such a state of intumescence as to prevent a view of the vocal cords and encroach to such an extent upon the lumen of the laryngeal cavity as to necessitate tracheotomy to prolong life. Under the microscope these swellings are seen to be due to an extensive infiltration into the submucous connective tissue of small granular lymphoid cells. The normally numerous glands are also invaded by the infiltration and deposit of a fibrous tissue around the acini and ducts. The lumena of the ducts and of the acini are filled with unusually large proliferated epithelial cells, which in many instances have undergone retrograde changes, leaving the ducts and acini filled with a granular débris. The perivascular connective tissue is considerably increased in thickness and the lymphatics filled with lymphoid cells. A certain amount of serous exudation is also present, which is demonstrated by the fact that a considerable shrinkage takes place in the size of the swellings when the specimen is kept after removal from the body for a few hours before immersing it in the hardening solution. Nowhere are miliary tubercles or cheesy deposits to be seen in the tissue. In many cases no other manifestations than these tumefactions are noticed, and in a few instances I have seen the pyriform swellings disappear under appropriate treatment together with the healing of the affected lung. There is another class of cases in which either no tumefaction of the tissues occurs or in which it is very slight and spread over a larger surface. In these, ulcerations begin to appear in various portions of the larynx which are in appearance like the shallow erosions of catarrhal inflammation of the larynx. They usually are situated at the free margin of the epiglottis, in the inter-arytenoid space, and on the laryngeal face of the arytenoid cartilages, less frequently on the ventricular bands, ary-epiglottic folds, and the vocal cords.

In post-mortem examinations I have often found them in the trachea

and bronchi, and usually occupying in the former that side on which the greatest amount of disease in the lung was found. In the larynx their shape varies with the position which they occupy, being linear on the vocal cords, ovoid on the ventricular bands, and oval or roundish on the epiglottis. Their tendency is to spread on the surface of the mucous membrane, but not to invade the deeper structures, except where the excretory ducts of glands become involved, when a pit-like depression in the bed of the ulcer can be seen. A grayish-white, moderately stiff excretion covers the surface, and they are very sensitive to irritation, giving rise to pain on deglutition and phonation according to their situation. Under the microscope the tissue does not present any marked difference from the picture presented by the tumefactions, except that the small-celled infiltration is more densely crowded around the ulcers and the epithelium at their edges is turbid and granular. When a gland duct is implicated, its epithelium has disappeared and it is seen to be filled with granular débris. The lymph spaces are occluded by cellular elements near the edge of the ulcer, and the capillaries and smaller vessels almost filled with proliferated endothelium.

In other cases still we see projections resembling exuberant granulations in the interarytenoid space, often reaching into the laryngeal cavity, thus interfering with the approximation of the cords and giving rise to aphonia. These neoplasms may remain unchanged for a considerable length of time, to be destroyed by the ulcerative process toward the end of the disease, or they may disappear spontaneously like papillary growths on the external integument of the body are prone to do. The only specimen of a growth of this kind which I obtained by evulsion with the forceps, showed under the microscope its epithelial origin, being identical with the tissue of an ordinary papilloma, except that the connective tissue stroma was densely infiltrated with small lymphoid cells so as to be barely distinguishable except by teasing the sections.

These manifestations of phthisis in the larynx remain often unchanged for a long time, or make but little progress as the lung disease advances, or they may disappear altogether under appropriate treatment, even before the disease in the lung tissue has been fully arrested in those cases which terminate in recovery. But as soon as tubercles are deposited in the lungs the laryngeal lesions also develop a tubercular character, and a rapid change for the worse sets in.

The same etiological factors which give rise to the lung disease, viz., the lowered vitality of the system, the want of histogenetic power of the inflammatory products, and the predisposition to inflammation or weakness of the organ, also cause the laryngeal implication, and if any

injury by cold or otherwise starts an inflammatory process in the laryngeal mucous membrane, it will be of a phthisical type. The continuity of tissue between the alveoli of the lung and the mucous membrane must also be taken into consideration as an etiological factor. But I do not believe with some authors that the irritating influence of the expectoration from the lungs can give rise to the erosions or ulcerations seen in the larynx, as it does not become inspissated, and, therefore, cannot act long enough to destroy the epithelium. These ulcers are rather due to mechanical injuries depriving a small portion of the mucous membrane of its epithelium which is not regenerated. And now let us glance for a moment at the picture presented by the laryngeal lesions in tuberculosis, which has been so admirably delineated by my friend, Dr. J. S. Cohen, in an exhaustive paper read before the Society a year ago, which I am sorely tempted to quote verbatim, were it not for want of space and time, and I must, therefore, confine myself to mentioning only the salient points of contrast as they have presented themselves to my observation. The laryngeal lesions in tuberculosis giving rise to subjective symptoms are much more frequent, occurring as they do in about fifty-three per cent. of all cases. The primary deposit of tubercles in the larynx, although not usual or frequent, has been observed in several cases, one of which came under my own observation. The mucous membrane is usually of a livid red color, which is intensified around the ulcerations. The tumefaction of the tissue is more circumscribed, and occurs more generally in the anterior portion of the larynx. The ulcerations are deeper, have raised and serrated edges, and cause often great destruction of tissue. Pseudo-papillary neoplasms are never seen, and true miliary tubercles as well as cheesy deposits have been demonstrated in the tissue of the larynx. At the same time, complete occlusion of capillaries and lymph spaces in the neighborhood of the ulcerations may be seen under the microscope. And, finally, the existence of these lesions is but a short one, for they depend upon the deposit of tubercles in large numbers, and rapidly progress toward a fatal end.

As in tuberculosis of the lung or general tuberculosis, laryngeal tuberculosis is due to scrofula.

And now let us briefly consider what pathology has to teach us in the prognosis and treatment of these diseases. Tuberculosis from the start is a fatal disease, except in the rare cases in which the deposit of the neoplasms is limited in number and in which they become encapsulated, the poison being antagonized by considerable power of the histological elements of the tissues and the inflammatory product to form new tissue. Treatment avails us nothing, for I will ask, Have we

time so to improve the general health and to change the anatomical condition of the connective tissue to prevent the ulcerative process and have the resulting inflammation terminate in resolution? Clinical experience answers "No" to this question. All we can do in these cases is to alleviate the suffering and prolong life as long as possible and make it endurable. We can, however, prevent the outbreak of the disease by preventing the formation of the initial infectious material and by changing the scrofulous character of the system of our patients in early life. And, further, we can use our influence as medical advisers of families to prevent the intermarriage of blood relations, of syphilitic and of scrofulous persons. The prognosis of phthisis, on the other hand, is not nearly as bad, and we may reasonably hope for recovery if the proper treatment be instituted early in the disease.

Since the low type of inflammation is dependent upon a lowering of the vitality from any cause, we must direct our efforts to elevate and strengthen the constitution by proper feeding and healthful exercise in the open air, and prevent the too rapid cell death by the judicious exhibition of alcoholic stimulants. Digestion, as a rule, being impaired, we should exercise great caution in giving drugs and especially cough syrups. At the same time we must strive to evacuate the alveoli of their contents, which by entering and remaining in the bronchioles irritate the mucous membrane and give rise to the frequent and distressing cough. This may be accomplished with marvellous success by forcible inhalations of warm and moist vapors, not under pressure, however, for, as has been lately demonstrated, the lung tissue is not air tight when undue pressure is exerted upon the alveolar walls for any length of time, and air will enter the bloodvessels causing instant death. By thus removing the irritant from the bronchial tubes, the cough is alleviated much more quickly and more satisfactorily than is possible with expectorants acting through the stomach. The treatment of cavities in the lung tissue, as instituted by our illustrious member, Dr. W. Pepper, and its success by injections and drainage, are too well known for me to dilate upon here.

As regards the lesions in the larynx, only the mildest possible applications in the mildest possible manner should be employed, for be it remembered that mechanical injury will give rise to the ulcerations, and, therefore, all harsh treatment with the probang or brush should be avoided.

The treatment as thus outlined has proved eminently successful in my hands, as well as in those of others, and I am happy to be able to say that there are numerous cases of cured phthisis in this city at the present

time. But even the best and most successful treatment is not equal in efficiency to the prevention of the disease; and, as in the case of tuberculosis, we can do far more good by teaching our patients to observe hygienic laws and to elevate the vitality of their system, thus preventing the possible outbreak of the dread disease. We should also be very careful to search for and remove any source of irritation which might ultimately produce phthisis.

To sum up my remarks, I will state that, in my opinion, *tuberculosis* is produced by infectious material entering the lymphatic circulation which does not originate outside of the body, and that the disease is incurable. Further, that *phthisis* is due to a low grade of inflammation of the lung tissue, and is curable in the earlier stages. That both tuberculosis and phthisis give rise to laryngeal complications and lesions which are distinct in character, and differ from each other both in their clinical features and in the pathological changes of the tissues. And finally, that both diseases, although totally different in their etiology and initial pathological lesions, may coexist and produce each other, and that the indiscriminate use of the terms tuberculosis and phthisis in our literature must necessarily mislead the student, and make careful investigation extremely difficult.

Dr. J. C. Wilson, in response to a call by the President, said that he had listened with interest to the reading of the paper. The field covered was too great to permit a detailed discussion of the principal points. Two points, however, appeared to warrant comment:

First, Dr. Seiler had several times made use of the expression "tuberculous material not derived from the exterior." If he had understood the paper, Dr. Seiler had not indicated his views as to the nature and source of this "tuberculous material;" and he asked if Dr. Seiler followed the older doctrine—that of Buhl—or if he had some new theory as to the etiology of tubercle?

Secondly, Dr. Seiler failed to make clear his means of recognizing tubercles, either clinically or in the laboratory.

It would be of interest to hear his views upon this vexed question. In a recent work, Hamilton, of Aberdeen, again sought to establish a histological criterion for tubercle—the presence of giant cells under a peculiar arrangement. The pathological points were the modes of degeneration—1, caseous; 2, fibroid. To the latter Dr. Seiler made no allusion. He thought, further, that sufficient emphasis had not been laid on the presence of tubercle in the various forms of phthisis as seen in post-mortem examinations. He heartily concurred in the hopeful views as to the curability of certain forms of chronic lung disease when

treatment was instituted at an early period. Nothing had exerted a more unfavorable influence upon the therapeutics of such diseases than the false view that the constitutional tubercular diathesis invariably antedated the local lesions of pulmonary consumption.

Dr. F. P. Henry remarked that Dr. Seiler's paper was so comprehensive that he found it impossible to refer to more than a few of the points contained in it. He was not inclined to draw so broad a line of distinction between that form of pulmonary disease in which miliary nodules predominated and that in which the deposit was in larger caseous masses. Like Dr. Seiler, he was by no means convinced of the primary importance of the bacillus as a cause of tuberculosis, but he was inclined, however, to attribute to it a prominent part in the production of the secondary symptoms of phthisis—those of systemic infection—which are largely septic in character. The symptoms of interference with oxidation, caused by even extensive destruction of pulmonary tissue, were subordinate to those of systemic infection caused by absorption of the contents of cavities. The presence of the bacillus in the contents of these cavities was indispensable to the production of changes capable of producing this systemic infection. A small ulcerating cavity communicating with the absorbent vessels is more disastrous in its effects than a larger cavity shut out from the absorbents by a lining membrane or wall of fibrous tissue. He understood Dr. Seiler to deny the existence of the giant cell, and to make the statement that cross-sections of blood- and lymph-vessels have been mistaken for it. Dr. Henry did not agree with him in this view, but thought that the irregular contour of the giant cell and its granular protoplasm were sufficiently characteristic. Additional evidence of the existence of this cell was furnished by the experiment of introducing beneath the skin of an animal two thin glass covers fastened together. In the interspace of the glasses giant cells had been found, and in such an experiment there could be no question of the cross-section of vessels. Dr. Seiler had several times referred to what was known here and elsewhere as Formad's theory of tuberculosis, which is: That in certain animals predisposed to phthisis, and presumably in some human beings, the lymph spaces are abnormally small, or, in other words, that in a given area of tissue there is to be found a greater number of endothelial cells than in non-strumous animals. He did not think that this theory should be so extensively quoted until some more decided attempt had been made to establish or refute it. This might be readily done, he thought, by counting the cells in a given area of the tissue of strumous animals, and comparing their number with that contained in the same area of

tissue of non-strumous animals. He did not think that any greater difficulty would be met with in this attempt than had been successfully encountered in the enumeration of the blood cells.

Dr. Bruen said that he believed in a hopeful prognosis in the early stages of many varieties of phthisis; even when the process of phthisis is advanced, the management of cases is more successful when the lesions are localized; less advanced lesions are more grave when they are widely disseminated. He thought it had been proved that phthisis could be produced by inhalation of inorganic irritating particles, especially if there was inherited predisposition to phthisis or an artificially damaged constitution. Might not bacterial elements, he asked, be among the irritants capable of developing phthisis when inspired in large numbers? And, he thought, they might be even more capable of doing damage than inorganic materials, because they possessed the power of proliferation. He agreed in the main with the views expressed by Dr. Seiler, and he considered the paper most instructive and interesting.

Dr. Mills thought it worth while to note the frequent occurrence of tuberculosis among those afflicted with chronic nervous and mental diseases. At institutions for the feeble-minded and insane, phthisis or tuberculosis is a common cause of death. This fact, he thought, lends support to the views of Formad rather than to those of Koch.

Dr. J. T. Eskridge had observed that some who had participated in the discussion had referred to the views of the pathology of tuberculosis expressed by Dr. Seiler, and to those entertained by Dr. Formad, in order to prove the same thing. He regarded the theories of each of these gentlemen as widely different. If tuberculosis is the result of inflammation in a person whose lymph channels are abnormally narrow, as claimed by the latter, he could not see that phthisis differs from tuberculosis, as maintained by the former. In regard to tuberculosis being frequently developed in chronic diseases of the brain and cord, throwing light on the pathology of the former, he thought that the association of these diseases proves nothing more than that a prolonged period of lowered functions of the body is a favorable condition or the development of tuberculosis. He confessed that he did not know what to believe with reference to the pathology of tuberculosis; to his mind there had not been enough proved to establish firmly any theory yet advanced, so that it might be accepted as positive fact. He agreed with Dr. Shakespeare in demanding more pathological investigation ollowing the clinical observation of the disease before he could accept as positive any view of the pathology of tuberculosis. He called attention to the fact that many of the best clinical observers of large experience,

such as Flint, Da Costa, Hughes-Bennett, considered tuberculosis and phthisis to be identical.

Dr. Davis asked Dr. Seiler if he taught that tubercle was caused by a caseous focus, to which Dr. Seiler replied in the affirmative. Dr. Davis said that it was important to know whether this is the case or not, as German surgeons excise caseous glands, not so much for the deformity they produce as to obviate the liability to general infection, and he asked if Dr. Seiler would sanction this practice. As regards the possibility of cure, he believed, with Koster, Billroth, and König, that tubercle is a local affection and not a general disease. He had seen tuberculosis as marked in the knee as in the lung, the miliary tubercles being within an eighth or a quarter of an inch of each other. He had also seen tumor albus of the knee recover without operation. If tuberculosis of the knee can be recovered from, he believed the same might occur in tuberculosis of the lungs. *October* 22, 1883.

---

3. *Phthisis with empyema.*

Exhibited by Dr. H. M. Fisher.

The patient, J. C., æt. 21 years, was admitted to the Episcopal Hospital March 17, 1883. The following notes of the case were taken by Dr. George M. Boyd, the resident physician:

Patient stated that he had had a slight cough for one year, but was not much annoyed with it until about one month ago, when he was seized with severe pain in the left chest, accompanied by chilly sensations and difficulty of breathing. Upon admission he presented all the symptoms of left pleural effusion, absent vocal fremitus, tubular breathing, and bronchophony in the neighborhood of the spinal column on the left side. His chest was tapped on the morning of March 21st, and three pints of a semi-purulent fluid were evacuated. The operation was followed by great improvement in the patient's symptoms. Three weeks later he left the hospital contrary to advice. He was readmitted April 20th, and stated that, soon after leaving the hospital, the pain in the side returned, followed by dyspnœa.

April 23. Paracentesis thoracis was performed by Dr. Henry, and fifty-six ounces of purulent fluid were drawn off, and the operation again afforded great relief. A violent fit of coughing followed the withdrawal of the canula. The heart's apex beat was found, before the operation,

to be immediately below the right nipple; after the operation, it was found to have shifted one inch to the left of its previous position.

May 5. Dr. Forbes operated at Dr. Henry's request, making two openings into the left pleural cavity, one at the fifth interspace, the other at the fourth and to the right of the first. Ten ounces of purulent fluid were withdrawn by means of the aspirator, and a soft rubber catheter was passed in at one of the openings and out at the other. The pleural sac was then ordered to be washed out daily with a solution of corrosive sublimate gr. j–ʒj.

During the summer the patient's general condition seemed for a time to improve; his appetite, however, continued obstinately bad, and he had constipation alternating with diarrhœa. In October it was noted that he was losing flesh and strength rapidly, and that there was much œdema of the feet and legs. During this month diarrhœa became a constant symptom, and death occurred November 22d.

Post-mortem examination, ten hours after death.—The body is extremely emaciated. The left lung is contracted to about one-fourth of its normal size, contains in its upper lobe some cheesy masses with areas of catarrhal pneumonic infiltration. The left pleural cavity contains about five ounces of ichorous pus. The parietal layer of the left pleura is so tightly adherent to the chest wall that it is impossible to detach it without dissection. The pulmonary layer is also tightly adherent to the contracted left lung, the lobes of which are firmly matted together by adhesions. The *right* lung also presents numerous cheesy foci with large areas of catarrhal pneumonic infiltration. The heart is rather small, and its tissue is pale, but its valves appear normal. The liver weighs six pounds six and a half ounces, its tissue is pale, and it has a *markedly waxy appearance.* The spleen is much enlarged, its tissue *firm and of a dusky red hue.* Numerous *yellowish-white nodules* are also seen in it, the largest of which is perhaps the size of a small pin's head. The kidneys are rather large, their capsule is non-adherent, and their tissues rather paler than normal. Numerous *minute whitish nodules* are also found to be scattered through the tissue of both kidneys. These appear rather more numerous and larger in the cortical portions, but are also found in the medullary portions. From some of the larger nodules a whitish puriform substance can be squeezed out with the blade of the knife. With the naked eye the exact nature of the above-mentioned infiltrations of the spleen and kidneys is difficult to determine. Nothing abnormal was noticed in the intestinal tract; except in the ileum, where an area of intense congestion was noticed about one yard from the ileo-cæcal valve, but no ulceration was anywhere detected.

My view of the sequence of pathological events in this case is the following: First, catarrhal pneumonia with the production of cheesy foci; secondly, scrofulous inflammation of the pleura with attendant exudation, which from the start was probably more or less purulent; thirdly, the infiltration of the *liver*, *spleen*, and possibly also the *kidneys* with amyloid matter.

The exact nature of the yellowish-white nodules in the spleen and kidneys being undetermined, I cannot assign to them a positive place in the chain of scrofulous processes; but, from the absence of any macroscopic evidence of embolic infarctions, or of any appearance of infarction in the one microscopic section of the kidney I had the opportunity of examining (kindly made for me by Dr. Henry), I should conclude that these were also cheesy foci, and their production may, perhaps, have nearly coincided in point of time with the production of the cheesy foci in the lungs above alluded to. *December* 27, 1883.

---

4. *Pleuro-pneumonia complicated with delirium tremens.*

Exhibited by Dr. J. H. Musser.

I present this specimen to-night on account of its perfection. It is the lower lobe of the right lung in the stage of red hepatization, as indicated by the appearance, weight, etc. Almost the entire pleural surface, including the diaphragmatic, is covered with recent lymph, the layer averaging one-half inch in thickness. The tongue of the lung dipping into the space between the diaphragm and the thoracic wall, is not solidified entirely. Here the lymph is abundant, and the contiguous portion of the lung is hepatized, as if the inflammatory process extended from the pleura; this peripheral hepatized portion is but one-fourth of an inch wide, the inner succeeding portion is not solidified.

The patient died eighteen hours after admission to the hospital from heart clot. When admitted there were evidence of its formation, and, in addition, he had delirium tremens. The pneumonia was distinctly recognized. There were no signs of simple or diaphragmatic pleurisy. It was remarked at the autopsy, on removing the sternum, the extreme distention of the right heart, especially the auricle. On opening the heart, hypertrophied from other causes, the right side was found filled with blood, and an enormous ante-mortem clot entwined around the leaflets of the tricuspid valve, and extending through the auricle into

the pulmonary vessels. A similar clot was found in the left heart. The kidneys were congested, and commencing cirrhosis appeared manifest.

The history of the case antecedent to the admission to the hospital is as follows: The patient had been on a "spree" for two weeks and five days before admission, and had had a severe chill followed by the symptoms of pneumonia. Two days after the chill the mania developed, and on the day of admission he had been found wandering about the streets by a crony, who brought him to the hospital. He was 41 years old, a boss machinist, single, and of intemperate habits. *December* 27, 1883.

---

5. *Phthisis following empyema; amyloid kidneys; cancer of uterus.*

Exhibited by Dr. W. E. Hughes.

Amanda F., white, æt. 38 years, was admitted to the University Hospital for cancer of the uterus. She had been a sewing woman, and had been much exposed to drafts. Her mother died of cancer of the uterus. There was no phthisical family history. One of her children died of tubercular meningitis. While in the hospital she complained of pulmonary symptoms, and physical examination of her lungs showed on the left, posteriorly, flatness down to midway between the spine and the angle of the scapula with blowing-breathing and gurgling râles; anteriorly, tympany with metallic, cavernous breathing; at the base a small amount of fluid free to move. On the right, hyper-resonance with exaggerated breathing, and at the apex moist râles. Her general condition was much below par. She had a troublesome loose cough, with muco-purulent expectoration, and pleuritic pains through both sides of her chest. Five and a half years before she had taken a severe cold, from which she dated all her trouble. With the cold there had been severe pleuritic pain in the left side, some dyspnœa, and slight muco-purulent expectoration, occasionally streaked with blood; in a month she had lost twenty pounds. Afterward the acute symptoms disappeared, the pain grew less severe, the cough looser, and the expectoration quite profuse. She slowly lost ground till about a year before, when, after a succession of heavy colds, her condition deteriorated more rapidly. There were more dyspnœa, more cough, and an occasional rise of temperature preceded by chilliness. During this year she had several pulmonary hemorrhages. For a month the frequency of micturition had been much increased, but the urine contained no albumen, though the

quantity was increased, and the specific gravity somewhat lowered. The first symptoms of cancer of the uterus had appeared about seven months before. For more than a month after admission she improved; then, a day after a rather profuse pulmonary hemorrhage, she developed a typical uræmic condition. The urine was very scanty, and loaded with albumen, but contained neither tube casts nor blood. The uræmic condition disappeared after two days, and the urine increased to its former quantity, all but a trace of the albumen disappearing. Two weeks after this, for the first time, a few waxy and epithelial casts were found in the urine. From this time on, the quantity of urine passed daily varied from fifty ounces to seventy ounces; its specific gravity ranged between 1.008 and 1.015, and the proportion of albumen contained steadily increased, till, toward the end, it became as much as one-third of the bulk of the urine. At no time were very many tube casts present, though they were never absent; they were either waxy or epithelial. She died January 1, 1884, of uræmia, which had gradually developed,

Autopsy, five hours after death.—Much emaciation. The left lung was compressed, atrophied, and firmly bound down in the posterior part of the pleural cavity. The remainder of the cavity contained gas and about eight ounces of sero-pus. The pleura was much thickened, and transformed into a pyogenic membrane. The lung itself was hollowed out into a large cavity with suppurating walls by an extensive series of bronchial dilatations with more or less destruction of lung tissue. The lung was so torn in its removal that it was impossible to say whether or not there had been a communication between it and the pleural cavity. The right lung was emphysematous, and contained some tubercular and cheesy deposits at the apex. The heart weighed nine ounces, its right cavities contained an unusually developed ante-mortem clot closely moulded to the pulmonary valve. The kidneys weighed eleven and a half ounces, and presented very characteristic amyloid change. The body of the uterus was unchanged, but its cervix and the upper part of the vagina were destroyed by cancerous ulceration. There was no infiltration of the lymphatic glands. Other organs normal.

January 24, 1884.

6. *General tuberculosis of serous membranes.*

Exhibited by Dr. W. E. Hughes.

Caroline K., white, æt. 17 years, was admitted to the University Hospital November 3, 1883. There was a history of articular rheumatism in father and mother. The family was free from consumption. She herself had been perfectly well till eight months previous, when she developed symptoms of acute pleurisy. The acute symptoms subsided after a few days, and, with the exception of slight dyspnœa and hacking cough, she soon felt as well as before. Two months afterward she had pain, swelling, and redness, involving, successively, all the large joints of the body, lasting ten weeks, and disappearing completely. From the onset of the articular rheumatism her strength and flesh failed steadily, appetite grew poor, and digestion bad, dyspnœa and cough increased slightly. Five weeks before admission she began to have occasionally sharp pains through the abdomen, and noticed that the abdomen was gradually enlarging. When first examined she was pale, somewhat emaciated, had hacking cough, with mucous expectoration, slight constant dyspnœa, very little increased on exertion. The right pleural cavity was filled with fluid up to the third rib. The abdomen was much distended with fluid free to move. The heart was normal in size, but there was a strong mitral systolic murmur. She had an irregular hectic fever. Under treatment the pleural effusion rapidly subsided, that in the abdomen less rapidly. One month after admission symptoms of meningitis developed, and examination of the eye ground showed descending neuritis. A week afterward a double pericardial friction sound developed over the sternum opposite the third intercostal space. She died December 16th.

Autopsy, seven hours after death.—Thorax: right pleural cavity completely obliterated by organized plastic adhesions, in the adhesions numerous gray miliary tubercles were found. Right lung congested, compressed, and contains scattered miliary tubercles. Left lung contains a few miliary tubercles; pleura normal. Heart normal in size; marked thickening of mitral leaflets, with incompetency. In the pericardium at upper part of anterior surface of left auricle and over base of aorta were a few small grayish granulations, apparently tubercular. Peritoneal cavity contained about two quarts of straw-colored serum. Peritoneum everywhere thickly studded with gray miliary tubercles. Old peritoneal adhesions in several parts of abdomen, notably in left lumbar region, and around pancreas. These old adhesions are filled with

miliary tubercles. Lymphatic glands moderately enlarged, not cheesy. Numerous gray miliary tubercles in membranes of base of brain, especially in Sylvian fissure. No tubercles in any organs except the lungs.

January 24, 1884.

---

7. *Enlarged bronchial glands which had caused intrathoracic pressure.*

Exhibited by Dr. E. T. Bruen.

These specimens were taken from the body of a man, æt. 44 years, who had suffered for some years from chronic bronchitis. The bronchitis was probably due to his exposure to the fumes of coal in the gas-works. There was no emphysema. The bronchial glands are deeply pigmented and much enlarged, forming in all a mass five inches long, three inches broad, and two inches thick. This enlargement surrounds the trachea, and slightly overlaps it anteriorly. A portion of the formation covers the origin of the right bronchus, and the left is also somewhat enclosed by the enlarged glands. In addition, many isolated bronchial glands will be found much increased in size. The lungs presented evidences of chronic bronchitis, and lymphatic irritation. The aorta is atheromatous and dilated; heart normal. This specimen is exhibited chiefly to illustrate the possibilities of intrathoracic pressure from this source. It will be seen that these enlarged glands occasioned serious pressure upon the lower portion of the trachea and the upper portions of the bronchi. During life there were many symptoms traceable to reflex irritation of the pneumogastric nerve, and there were also symptoms of pressure upon the œsophagus. The writer has published a detailed account of the symptoms incident to similar conditions in *The American Journal of the Medical Sciences* for July, 1883. The cause of the enlargement of the bronchial glands in this case must have been the chronic bronchitis, although similar enlargements sometimes follow dilatations of the aorta. It is curious to note that degenerative changes in the lungs, or hepatization, were not observed. *February* 28, 1884.

8. *Carcinoma of larynx.*

Exhibited by Dr. W. E. Hughes.

J. C., æt. 49 years, had been complaining of some alteration of voice for six weeks. He was a man of rather dissolute habits; denied syphilitic infection; had never had his larynx injured or irritated by foreign substances or gases, and had a perfectly good family history. In addition to the change in his voice, which was at first the most marked symptom, there was tickling cough. Soon after this the glands beneath the angle of the jaw enlarged and he began to have fits of dyspnœa. His flesh and strength failed but little, and his appetite remained unimpaired, though a slight trouble with deglutition prevented his eating as much as he would have liked. When first seen, the glands of his neck were enormously enlarged, but painless and still movable. His voice was husky or cracked, sometimes whispering or lost, his breathing difficult and noisy. Alternating with this constant difficulty of breathing were fits of dyspnœa, brought on by no appreciable cause, often so intense as to threaten life. Two days later he died in one of these attacks of dyspnœa before aid could be rendered. For the foregoing facts I am indebted to the kindness of Dr. George J. Preston.

Autopsy, nine hours after death.—Body well nourished. Cervical lymphatic glands enormously enlarged, rather firm, no signs of degeneration. Bronchial glands slightly enlarged. In the cavity of the larynx, above the vocal cords, not involving them but involving the ventricular bands, and extending from them to the top of the larynx, was a firm, pinkish, nodular growth involving the right side most. The epiglottis was so involved in this growth as to have no vestiges remaining of its original shape. The mucous membrane was intact. The growth had left only a narrow slit for the entrance of air, which could easily be completely closed by pressing down the deformed epiglottis. The pharynx and œsophagus were not involved. The cartilages of the larynx were completely ossified, and around the superior cornu a small abscess had formed, resulting, apparently, from a necrotic process in the ossified cornu. The trachea and bronchi were normal, the lungs congested. There was a slight increase in the fibrous tissue of the liver, and in the substance of the right lobe was a small cheesy nodule. The kidneys were granular. On microscopic examination the growth was found to be made up of large, irregular cells, separated into masses, in which was no intercellular substance, by a scanty stroma of connective tissue.

Scattered through the growth were masses of fibro-cartilage not connected with cartilage of the larynx. The mucous membrane was proliferated, and in places prolonged into the subjacent connective tissue, but nowhere did it take part in the new growth. The epithelium lining the glands was much proliferated, and seemed to have been the starting-point of the morbid process. The enlarged lymphatic glands were infiltrated with a growth similar to that in the larynx.

April 10, 1884.

---

9. *Diphtheritic bronchitis; croupous pneumonia.*

Exhibited by Dr. W. E. Hughes.

W. D., white, æt. 43 years, a salesman, was admitted to the University Hospital April 1st. Of rather intemperate habits, he had been on a prolonged spree and much exposed to weather, when, three days before, he had been seized with a severe chill, followed by high fever, and, later, intense dyspnœa, with but little cough and no pain. When first seen he was so weak as to be unable to give a satisfactory history. Face and extremities congested, heart feeble and irregular, breathing rapid and labored. The breath was extremely fetid, but he complained of no throat symptoms and there was no stridor. The cough was hacking, not very troublesome, and he expectorated small quantities of frothy, blood-stained serum. Physical examination showed flatness over the whole right lung, with imperfect bronchial breathing, best marked at the root; over the left lung some impairment of resonance with large moist râles. He died in less than an hour of apnœa.

Autopsy (notes by Dr. Formad), fourteen hours after death.—Pleura of right lung inflamed; plastic exudation; about one pint of serous effusion; left pleura normal. Right lung compressed by the effusion, and uniformly in the beginning of the second stage of croupous pneumonia. Left lung has a spot an inch in diameter in the upper part of the lower lobe pretty far advanced in the second stage of pneumonia; elsewhere it is simply congested and œdematous. Pharynx acutely inflamed, with some spots of superficial ulceration and scattered deposits of false membrane. Tonsils ulcerated, the bottoms of the ulcers sloughy and covered with offensive false membranes. The same condition obtains in the larynx; its surface is softened, reddened, and dotted with false membrane and superficial ulcerations; near the base of the epiglottis is a deep

offensive ulceration one-half inch in diameter. Epiglottis œdematous. In the trachea the condition is more marked than in the larynx; about the middle of the trachea the patches of false membrane become continuous, and clothe the whole inner surface of the tube, growing thicker and more consistent as the bronchi are approached, and traceable into the finest ramifications of the bronchioles; in the larger tubes tubular, in the smallest, solid cylinders. The exudation is but loosely adherent to the mucous membrane, which is red, thickened, or raw. Lymphatic glands of the neck moderately enlarged, red, and softened. Liver, kidneys, and spleen congested, otherwise normal. Heart contains unusually firm white clots. *April* 10, 1884.

---

10. *Diphtheritic croup.*

Exhibited by Dr. W. E. Hughes.

H. G., æt. 4 years, had been ailing for two days; slightly feverish, and complaining of sore throat, when he began to cough and his parents noticed slight difficulty with respiration. A day after this, when I first saw him, there were moderate fever, much inspiratory dyspnœa, muffled cough, and whispering voice. The tonsils and pharynx were covered with patches of false membrane, and the cervical lymphatic glands enlarged. On the second day afterward the dyspnœa became so threatening that I performed tracheotomy. His strength was, at this time, well preserved. After the operation his breathing became perfectly easy, the temperature fell almost to normal, and his general condition improved markedly. Twenty-four hours afterward, however, the temperature rose, the dyspnœa returned, and he died of apnœa fifty hours after the operation.

Autopsy, thirty-six hours after death.—Body well nourished. The tracheotomy incision had divided the isthmus of the thyroid gland, and the second, third, and fourth tracheal cartilages. The edges of the wound were covered with false membrane. The cavity of the larynx was completely filled by a plug of firm white false membrane, closely adherent to the mucous membrane. In the upper part of the trachea was a thin layer of false membrane; below this the trachea was almost perfectly free, its surface reddened, thickened, and superficially ulcerated. In the right bronchial tube there was an enormous growth of membrane completely filling the tube, and traceable some distance into

its divisions. In the left bronchus was a smaller quantity of membrane not occluding completely its lumen. The left lung was somewhat congested; the right lung contained numerous patches of collapsed tissue, and was in other parts distended with *interlobular* emphysema. This emphysema was most marked at the free edges and surface of the lung, but was pretty generally distributed throughout its substance. There were no distention of the air-cells, nor was there any emphysematous condition of the other lung, nor of the tissues of the anterior mediastinum or neck. The cervical lymphatic glands were enlarged and softened. At the bifurcation of the trachea was a mass of calcified glands. Other organs appeared normal.

There were cases of diphtheria in the neighborhood of the patient's residence, so that infection is easily accounted for. A rather curious fact in his family history is that three of his brothers and sisters have died of throat troubles: one of throat complications in scarlatina, another of croup, and a third of spasm of the glottis.

April 10, 1884.

---

11. *The pathology of broncho-pneumonia.*

Read by Dr. Francis Delafield.

I shall offer for your consideration, this evening, some observations on the subject of broncho-pneumonia. I venture to do this, for the reason that I believe that this particular lesion suffers from the effects of tradition, from having been called catarrhal pneumonia, and from its relations to pulmonary phthisis. It is also doubtful whether the profession appreciate what a common lesion it is.

I do not mean that the real lesions and symptoms of the disease have not been described. They have been described by different observers; but their descriptions have been, for the most part, fragmentary, and have failed to give a picture of the disease.

The current notions concerning the disease have remained somewhat obscure and indefinite. The prevailing ideas concerning broncho-pneumonia may be stated as follows:

That the terms broncho-pneumonia, lobular pneumonia, catarrhal pneumonia, and capillary bronchitis may all be used to designate the same lesion—although it is customary to use the words broncho-pneumonia and lobular pneumonia when the disease occurs in children;

capillary bronchitis when it occurs in adults; and catarrhal pneumonia when it is believed to be a form of phthisis.

That the inflammation begins in the bronchi, extends to the small and capillary tubes, and then to the groups of air vesicles which belong to these bronchi, and that for this reason the hepatization assumes a lobular form.

That obstruction of the bronchi with inflammatory products frequently produces areas of atelectasis.

That the catarrh may become chronic, the products of inflammation in the air vesicles undergo cheesy degeneration, interstitial changes be developed in the framework of the lung and so a form of pulmonary phthisis be produced.

This, I think, is a fair enough example of the ordinary accounts of broncho-pneumonia—accounts which fail to bring out the essential features of the disease.

Let us, then, turn to the conditions themselves—to the clinical symptoms and the lesions of broncho-pneumonia as we all can see them for ourselves.

To approach the subject properly, we must consider the symptoms and lesions of acute bronchitis, as well as those of broncho-pneumonia.

First, then, of *acute catarrhal bronchitis.* This is a disease of very common occurrence, especially in children, but one which seldom proves fatal. Our knowledge of its lesions is derived from exceptionally severe cases, from cases which are complicated by other diseases, and from the symptoms which we observe during life.

The inflammation involves regularly the trachea and the larger bronchi, less frequently the smaller bronchi also. As a rule, the bronchi in both lungs are equally affected.

The first change seems to consist in a congestion and swelling of the mucous membrane of the bronchi with an arrest of the functions of their mucous glands. This is attended with a pain over the chest, a feeling of oppression, rapid or asthmatic breathing, and a dry cough.

Fever and prostration are present in a degree corresponding to the extent and severity of the inflammation and to the age of the patient.

After this the mucous glands resume their functions with increased activity, the congestion and swelling diminish, there is a more rapid desquamation of the superficial epithelial cells, and increased growth of the deeper epithelial cells, and a moderate emigration of white blood-cells. Sometimes the red blood-cells also escape from the vessels.

The patient now has less pain and oppression, the cough is accompanied with an expectoration of mucus, mixed with epithelium, pus, and

sometimes blood. After death the only lesions visible are the increased quantity of mucus, the growth of new epithelium, a few pus-cells infiltrating the stroma of the mucous membrane, and sometimes a general congestion. If the smaller bronchi are involved, they contain pus-cells.

In a moderate number of cases, especially in very young children, certain accessory lesions are added. There may be a general congestion of the parenchyma of the lung, and even a filling of some of the air vesicles with inflammatory products. Still further, the filling of the small bronchi may lead to collapse of the groups of air vesicles to which they lead, and thus are produced areas of atelectasis, which may be further changed by inflammatory processes.

In acute catarrhal bronchitis, then, the inflammation involves regularly only the mucous membrane of the bronchi; and in this mucous membrane the only changes are: congestion, swelling, changes in the epithelial cells and in the functions of the mucous glands.

As complicating conditions, we may find atelectasis, congestion of the parenchyma, and areas of diffuse pneumonia.

Now let us consider the lesions and symptoms of broncho-pneumonia.

This disease is of common occurrence in children as an idiopathic inflammation, and as a complication of measles, whooping-cough, scarlet fever, and diphtheria. In adults it occurs less frequently, but in them also it may be idiopathic, may complicate the infectious diseases, and may follow injuries of the brain and spinal cord. Constitutional syphilis also may give rise to broncho-pneumonia, and in pulmonary phthisis this same inflammation constitutes an important part of the lesions.

In children, while the inflammation always presents the same essential characters, yet there is considerable diversity, both in the symptoms and in the lesions, in different cases. Thus, in infants a few weeks old, often the only symptoms are rapid breathing, a febrile movement, prostration, and death.

In older children there are well-marked constitutional disturbances—fever, prostration, and cerebral symptoms; in some cases the cerebral symptoms being excessively developed. The breathing is rapid. There may be cough. The physical signs are those of bronchitis alone, or of bronchitis with consolidation of the lung. If there is consolidation, it is developed slowly, and disappears slowly. Not infrequently, successive portions of the lung become consolidated. The disease terminates in the death of the patient, in recovery, or it assumes a chronic character. This disposition of the broncho-pneumonia to become chronic is one of its characteristic features, a feature in which it differs from acute bron-

chitis and lobar pneumonia. The cases vary, however, as to the degree in which the disposition is carried out.

In some children the disease after running its regular course of one or two weeks subsides, the constitutional symptoms are less marked, the child seems better in every way. But yet the physical signs of consolidation continue, there is still a slight rise of temperature and convalescence does not fairly begin. In this condition the child may remain for a number of weeks and then get entirely well, except that the percussion-note and the breathing remain somewhat changed.

In many such cases as these the recovery is permanent and the child has no further trouble. But in other cases, after the lapse of several months, the child is attacked with acute general tuberculosis. Thus it is not uncommon in children's asylums for an epidemic of measles complicated with broncho-pneumonia to be followed after the lapse of a year by an epidemic of acute tuberculosis.

In other children the course of the disease is more protracted. The physical signs of consolidation continue, there is a febrile movement, the child has no appetite, it gradually emaciates and dies at the end of several months. These cases resemble pulmonary phthisis in their symptoms, but they are really only examples of a broncho-pneumonia which has become chronic.

In still other children the physical signs and the constitutional disturbances continue, but the child does not succumb to the disease. It continues to live with the evidences of a chronic bronchitis, which go on year after year. So the child may grow up to adult life, sometimes better, sometimes worse, never entirely well. Cough, expectoration, dyspnœa, occasional fever harass the patient at intervals. The lung becomes more and more solid, the bronchi more dilated, the pleura thicker, and the affected side of the chest more retracted.

In the cases of acute broncho-pneumonia which die within from two days to three weeks, there is some variety in *the post-mortem appearances.*

The lungs may be large and well aërated, but on section the cut ends of the medium-sized and smaller bronchi are unusually prominent and thick, and around them are little zones of hepatization of red, or gray, or white color. This appearance of the lung may be further modified by a cylindrical dilatation of the thickened bronchi.

In other cases the lungs are denser and more congested, and a larger or smaller portion of them is consolidated. The consolidated portions are unaërated, dense, and smooth, of red color, or pinkish-gray, or dark red. Or the color may be mottled—small, rounded, gray or whitish areas surrounded by red hepatization.

The distribution and extent of the consolidation also vary. The hepatized areas may be small, encircle the bronchi, and situated at some distance from each other. Or they may in some one lobe or part of a lobe be close together, and between them is a more diffuse hepatization, so that this part of the lung may be completely solid.

The appearance of the consolidated lung may be further changed by a cylindrical dilatation of the bronchi.

In still other cases the consolidated portions of lung are of some size and of somewhat regular shape, as if they were portions of lung corresponding to bronchi. These portions are dense, unaërated, of a dark red color, and somewhat shrunken.

If the inflammation has become chronic, then over one lobe or part of a lobe the pleura is thickened, bands of fibrous tissue run into the substance of the lung, and the lung tissue is dense, hard, and unaërated.

When we examine these lungs more minutely, we notice first some peculiarities which belong to them, because they are the lungs of children and not of adults. The bronchi and the connective-tissue framework of the lungs occupy a larger relative space than they do in the lungs of adults; and in any inflammation of the lungs they are apt to take a more prominent share. The air vesicles are small and products of inflammation which have been formed within them are absorbed slowly and with difficulty. The walls of the vesicles are lined with a nearly continuous layer of epithelial cells. When the vesicles are inflamed there is a greater production of new epithelium and a less of fibrin than in adult lungs. The small size of the air vesicles renders a simple congestion and dilatation of the capillary vessels within their walls a more serious condition than it is in adults. The bronchial glands are more regularly and intensely inflamed. These peculiarities of the child's lungs seem to account for its liability to certain forms of inflammation.

The same exciting causes apparently produce in a child under five years of age broncho-pneumonia; in a person between the age of five and fifteen, broncho-pneumonia, or lobar pneumonia; in an adult, lobar pneumonia.

Now let us consider more in detail the lesions of broncho-pneumonia in children.

The trachea and large bronchi are congested and coated with mucus as in acute bronchitis; but in the smaller, and to a less extent in the capillary bronchi, the changes are of a different character. In these small bronchi the entire thickness of their walls is infiltrated with cells—partly new connective-tissue cells, partly pus cells. This change may affect the small bronchi equally in all parts of the lungs, or it may be

confined to those situated in one lobe or part of a lobe. Around every bronchus, of which the walls are infiltrated with cells in this way, is a zone, either of intense congestion or of pneumonia, the inflammation extending directly outward from the bronchus to the surrounding vesicles.

In the zones of peri-bronchitic pneumonia, the walls of the air vesicles are infiltrated with cells in the same way as are those of the bronchi. The cavities of the vesicles are filled with pus and epithelium, or with an organized tissue composed of a basement substance and cells.

These constitute the essential features of the lesion—a bronchitis which involves the *walls* of the bronchi, and a pneumonia which involves the vesicles *surrounding* the bronchi, and which produces changes in the *walls* of the vesicles as well as in their cavities, while the inflammatory products within the cavities of the vesicles are not only pus and fibrin, but also organized tissue.

To these essential lesions are often added other accessory changes. The bronchi, of which the walls are infiltrated with cells, may be dilated. Between the zones of peri-bronchitic pneumonia the lung is congested, and there may be areas of diffuse red hepatization, which do not, however, correspond to bronchi. There is often a layer of fibrin on the pulmonary pleura. There may be areas of atelectasis corresponding to obstructed bronchi.

The bronchial glands are swollen, and the seat either of simple or of tubercular inflammation.

When the broncho-pneumonia passes into the chronic condition, the inflammation usually persists only in part of a lobe, or a single lobe, while the rest of the lung returns to a normal condition. In that portion of the lung in which the inflammation persists, we find the small bronchi with their thickened walls and their zones of peri-bronchitic pneumonia. The number of bronchi involved may be moderate, and then a section of the lung will look as if it were studded with fibrous nodules. Or most of the bronchi may be involved, the zones of peri-bronchitic pneumonia are close together, and the entire lung tissue is dense and solid. In either case the bronchi may be dilated and the pulmonary pleura thickened. As the inflammation goes on, its interstitial character becomes more and more marked, until the affected portion of lung becomes converted into a mass of fibrous tissue, in which the bronchi still remain, while the air vesicles are obliterated. The bloodvessels, however, are, for the most part, not obliterated, so that the lung does not become necrotic or degenerated. Still occasionally areas of cheesy degeneration exist.

These are the characteristic features, then, of the broncho-pneumonia of children.

In adults broncho-pneumonia occurs in one of four forms: As an idiopathic inflammation of acute and severe type; as a subacute inflammation; as a complication of the infectious diseases, and of lesions of the brain and spinal cord; as one of the lesions of phthisis.

1. *The acute, idiopathic broncho-pneumonia of adults.*—The invasion of this disease is acute and severe. The patients have rigors; pains in the head, back, and chest; vomiting and marked prostration. The temperature runs between 102° and 105°; the pulse is rapid; the breathing is rapid and unsatisfactory. There is cough, at first dry, later accompanied by profuse muco-purulent and bloody expectoration. There are venous congestion of the skin, albumen in the urine, and cerebral symptoms. When we examine the chest we find the percussion note normal, or exaggerated, or dull. There are crepitant, subcrepitant, and coarse râles with sibilant and sonorous breathing.

The cases usually terminate fatally in about seven days. After death we find both lungs large, heavy, and congested. There is fibrin on the pulmonary pleura. The trachea and large bronchi are congested and coated with mucus. The smaller bronchi contain pus, their walls are thickened and infiltrated with cells, and around them are zones of air vesicles with their bloodvessels gorged with blood, and in their cavities epithelium, pus, and fibrin.

2. *The subacute broncho-pneumonia of adults.*—This is a rare disease. It has a clinical history much resembling that of acute phthisis. The patients are attacked with prostration, fever, cough, and muco-purulent expectoration, dyspnœa, pain in the chest, coarse râles all over the chest, with dulness over the consolidated portion of the lung. These symptoms continue, the patients lose flesh and strength, and die at the end of several weeks.

After death we find fibrin on the pulmonary pleura. The larger bronchi are congested and coated with mucus. There is an irregular, diffuse red hepatization mottled with small white nodules, from the size of a pin's head to that of a pea. In the diffuse red hepatization the air vesicles are filled with pus, epithelium, and fibrin. The white nodules correspond to sections of bronchi with zones of peri-bronchitic pneumonia. These bronchi are of small size, they contain pus, their walls are thickened and infiltrated with cells, and they may be dilated.

In the peri-bronchitic zones of pneumonia the walls of the vessels are thickened and infiltrated with cells, but the bloodvessels remain pervious and can be injected. The cavities of the vesicles are filled not with pus

and fibrin alone, but also with a basement substance of homogeneous or finely fibrillated character, in which are embedded polygonal, round, and fusiform cells.

3. *The complicating broncho-pneumonia of adults.*—It is not uncommon for some of the infectious diseases, and some of the lesions of the brain and spinal cord to be accompanied by the development of this form of inflammation of the lung.

In typhoid fever we sometimes find a broncho-pneumonia exactly resembling the same lesion as it ordinarily occurs in children.

In pyæmia the inflammation is of the same kind, but is apt to be less extensive, involving only part of one or both lungs.

With lesions of the brain and spinal cord the changes are the same as with pyæmia.

4. *With phthisis*, both acute and chronic, broncho-pneumonia often forms an important part of the morbid changes in the lungs, but yet it is never the primary or the only lesion. It is only one of a number of pathological changes which go to make up the complex whole of pulmonary phthisis.

From what has been said, then, I would draw the following conclusions:

There is a form of inflammation of the lung which may properly be called broncho-pneumonia.

In children it is the most frequent form of pneumonia; in adults it is less common.

It differs from bronchitis and from lobar pneumonia in that the inflammation effects changes in the *walls* of the bronchi and of the air vesicles, and this peculiar interstitial character of the process exists from the very outset.

The inflammation extends from the bronchi, not to the group of air vesicles into which they lead, but directly outward to the vesicles which surround the inflamed bronchi, and in these vesicles the walls are changed.

The interstitial character of the inflammation is its most important feature. It accounts for the severity of the symptoms, the frequent long continuance of the consolidation, the dilatation of the bronchi, and for the tendency of the broncho-pneumonia to assume a chronic character.

The complicating tubercular inflammation of the bronchial glands may give rise later to general tuberculosis.

Broncho-pneumonia is not a form of phthisis; it is doubtful if it is ever directly followed by phthisis; but it constitutes a part, and often an important one, of the lesions which constitute phthisis.

I have endeavored to describe, though in a somewhat incomplete way, the characteristic symptoms and lesions of an ordinary disease. I am well aware that I have described conditions which are familiar, and that nothing which I have said has not often been said before.

But the very common occurrence of this form of inflammation of the lung renders it all the more important. The varying character of the lesions has confused their essential and their accidental characters, and I think it is worthy of consideration whether the views which I have advanced concerning the pathology of the disease, are not the true ones, namely, that the inflammation is essentially and from the outset an interstitial one, more or less complicated by other conditions.

Dr. Pepper said that he had listened with very unusual interest to the paper of Dr. Delafield, in which he had so distinctly and concisely set forth his views on this very common disease.

He thought all who had listened to Dr. Delafield would agree with him in congratulating the author upon the clearness and force with which he had described a condition which had hitherto often been confused by prolix description, and by want of definiteness in separating different anatomical conditions. In regard to the term "broncho-pneumonia," which Dr. Delafield prefers, he has proved by his anatomical studies of the infiltration of the bronchial walls and of the surrounding parenchyma, that this term is strictly applicable to the cases upon which this paper is based.

Dr. Pepper stated, however, that, though chiefly from a clinical standpoint, he was inclined to prefer the term catarrhal pneumonia, as probably including the form described by Dr. Delafield, as well as certain other forms which seem to him to be necessarily included in a complete picture of the disease.

For instance, there are many cases in adults which begin with rigor, followed by high fever, with temperature of 102¼° to 104° F., with cough hard and dry at first, and later with muco-purulent expectoration, with no very definite physical signs; careful examination will show local impairment of resonance, coarse crackling râles on deep inspiration, and weak vesicular murmur. This condition may be limited to the apex or to the neighborhood of the root of one lung, or may occur elsewhere. The cases have a duration of from eight to twelve days, and terminate by lysis with resolution, though not rarely some cough remains, and the lung is sensitive and prone to recurring attacks, which in subjects predisposed to phthisis may induce that disease.

It seemed to him difficult to regard these cases as anything else than mild catarrhal pneumonia; for this type of pneumonia agrees with other

catarrhal affections in the wide range of severity presented by different cases. On the other hand, there are cases much more common in children, in which disease extends from the bronchial tubes into the lobules to which they lead.

The commonly accepted opinion that the lining of the alveoli and air vesicles is susceptible to catarrhal inflammation, appeared to him well established. In such cases the disease may extend outward to the peribronchial tissue, as emphasized by Dr. Delafield, and lead to secondary interstitial changes, and also in consequence of obstruction of the bronchi, atelectasis occurs; the aspiration of irritating bronchial products fills some of the alveoli, or finally they become impacted with the results of catarrhal inflammation of their walls. Subsequently, caseation with softening may give rise to small abscesses, with breaking down of the walls of the air vesicles or with perforation of the pleura, or inspissation may occur with reabsorption of infectious material, with the development of general tuberculosis.

It did not seem necessary to dwell upon the cases in which atelectasis occurred as a primary condition, with the subsequent development of pneumonic centres.

It seemed to him impossible to consider catarrhal pneumonia without taking the comprehensive view which would include all the varieties above indicated; though the term "broncho-pneumonia," as used by Dr. Delafield, might be most appropriate to the special conditions described by him.

Allusion was made to the very interesting physical signs attending the course of atelectasis in the course of catarrhal pneumonia of children or of adults, where considerable areas of the lung, or even an entire lung, might pass into this state, to be followed before long by the reestablishment of respiration and the disappearance of the physical signs. Difficult questions of differential diagnosis may present themselves, requiring critical examination. From an allusion made by Dr. Delafield, it appeared that he regarded lobar pneumonia as being, like broncho-pneumonia, induced by the ordinary causes of idiopathic inflammation. The argument in favor of all lobar pneumonias being a specific constitutional disease, or dependent upon a special microbe, did not appear to Dr. Pepper to be conclusive, and he was glad to know, from the remarks of Dr. Delafield, that he holds the same view.

Dr. Bruen said he rose to call attention to the observations of Hamilton, of Aberdeen, in reference to the peculiar basement membrane of the bronchial tubes, which determines the chronicity of bronchitis, and probably the interstitial changes in chronic broncho-pneumonia. Hamil-

ton, in speaking of the denseness of this basement membrane, gives it the importance of a fascia, which determines the direction in which the inflammatory products of bronchitis shall be absorbed, viz., by the lymphatics, rather than by free exudation into the bronchial lumen. The interlobular connective tissues are permeated with fibrous bands, which radiate from the fibrous coat of the bronchi toward the pleural surface. Dr. Bruen thought that if careful study of the lymphatics were made, the absorbed products of an acute or a subacute inflammation could be traced throughout the lung, finally leading to enlargement of the bronchial glands.

The importance of the basement membrane is further illustrated by the phenomena of pneumonikoniosis. Immediate absorption from the bronchial tubes does not occur; although the tubes are always exposed to carbonaceous matter as evinced by the blackened sputa, yet the tubes are unpigmented, the carbonaceous or organic dust being carried down into the alveoli, whence it is absorbed, and the whole parenchyma of the lungs and the bronchial glands are blackened, but always strictly in the course of the lymphatics.

In children of a strumous habit, forms of bronchitis of an obscure nature often occur. Congested areas near the root of the lung are recognizable—abundant mucous râles and frequently laryngeal spasm at intervals is an important symptom. These symptoms are often referable to enlargement of the bronchial glands, and the nervous symptoms are due to irritation of the pneumogastric nerves.

Dr. J. C. Wilson asked whether Dr. Delafield designed to describe one variety of a group of affections to which the terms broncho-pneumonia, catarrhal pneumonia, desquamative pneumonia, etc., are somewhat vaguely and interchangeably applied, or to include the whole group in his account, and under the designation of broncho-pneumonia. If Dr. Wilson had understood the paper aright, he thought it certainly had referred to an especial variety of the affection in question, for there are encountered cases which differ both clinically and anatomically from the disease described by Dr. Delafield, and in which the lesions spread not only in a direction internal from the affected bronchial tubes to the peri-bronchial structures, but also in the direction of the long axis of the tubes to involve the terminal (subpleural) vesicles, and this, according to widely accepted views, often without antecedent atelectasis.

Dr. Carpenter said that he had very little, indeed, to give of value in a pathological discussion, but, at the same time, would say that after thirty years' experience he had arrived at certain conclusions, not perhaps new, but which had been gathered in one set of cases, viz., anthra-

cosis. They are a very striking set of cases. They all originate in a bronchitis which differs from the ordinary form of that disorder in one very striking symptom, viz., great oppression of breathing. This oppression is far greater than can be accounted for by ordinary bronchial inflammation. It depends on interstitial disease or peri-bronchitis. A true broncho-pneumonia is set up, the cause being a special one, viz., inhalation of coal-dust. In these cases so great obstruction to the circulation is caused by the interstitial exudation that the circulation is very seriously embarrassed. The heart suffers—dilatation, or hypertrophy with dilatation, is produced, and a form of dyspnœa, known as miners' asthma, occurs. These cases are essentially chronic ones. He had only the day before seen a patient die with this disease who had been under his care for several years, and in whom no lesions but those of peri-bronchitis could be detected.

Many of these cases, however, in a chronic progress, do develop all the symptoms of phthisis. Slow alterations of structure occur, cavities form, and all the pathological conditions of the so-called fibroid phthisis are found on post-mortem examination. He, therefore, claimed that these cases are entitled to constitute a special form of broncho-pneumonia. He agreed with Dr. Pepper that acute or subacute broncho-pneumonia left sensitive areas, leading often to subsequent phthisis. In his observation, fibroid phthisis is not a true tuberculosis, but a chronic degeneration of lung-tissue, due to a preëxisting broncho-pneumonia, such as he had observed in anthracosis.

Dr. Osler said that his experience in many points tallied with that of Prof. Delafield. In the broncho-pneumonia of adults the pneumonic process, he believed, most usually spreads from the bronchi. He referred also to those cases of broncho-pneumonia which followed brain injury or disease affecting the pneumogastric centres. In such cases the disease is deeply seated, and we find that the morbid process often surrounds the bronchi, but does not involve the terminal alveoli. The reverse is true in the case of children, in whom the disease is more peripheral, is nearer, and may be just beneath, the pleura. He was glad that Dr. Carpenter had raised the point as to anthracosis. Dr. Osler had been able to examine several cases of this affection in its very earliest stages, and could testify that it begins in the bronchi and thence extends to the peribronchial tissues. It is primarily then a broncho-pneumonia, and in every case he had found small disseminated black lumps resulting from localized broncho-pneumonia, which, by their fusion and extension, produce a form of fibroid phthisis.

Dr. Tyson had little to add to what had already been said. He had,

however, first to express his gratification at the simple clearness with which Dr. Delafield had presented the question. Dr. Tyson had been very much impressed with the diversity of nomenclature of the disease under consideration, and it would be useful if we could agree upon some common term. For a long time desquamative pneumonia had seemed to him to be the best term, but from a study of the pathological histology, he thought the term peri-bronchial pneumonia more suitable. If now the adjective desquamative be added, we have a term which will be still more comprehensive and exact. Dr. Tyson thought that our understanding of the enormous peribronchial cellular infiltration would be much simplified if we lose sight altogether of the idea that there is essentially any form of inflammation except interstitial inflammation. He had come to the conclusion that there is no such thing as catarrhal or parenchymatous inflammation, the phenomena usually considered characteristic of these being secondary. The wandering out and massing of leucocytes is the one essential factor of the inflammatory process. He would like to ask Dr. Delafield where he would draw the line between this process and tubercular phthisis. He presumed that Dr. Delafield agreed with all other observers in admitting that broncho-pneumonia does sometimes terminate in tubercular phthisis, and when this occurs it is often difficult to say where the broncho-pneumonia ends and where the phthisis begins, although the extremes may be easy of recognition.

Dr. Formad said he would like to ask the lecturer's method of distinguishing broncho-pneumonia in its *chronic* form from *tubercular* broncho-pneumonia. Like Dr. Tyson, he felt that he was unable to draw a line of distinction between the two affections. Indeed, Dr. Formad was unaware of a non-tubercular form of broncho-pneumonia in man until he saw Dr. Delafield's excellent records and representations of this lesion.

Dr. Formad fully recognized *acute* broncho-pneumonia as an independent affection, although he believed he had observed this lesion post-mortem only in dogs, induced artificially by means of forced inhalations of a spray containing irritating particles. Dogs with such artificial broncho-pneumonia (even if tuberculous sputum was resorted to to induce it), Dr. Formad had observed, always recover within a couple of months; but if the dogs were killed before the end of the first month after the operation, the post-mortem examination showed invariably an acute broncho-pneumonia not distinguishable from that described by Dr. Delafield as occurring in man. Throughout the lung substance are seen small nodes of irregular outline, in size resembling tubercles.

Under the microscope these nodules are shown to consist of mere unorganized collections of cells, often in a state of retrograde change and mixed with mucus and débris; this exudate being limited to the lumina of the bronchioles and their pertaining groups of air vesicles which it fills. On section these artificial boundaries give rise to the appearance of nodes. Very often epithelial cells and mucus from the bronchi have been seen intermingled with the purulent contents within the air vesicles; this suggests that the exudate contained in the latter may have been partly aspired from the bronchi (during forced breathing) and was lodged in the air vesicles as foreign material.

Acute broncho-pneumonia in man appears to be a lesion perfectly analogous to the one described above in dogs.

Dr. Delafield, in closing the debate, said that all the speakers had brought out what was one of the most difficult points concerning broncho-pneumonia, namely, its limitations. Strictly speaking, every pneumonia is a broncho-pneumonia, and the application of the term to a certain group of cases is, of course, arbitrary. He believed, however, that the name is most properly employed to designate the group of cases which he had described.

In anthracosis there is a chronic bronchitis and also a chronic pneumonia, but yet the lesion is not, properly speaking, a broncho-pneumonia.

He did not believe that the inflammation travels directly from the bronchi to the air vesicles into which they entered, but that the appearances which simulate this are due to atelectasis.

He thought the term catarrhal pneumonia a very bad one, and that the air vesicles are structures entirely different from mucous membranes.

He did not believe that broncho-pneumonia is a form of phthisis or leads to phthisis, but that phthisis has its own special anatomy from the very beginning. *October* 23, 1884.

---

12. *Three cases of tuberculosis.*

Exhibited by Dr. E. T. Bruen.

The following cases I desire to submit to the Society, because they have seemed to me valuable, as showing grounds for the belief in the non-specific inflammatory character of some tubercular lesions:

Case I.—Cassie C., æt. 18 years, was admitted to the medical wards of the Philadelphia Hospital, June, 1884. She was the type of a strong,

healthy Irish girl, and, until a short time previous to her admission, had never been ill in her life. When admitted she was suffering from secondary syphilis and gonorrhœa; the primary syphilitic lesion having occurred three months previous. She was put on the usual specific treatment, and seemed to be doing very well until about the 20th of July, when she began to complain of pain in the right inguinal region, and a vaginal examination showed a purulent discharge exuding from the mouth of the uterus. Upon dilatation of the os with sponge-tents an abundant purulent discharge followed; but after transitory improvement, an abscess formed in the cellular tissue of the vaginal wall, which finally ruptured, and, after discharging freely, closed. After a period, during which there seemed gradual improvement, she again complained of abdominal pain, and was transferred to the medical wards in October; from which time her health progressively declined, great emaciation occurred, and she died November 26th.

Autopsy.—Thorax, Lungs: Pleuræ were normal, presenting neither effusion nor adhesions. Lungs were extensively hepatized and œdematous, presenting marked signs of croupous pneumonia.

Heart: Pericardium was normal. The heart itself showed no valvular lesions. The cardiac tissue, however, was pale and atrophied. There was a large ante-mortem clot in both right and left sides of the heart.

Abdomen: There was no peritoneal effusion. The omentum, as well as the whole peritoneal surface, was studded with minute nodules of a tuberculous nature. There were adhesions between all the viscera. Catarrhal changes were present throughout the intestines.

Liver: There was extensive perihepatitis: the connective tissue was everywhere covered with minute tuberculous nodules. The parenchyma of the liver was granular, and rather anæmic, but no tubercles were visible microscopically.

Spleen: This organ was slightly enlarged, but of normal consistence. There was slight perisplenitis, and numerous tuberculous nodes throughout the whole splenic substance.

Kidneys were slightly above normal size; their surface was smooth, but, as well as the parenchyma, presented whitish-yellow spots, alternating with congested points. There were also lesions indicating parenchymatous nephritis.

Pelvis: There was a prominent abscess in the psoas muscle of the right side. The opening of the abscess revealed a large amount of pus. There were lesions of purulent endometritis, as well as vaginitis.

The *brain*, with the exception of an excess of fluid in the fourth ventricle, was normal.

Cause of death, tubercular peritonitis.

Case II.—A male, æt. 40 years; admitted to the medical wards of the Philadelphia Hospital suffering with chronic parenchymatous nephritis. This disease was complicated by pleural effusion on the left side. Under treatment this effusion was absorbed, but within two months he developed symptoms of peritonitis, and died of this complication.

Autopsy.—Kidneys revealed the changes of chronic parenchymatous nephritis.

Lungs: Structure normal.

The visceral and costal pleura on left side adherent.

Examination of the abdominal cavity reduplicated the appearance of the previously related case in so far as the peritoneal surfaces were concerned, and also the condition of the spleen and intestines.

The inferior surface of the diaphragm was more thickly studded than elsewhere, with minute nodules of tuberculous nature.

The suggestion of peritoneal infection through transferrence of material from the remains of the pleural inflammation seemed the most natural inference, especially when we recollect the free inosculation of the peritoneal and diaphragmatic lymphatic system with the pleural lymphatic channels.

Case III.—Edward C., æt. 50 years. *Autopsy, external appearances.*—Middle-sized, much emaciated man. Subcutaneous adipose tissue wasted.

Thorax: The lungs were somewhat swollen from hypostatic congestion. On section both lungs showed a pronounced tubercular bronchopneumonia. The left lobe was riddled throughout with tubercles, and pneumonic racemose-shaped foci, but no cheesy foci or cavities. The right lung was similarly affected but in a higher degree, and showed a cavity in the upper lobe near apex which communicated with several smaller cavities around it. There was also a scar at the apex of the right lung indicating an old healed cavity. The bronchial glands were all enlarged and somewhat cheesy.

Heart was comparatively small in dimensions. Pericardium normal. The heart muscles, valves, and orifices normal. Large ante-mortem clot on right side. Mediastinal glands enlarged, and some of them calcified. In the group of mediastinal glands, and encapsulated in the connective tissue on the right side, was found a Minie-ball (rifle); no injury to the lung could be discovered, but the connective tissue in the mediastinum in this locality showed the scar tissue riddled by tubercles. Subsequent examination showed that the ball from the rifle (received twenty-two

years ago) had entered at a point one inch and a half within the right nipple, slightly above the mammary line, and must have passed through the right lung to reach the locality where found, although no scar could be discovered in the lung.

Abdomen: Peritoneum normal. The lymphatic glands somewhat enlarged.

The *liver* was of normal size, in second stage of fatty infiltration.

Kidneys and suprarenal bodies normal.

Spleen atrophied.

Rest of organs normal.

It is a reasonable hypothesis that the phthisis in this case was of traumatic origin.

Dr. Shakespeare said that no examination for the tubercle bacillus had been made. He thought, therefore, that none of the three cases as they stand could, with our present knowledge, be considered to be of such undoubted significance as to warrant the claim that they are representative of a class of tuberculosis in man without the presence of the tubercle bacillus. In the Minie-ball case, too much time had elapsed—viz., twenty years—in view of the fact that experimental investigation seems to show that only a short time—at the shortest two weeks—is required for the development of artificial or inoculated tuberculosis. He thought, therefore, that we were hardly justified by such testimony as was presented by these three cases, in assuming in the face of the positive evidence of experiments, that there was a tuberculosis without bacilli. With regard to one of the abdominal cases, it may be remarked that there are cases on record where abdominal serous tuberculosis seems to have arisen by the passage of the virus along the Fallopian tubes.

Dr. Formad said that he plainly recalled the Minie-ball case, and that examinations of the sputum during life, and of scrapings of the lung, post-mortem, failed to reveal bacilli, at least any which gave a typical reaction.

Dr. Bruen said that no one is in a position to affirm the positive etiology of tuberculosis; but the two cases of abdominal tuberculosis might inferentially be considered instances of non-specific inflammatory tubercular disease rather than specific.

In conclusion, it appeared to the writer that the mass of observations already made and constantly increasing, demonstrate beyond question the very constant presence of a peculiar organism in tuberculous processes—yet, at the same time, there are certain nodular and cheesy processes undoubtedly tuberculous in which the organism has not been found. Probably some of these failures are traceable to imperfec-

tions in the method of search for it, but other cases are inexplicable on this ground. It seems probable that certain local inflammations, or irritants, can give rise to tubercular and cheesy tubercular non-specific (in the sense of organisms present) products quite local in character. When these lesions are diffused throughout the body—their diffusion is evidently governed by lymphatic circulation which may permit transferrence of irritant material from the site of the primary inflammation to a new situation.

The bacterium, on the contrary, is capable of developing a tubercular and specific process over the entire system, and researches seem to warrant us in designating this process as a specific tuberculosis.

Thus considered, the bacillus tuberculosis becomes one of the causes of tubercular inflammation. The question of the frequency of its operation is still unsettled, but by its side is possible the non-specific (in sense of the presence and etiological relation of organism) inflammatory nodule which is subject to similar degenerative processes as the so-called specific nodule. Were this Society a clinical body, weighty clinical evidence, it seems to the writer, could be adduced to defend the above statements. *December* 11, 1884.

---

13. *Larynx, trachea, lungs, and heart from a case of anginose diphtheria.*

Exhibited by Dr. W. A. Edwards.

This case occurred in the practice of Dr. William M. Powell, of this city, at whose request I saw the little patient and for whom I made the post-mortem examination.

Lizzie P., æt. 2 years, of a strumous diathesis, was first seen by Dr. Powell on February 2, 1885, when she appeared to be suffering from catarrhal fever, but at his next visit, two days later, a diphtheritic membrane was easily recognizable over the uvula, tonsils, and half arches.

The child grew worse, the membrane increasing, the cervical and post-cervical glands enlarging, pulse running high, hyperpyrexia, and the case rapidly assumed a malignant aspect. On the 8th, after consultation, the plan of treatment was slightly changed, apparently to the child's benefit as she improved until about 8 o'clock in the evening of the 11th, when her respiration was noticed to become shallow, extremities cold, pulse high and thready, increasing apnœa, and sudden death at 9.30 P.M.

Post-mortem examination, fourteen hours after death.—Female child, fairly well nourished; in the right eye is seen a corneal opacity, probably the cicatrix following phlyctenular keratitis.

The *larynx*, unfortunately, was somewhat mutilated in removal as an incision in the neck was not permitted. Some œdema may be noted and in the recent state areas of hyperæmia were observed, probably the seat of membrane.

The *trachea* presents these areas much more plainly.

The glands at the root of the lungs and along the trachea are much enlarged and indurated; one is lodged just at the bifurcation of the trachea and probably had some causal relation, through pressure, to the emphysematous condition of the lungs.

Thorax, lungs: The pulmonary and costal pleura are adherent, as is also the diaphragmatic; the lobes of the lungs are bound together by slight adhesions. In numerous spots over the lung tissue are to be seen small areas of emphysematous dilatation. Cross-sections of the bronchioles show exuding muco-purulent matter well aërated. No effusion is to be seen in the pleural cavities.

The *heart* appears to have undergone some dilatation of its right cavities, the valves are normal, the left side is firmly contracted, with normal valves. Contrary to our expectation, no clots were seen either in the heart, pulmonary artery, or aorta, with the exception of a very small one entangled in the chordæ tendineæ of the right ventricle. No effusion within the pericardium.

Liver normal. *Spleen* somewhat enlarged. Stomach contained a large quantity of undigested milk: over its surface are seen numerous centres of ecchymoses.

Kidneys and *brain* not examined.

The cause of death in this case becomes an interesting inquiry; the child was practically well of the diphtheria and was progressing nicely toward convalescence when suddenly signs of apnœa appeared deepening into death. As was noted above, the right auricle and ventricle appear to have undergone some dilatation. This, to my mind, was the cause of death in our patient's case, as *sudden and considerable dilatation of the cardiac cavities, more especially of the right heart*, may be remarked at the bedside, and in many febrile cases causes sudden death from heart failure.

February 14, 1885.

14. *An anomalous human lung, having four lobes on the right side.*

Exhibited by Dr. W. A. Edwards.

Mary O., Irish by birth, æt. 62 years, widow, mother of four children, came under my care just a year ago, suffering from slight ailments incidental to her period of life. The patient's vital powers were at a low ebb, and she finally succumbed to senile asthenia two and a half months after I first saw her. A post-mortem examination was made, not to verify the ante-mortem diagnosis, but in the routine line of duty; our work was rewarded by securing this extremely interesting and unique specimen. All the organs were destitute of marked pathological lesions, but upon opening the thorax an unusual condition of affairs was made apparent: the lungs were widely stretched apart, increasing the mediastinal space by several inches, thus exposing the heart and great vessels, and giving a better view of the accessory lobe.

The left lung did not deviate from the normal standard, but the right presented *four well-marked lobes.*

The upper lobe was normal, bearing the proper relative proportion to the remaining parenchyma; the middle lobe was somewhat decreased in size, as was also the lower, and between the two may be seen the anomalous fourth lobe, which was formed at the expense of the second and third lobes, together with an absolute increase of lung tissue, as the other lobes are not diminished enough to form the new lobe.

This supernumerary lobe was quite as long as a man's hand from the wrist to the tip of the second finger, measuring from six and a half to seven inches.

At its widest part it measured two and a quarter inches, tapering to a quarter of an inch, and finally to the thin border as in the other parts. Its tissue was perfectly normal and functionally active. Its histological structure was the same as the rest of the lung, and it apparently did its work equally as well.

It is almost needless to remark that no evidence of this condition was revealed ante-mortem, nothing had ever called attention to the lungs, and, of course, the diagnosis could not have been made even by the most expert and careful diagnostician.

In illustration of the rarity of this anomaly, I am able to cite the following authorities:

Prof. Joseph Leidy writes me, "I have never seen such a lung, nor do I remember having read of one." Prof. William Pepper "has never

PLATE I.

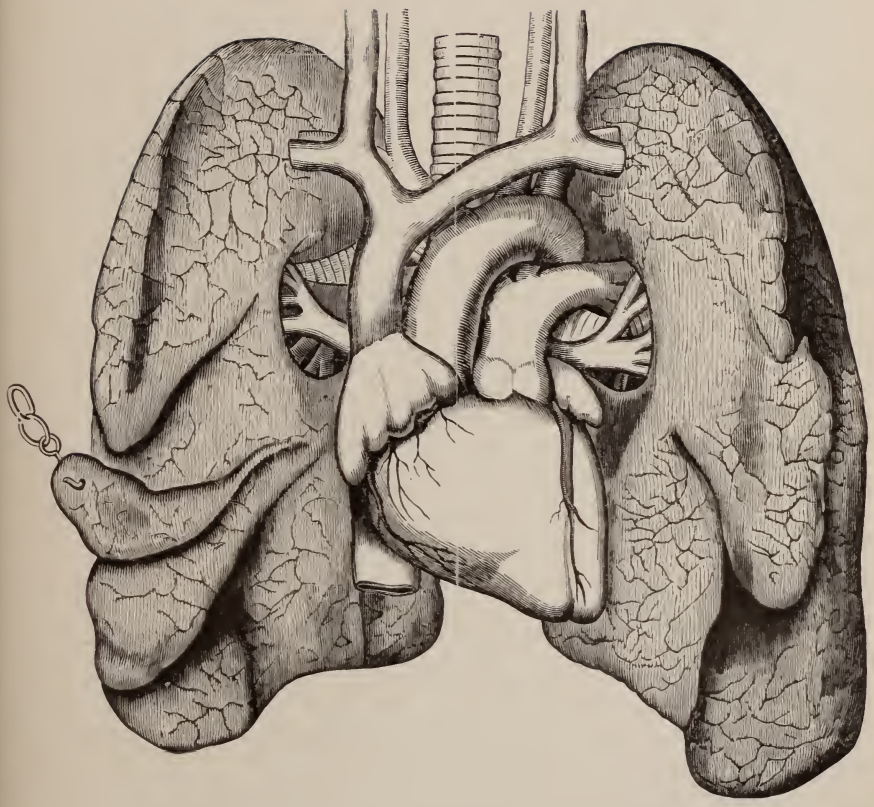

Illustrating Dr. Edwards' Case of Anomalous Lung;

Four Lobes on Right Side.

[*To face p.* 158.

seen such a case, and recalls no record of one." Prof. William Osler "cannot recollect a similar case occurring under my observation," but sends me a record of the following anomalies:

"Case I., in which the right middle lobe was only a notch, the lung having but two lobes on the right side.

"Case II. The upper lobe of the left lung was divided by a deep fissure extending internally nearly to the root. Anteriorly to within an inch and a half of the usual fissure. Another fissure was noted in the same lobe three inches from the apex."

It will thus be seen that the left lung in this case was made up of three lobes, the deviation from the normal standard being at the expense of the upper lobe entirely. Dr. H. F. Formad "has seen a lung presenting three lobes on each side, but never one as above described." Prof. J. M. Da Costa "has never seen a similar case." Dr. W. S. Forbes writes that "In a long experience with the cadaver I have never met such an anomaly."

A careful search through a number of anatomical works failed to reveal a like condition, with one or two exceptions; for example, in the magnificent work of Braune (*Topographisch Anatomischer Atlas*, Dr. Med. Wilh. Braune, Leipzig, 1875), where a number of thoracic abnormalities are depicted, a case like ours receives no mention. William Cowper (*Anatomy of the Human Body*, London, 1697, Table xxiv.) describes but two lobes to each lung, calling them the right and left anterior lobes, and the right and left posterior lobes. Weckel (*Handbuch der Path. Anat.*, Bd. i. S. 479) remarks that Rhodius states that Mollinetta (*Mantissa Anat. Obser. xi.*) once found in a very large man the lungs divided into four lobes like the ruminants. The *Anatomy* of Harrison Allen devotes more space to these anomalies than most other anatomical works, although even here it is but a few lines.

Dr. Collins ("On Accessory Lobes of the Human Lungs," by Edw. W. Collins, M.D., *Trans. Royal Irish Academy*, vol. xxv. part vii. p. 329, Dublin, April 13, 1874) records a threefold abnormality in the right lung, pleura, and vena azygos. Immediately above the posterior part of the root, in the angle between it and upper portion of the right lung, was to be seen an accessory lobe, somewhat pyriform in shape, with a broad peduncular attachment. Its measurements were four inches in length by two and a half in breadth at its widest part. Breadth of peduncle was one and a half inches. The lobe laid beside and upon the bodies of the five upper dorsal vertebræ in an accessory pleural pouch, which communicated with the general pleural cavity around the peduncle of the lobe. The pleural duplicate was continuous with the

costal portion of the pleura above and along its outer border; along its inner border with the mediastinal. Its lower border alone was free; the inner free margin contained the azygos vein: this vein had an anomalous distribution, the course of which it is not necessary to describe. The trachea was separated from the spinal column for a considerable space by the pleural pouch.

H. A. Wrisberg, in 1777, laid before the Royal Society of Göttingen an anomaly similar to the one above recorded. (*Cf.* "Observationes Anatomicæ de venâ azygâ duplici aliisque hujus venæ varietatibus," in *Novis Commentariis Soc. Reg. Scient.*, Göttingen, anno 1777, tom. viii. p. 14.) Bouchaud put on record another case before the Anatomical Society of Paris, in 1862.

Lately four instances of accessory lobes above the root of the right lung have been noted by Dr. Chiene, in Edinburgh, Prof. Cleland, in Galway, and Prof. Wenzell Gruber, in St. Petersburg.

Wrisberg's case is worthy of special note as being the only recorded instance of an accessory lobe of the left vena azygos. Prof. Cleland explains the fact of the accessory lobe appearing on the right side, which appears to be consonant with the development of the venous system as follows: Early in fœtal life from some such cause as a slight adhesion of the lung to thoracic wall, or, less probably, an undue curvature of the embryo, the azygos vein as it is drawn downward at a right angle to its original transverse direction by the descent of the heart, dragged down around it a fold of the pleura, thus deeply notching the lung instead of slipping behind it.

Comparative anatomists, says Collins, from the time of Cuvier, have shown that a fourth lobe upon the right side, which makes its first appearance in many of the quadrumana, is very constantly found in other mammals occupying a defined position, between the pericardium and diaphragm in one direction, and between the inferior vena cava and the spine in the other, a position due to the altered situation of the pericardium.

An accessory lobe of the right lung in man, lying below the root on the inner side, and bearing a tolerably strict homology to this so-called lobus impar, which has been regarded by some zoölogists as forming a distinctive difference between the lungs of quadrupeds and man, has been made the subject of a memoir by M. Pozzi (*Cf. Revue d'Anthropologie dirigée*, par P. Broca, 1872, p. 443), and was the *only case* on record in man, prior to my describing this *second case.*

A similarly situated accessory lobe upon the left side has been described in detail by Prof. Rektorzik, of Vienna (*Cf. Zeitschrift der K.*

K. Gesellschaft der Aerzte der Wien, 1861, No. 1). This accessory lobe was wholly isolated from the remainder of the lung, unexpanded, having no connection with the bronchus, though it contained collapsed alveoli, and bronchi lined with ciliated epithelium. It was from a girl who survived her birth only fourteen days.

In Prof. Wenzell Gruber's case, besides the accessory lobe of the vena azygos, the remainder of the right lung was divided into four lobes by a cruciform fissure.

Mr. Laurance Humphrey exhibited before the Cambridge Medical Society[1] an abnormal structure which he had removed from the body of a child a year old, who died of tubercular meningitis and acute general tuberculosis. It was lying in the left pleural cavity, in the vertebral groove between the base of the lung and the diaphragm, and was suspended by a thin pedicle of bloodvessels and connective tissue to the descending aorta, from which it received its blood supply. It had no connection whatever with the lung, neither was there any communication with or attachment to any part of the air-passage. It measured about two inches long by one broad; was flattened at the posterior surface, and rounded anteriorly, and had the appearance of a fœtal lung, but much harder. Sections under the microscope showed lung tissue containing bronchioles lined with columnar epithelium, and thick-walled unexpanded air vesicles, with a plentiful supply of bloodvessels; also large masses of caseating tubercle with well-marked giant cells.

H. Handford[2] records a case of a man, æt. 40 years, who died from chronic epilepsy. At the autopsy the following condition was revealed: Lying upon the pericardium and distinct from the rest of the lung about one inch and a half, was a lobe of lung-tissue one inch and a quarter long, three-quarters broad, and nearly one-half inch thick in the centre. It was attached to the anterior margin or the upper part of the lower lobe of the left lung by a double fold of pleura, in which were a few vessels. It was light in color, and not much pigmented. It contained plenty of air. No microscopic examination was made.

April 9, 1885.

[1] British Medical Journal, April 25, 1885, p. 842.

[2] Ibid., May 2, 1885, p. 926.

15. *The pneumonia-coccus of Friedländer* (*Micrococcus Pasteuri, Sternberg*).

Read by Dr. G. M. Sternberg.

In this paper I desire to call attention to the so-called pneumonia-coccus of Friedländer, which I shall take the liberty of naming *Micrococcus Pasteuri*. My right to name the micrococcus discovered by Friedländer in the exudate of croupous pneumonia must depend upon my ability to make good the claim which I here state, viz.: that the pneumonia-coccus of this author is, in fact, identical specifically with a micrococcus previously described by me, which is found in normal human saliva, and with that found by Pasteur in the blood of rabbits which had been injected with the saliva of a child who had died of hydrophobia in one of the Paris hospitals.[1]

In attaching to this micrococcus the name of the illustrious French chemist I have no desire to perpetuate the memory of the mistake he made in supposing for a time that it was the germ of hydrophobia. Having found that this was a mistake, he did not fail to correct it; so, no doubt, Koch will do if he has made a mistake in announcing his "comma-bacillus" as the much sought cholera-germ. It is easy to make mistakes in this field of investigation; easier, perhaps, than to acknowledge them. And believing, as I do, in human fallibility, I have no hesitation in questioning the conclusions of the most illustrious workers in the field of microbiology, if they are in conflict with my own observations. On the other hand, if, upon fuller investigation, I am convinced that I have been mistaken in regard to this or any other question, I shall feel no hesitation in following the example of Pasteur in making a public acknowledgment of my error. At all events, the name will stand for the oval micrococcus which produces a fatal form of septicæmia in rabbits, and which is constantly present in my buccal secretions.

If I am right as to the specific identity of this micrococcus with the micrococcus discovered by Friedländer in the exudate of croupous pneumonia, it does not follow that Friedländer is wrong in assigning to this organism an etiological *rôle* in connection with this disease. This is a question which I will not discuss at the present time, as I hope to make it the subject of experimental inquiry at as early a date as possible.

In giving a specific name to a micrococcus which I first observed nearly

[1] Comptes rendus Ac. de Sc., 1881, xcii. p. 159.

five years ago, and which I have repeatedly studied by means of oil immersion objectives—the one-eighteenth and one-twelfth inch hom. im. of Zeiss—by the most approved methods of staining and cultivation, and by numerous experiments upon animals, I can scarcely be accused of undue haste. And, inasmuch as this is the first microörganism which I have attempted to name among the multitude which I have encountered in the course of my bacteriological studies, I may be acquitted of any special proclivity for conferring names upon supposed "new species," as is the fashion among amateur naturalists.

I have heretofore spoken of this particular micrococcus as "the micrococcus of septicæmia in the rabbit;" but, as there is more than one form of infectious septicæmia in the rabbit known to us by laboratory experiments, each due to a different microörganism, this term is evidently inexact. Moreover, it would indicate that this particular micrococcus finds its usual habitat in the blood of rabbits affected with the form of septicæmia to which it gives rise. This is by no means true, for the organism in question is widely distributed, and it is only by inoculation experiments that the fact has been developed that it is a pathogenic species, so far as rabbits are concerned. I made this discovery in the summer of 1880, quite accidentally, having injected a little of my own saliva under the skin of a rabbit, as a comparative experiment, to ascertain whether a fluid supposed to be innocuous would give rise to any febrile disturbance. The promptly fatal result, and the presence of a multitude of oval organisms in the blood, at once aroused my attention, and, as is well known, I have since made numerous additional experiments, at different times and places, and always[1] with the same result: The animals die in from twenty-four to forty-eight hours; they present the same pathological appearances; their blood is infectious in the smallest quantity, and it contains vast numbers of the oval micrococcus which I now name *Micrococcus Pasteuri*.

Upon making sections of the tissues of a rabbit dead from this form of septicæmia, the oval micrococci are found in great numbers in the capillaries of the various organs, as I am prepared to show. Repeatedly I have produced this infectious disease in rabbits by injecting beneath their skin pure cultures of the micrococcus in question.

All this is a matter of record, and the experimental proof is as definite as is that offered by Koch in regard to the fatal form of septicæmia in mice which he has so well studied, or in the better known infectious dis-

[1] In only a few instances, out of a large number of experiments, have rabbits survived the injection subcutaneously of a few minims of my saliva.

ease, anthrax. Yet, in spite of my detailed record of experiments made, of my frequent repetition of these experiments, and of my photographs from nature which illustrate my first paper, published in 1881, and the article upon septicæmia in rabbits in my book,[1] which was published more than a year ago, I find in Klein's recent work[2] the following reference to my experiments:

"That saliva of the healthy dog, and of man inoculated subcutaneously into rabbits sometimes produces death in these animals [Senator] had entirely escaped his [Pasteur's] notice. Sternberg has proved this in an extensive series of experiments. His own saliva proved sometimes fatal to rabbits. They die of what is called septicæmia, and Sternberg thinks it due to the micrococci; but this is not to be considered as proved."

I claim that the fact is proved, and that the experimental evidence of this has been upon record for nearly four years, and I am prepared to repeat the experiments, and to demonstrate that such is the case. I look upon the fact that an infectious disease of a lower animal may be induced by inoculation with a microörganism which is habitually found as a harmless parasite in the mouth of man, as something more than a curious circumstance to be recorded and forgotten, and as having an important bearing upon vital questions relating to the genesis of "disease germs," questions which are now largely occupying the attention of leading pathologists in all parts of the world. But in the discussion of these questions I must insist that experimental evidence obtained on this side of the Atlantic is entitled to just as much consideration as that which comes to us from across the water. And, unless the truth of my detailed account of experiments made is impeached, I can only account for such a verdict as that which Klein has recorded in the sentence above quoted, upon the supposition that he has not read the evidence presented, or that he is controlled by a geographical bias, unworthy a true student of science, in estimating its value.

In the blood of rabbits recently dead, and in fresh cultures, *Micrococcus Pasteuri* presents the appearance shown in Figs. 1, 2, and 5. The oval elements vary considerably in their dimensions, and especially in length, and are seen solitary, in pairs, or in chains of three or four. When undergoing rapid multiplication they are commonly in pairs, but in surface cultures long chains are often formed as seen in Fig. 3. In these the individual cocci approach more nearly to a spherical form than in the pairs encountered in the blood of a rabbit just dead, where they are

[1] Bacteria. Wm. Wood & Co., New York.

[2] Microörganisms and Disease, 1885.

often so much elongated as to appear rod-shaped. My observations indicate that these rod-like forms are upon the point of division into two pairs of oval elements, and, indeed, upon close inspection with high powers the commencement of transverse division may be recognized in each element of the pair. Morphologically, these pairs of oval or rod-like

Fig. 1.

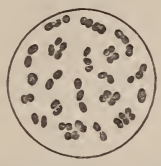

Fig. 2.

Fig. 1.—*Micrococcus Pasteuri* from blood of rabbit inoculated subcutaneously with normal human saliva (Dr. S.). Stained by the method recommended by Friedländer. Magnified 1000 diameters.

Fig. 2.—*Micrococcus Pasteuri* from blood of rabbit inoculated subcutaneously with fresh pneumonic sputum from a patient in the seventh day of the disease. Same staining and amplification as Fig. 1.

elements closely resemble the ordinary bacteria of putrefaction—*B. termo*, and might easily be mistaken for this organism. The supposition that they are identical is easily disposed of. Our micrococcus is, under all circumstances, motionless, while *Bacterium termo* is an actively motile organism. *Micrococcus Pasteuri* is difficult to cultivate, being exceedingly sensitive as regards the composition and reaction of the culture medium. It does not give rise to any putrefactive odor in fluids in which it is present in the greatest abundance. In liquid cultures it causes only a slight opalescence of the culture medium, and its presence upon the

Fig. 3.

Fig. 4.

Fig. 3.—Surface culture of *M. Pasteuri*, showing development of long chains. Same staining and amplification.

Fig. 4.—Surface culture of *M. Pasteuri* from blood of rabbit injected with pneumonic sputum, showing the so-called "capsule" of Friedländer. Same staining and amplification.

surface of Koch's "flesh-peptone-gelatine" can be detected only by close observation. It does not liquefy the gelatine, and does not grow readily on the agar-agar gelatine. In blood serum and in liquid culture media, it is seen with difficulty under the microscope, owing to the fact that its refractive index does not differ greatly from that of the fluid containing

it. On the other hand, *B. termo* thrives in any medium containing gelatine, or albumen, and causes this to undergo putrefactive decomposition.

The pneumonia-coccus of Friedländer is also described as oval in form, or as being found in pairs and in short chains. According to Talamon, "it has the form of a grain of wheat, of from 1 to 4 μ in length, and $\frac{1}{2}$ to 1 μ in diameter. It is isolated, more frequently in pairs, and sometimes in chains of four." This corresponds with the description I have given of *M. Pasteuri.* During the past winter I have made the

Fig. 5.

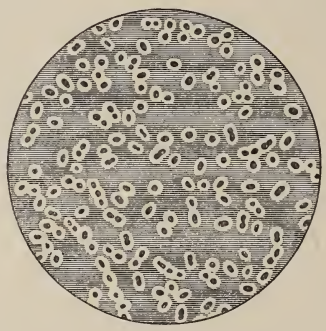

From a photo-micrograph made by the author of this paper in 1881, and used in April of that year to illustrate a paper on "A fatal form of septicæmia in the rabbit induced by the subcutaneous injection of human saliva." The preparation is from the blood of a rabbit recently dead, and is stained with an aqueous solution of iodine and potassic iodide. Magnified 1000 diameters. Photographed with Zeiss's one-eighteenth inch hom. oil im. objective.

acquaintance of this micrococcus as it appears in pneumonic sputum, and I find that morphologically it does not differ from my *Micrococcus Pasteuri.*

But how about the "capsule" which Friedländer has described as the distinguishing character of the pneumonia-coccus? Dr. Friedländer's first communication was made to the Medical Society of Berlin, on the 19th of November, 1883, and this capsule was described as something quite new, and as characteristic of the pneumonia-coccus. In the spring of 1881 I made a photo-micrograph in which oval micrococci in pairs and chains of three or four elements are surrounded by a capsule resembling that described by Friedländer in his communication made two years later. This photo-micrograph was reproduced by the heliotype process, and appears as one of the illustrations which accompany my paper on "a fatal form of septicæmia in the rabbit," published in vol. ii., No. 2, of *Studies from the Biological Laboratory of Johns Hopkins University.* This journal, however, is not likely to come under the eye of

medical men, and it is not surprising that the paper referred to had escaped the attention of Friedländer. The same paper was published in the *Bulletin of the National Board of Health*, of April 30, 1881, but without the heliotype illustration. The micrococci with "capsules" are also shown in Fig. 3, of Plate VI., in my book, *Bacteria*, published in 1884.

Unfortunately, a mistake has been made in the descriptive text facing this plate in my book, where the statement is made that the micrococci in this figure were stained with methyl-violet. This mistake was due to a fault of my memory, and to a failure to refer to my original paper published more than two years before, where the statement is clearly made that "in these photographs the staining was effected with iodine solution" (p. 196).

There can be no question as to the morphological resemblance of the micrococcus represented in this photo-micrograph with that described by Friedländer, and the capsule was brought out in the specimen from which this photo-micrograph was made by the use of the same staining solution which Friedländer recommends for its demonstration, viz., a weak aqueous solution of iodine dissolved by the aid of potassic iodide. In my paper referred to, I say, "In these photographs the staining was effected with iodine solution," and a little further on I gave the formula as follows: "(iodine, grains iij; potassic iodide, grains v; distilled water, grains 200)." In the same paper I give the following account of this envelope of mucous material which Friedländer describes as a capsule:

"The most striking morphological difference between the micrococcus, as shown in Figs. 2, 3, and 4, and in Fig. 1, is the aureole which surrounds the well-defined dark central portion in the latter figure.

"Pasteur says of this appearance: 'This organism is sometimes so small that it may escape a superficial observation. . . . It is an extremely short rod, a little compressed toward the middle, resembling a figure 8. . . . *Each of these little particles is surrounded at a certain focus with a sort of aureole which corresponds perhaps to a material substance.*'

"Pasteur's inference that this aureole represents a material substance, and is not simply the result of diffraction, is fully sustained by my observations and my photographs. The slighter aureole seen in Figs. 2 and 3 is probably a result of diffraction; but the use of aniline-violet as a staining fluid demonstrates that in Fig. 1 we have to do with a material substance. The refractive index of this substance must be very nearly that of blood-serum, for it is with great difficulty that this

aureole can be distinguished without the aid of staining material. It may be seen by the practised eye with a good immersion lens, but, as already mentioned, even the darker central portion, which alone is seen at first, may easily escape observation, and a false impression is obtained as regards the real size of the organism. When, however, a small drop of blood, dried upon a thin glass cover, is immersed for a minute or two in a solution of aniline-violet, and then washed and examined with, even, a good one-fifth inch objective, the observer will be astonished to find a multitude of organisms, solitary, in pairs, and in chains, having a diameter of more than 1 μ, and mostly possessing an oval or elongated form, which might lead to the inference that they should be referred to the genus *Bacterium*, Duj., rather than to *Micrococcus*, Cohn.

"The reason of this apparent change in dimensions as the result of staining is that the substance which constitutes the almost invisible aureole is deeply stained by the aniline, and the central portion, which was before seen because of its higher refractive index, is now lost to view in the uniform and deep violet color which the whole organism possesses."

Friedländer says with regard to his so-called capsule that several micro-chemical tests justify the conclusion that it consists of mucine, or of a substance resembling mucine. His account shows that it is not constantly present, and varies greatly as to the extent of its development. In this his pneumonia-coccus also corresponds with my *Micrococcus Pasteuri*. The development of this external envelope of mucine to the extent shown in my photo-micrograph is altogether exceptional. I have not yet ascertained the exact conditions which control the development of this envelope, but believe it to be most marked in a rich culture-medium, and as a result of an exceptionally vigorous and rapid development of the micrococcus.

Friedländer says: "The formation of capsules appears to be an attribute of the pneumonia-cocci at the highest point of their development."[1]

Prof. Germain Sée, in his recent work,[2] after giving an account of Friedländer's method of staining, says:

"Friedländer attaches such an importance to the capsule of the micrococcus that he declares that it is never wanting in acute fibrous pneumonia, and that in all the other forms of pneumonia studied by him he has only found cocci without capsules. Nevertheless we must hasten to say,

[1] From a review by Warwick in Centralbl. f. kl. med. Wissensch., Berlin, 1884, No. 7, p. 107.

[2] Des Maladies spécifiques du Poumon. Paris, 1885.

this capsule has no value whatever. Talamon does not refer to it. According to him, it does not belong to the coccus; it is the result of the mode of preparation and of staining the exudate. It is met with in various microbes found in bronchial mucus treated by the method of Friedländer. This is also the opinion of Professor Cornil. He says: 'We believe, M. Afanassiew and myself, that the appearance is due simply to a retraction of the liquid around the microörganism, and that the capsules are produced artificially.' On the other hand, Fränkel, at the Medical Congress of Berlin in 1884, declares that the formation of the capsule is not a constant phenomenon; that this capsule is formed in other schizomycetes; finally, that it is not possible to consider the capsules as characteristic of the micrococcus of pneumonia. Friedländer himself, at the same congress, replying to Fränkel, has given the last blow to this famous capsule, in admitting that that which characterizes the micrococcus of pneumonia is neither the capsules, nor its cultures in nail-form, but the sum of the morbid phenomena which it determines. There should then be no further question of micrococci with capsules. It is the form of the microphyte which ought to be taken as characteristic, joined to its pathogenic effects as shown by inoculation." (Op. cit., p. 98.)

A second distinguishing character assigned by Friedländer to his pneumonia-coccus was its peculiar nail-like mode of growth in gelatine cultures. Klein has made the curious mistake of speaking of the coccus itself as nail-shaped. In his recent work,[1] he says (p. 329): "They are oval, of *a peculiar nail-like shape*, about 0.001 mm. long," etc.; and again on the following page: "The micrococci were of *the peculiar nail-like shape*, and were characterized by a mucinous capsule."

Prof. Sée, in the work above referred to, shows that the nail-like growth in gelatine cultures is, after all, not a character of any great value, and that the body of the nail is formed by the growth of the organism along the track of the inoculating needle, and the head by a little knob upon the surface of the gelatine at the point of entrance. Prof. Sée says:

"According to Friedländer, the cultures have a peculiar aspect: upon the surface of the gelatine a little elevation is formed from which a whitish substance extends downward into the nutrient gelatine. This is what the German author speaks of as a nail-shaped culture. The coccus develops at the temperature of the chamber and does not liquefy the gelatine. Here again Friedländer has been mistaken, in describing this aspect of the culture as a peculiarity of the pneumonia microbe. The nail form does not depend upon the organism, but upon the manner in

[1] Microörganisms and Disease. London, 1885.

which one introduces it into the gelatine-peptone, by means of a platinum wire." (Op. cit., p. 90.)

At the same time that Friedländer was pursuing his researches with reference to the etiology of pneumonia in Berlin, Talamon was engaged in similar studies in the laboratory of the Hôtel-Dieu in Paris. His first communication was made to the Anatomical Society, November 30, 1883, a few days after Friedländer's communication to the Medical Society of Berlin. This author has nothing to say about a capsule. The morphology of the organism found by him in the pneumonic exudation, drawn from the lung during life by means of a hypodermic syringe, or obtained post-mortem, corresponds with that of my *Micrococcus Pasteuri*, as will be seen upon referring to Figure 5, which is copied accurately from an illustration in the recent work of Prof. Germain Sée, already referred to. Talamon experimented upon twenty rabbits, two guinea-pigs, four dogs. Injections of liquid cultures directly into the pulmonary tissue of the guinea-pigs and dogs gave a negative result. Of twenty rabbits inoculated in the same manner with the exudate from cases of pneumonia, or with liquid cultures, four recovered after showing symptoms of being sick for five or six days; the others died. Of those which succumbed, two presented no alterations of the lungs, which were scarcely congested, but a "fibrino-serous pleurisy" and fibrinous pericarditis were found. In eight rabbits there was fibrinous pneumonia, sometimes involving an entire lung, sometimes only the inferior lobe. In these cases also there were pleurisy and pericarditis with fibrinous and serous exudation. The blood of the rabbit contained the oval micrococcus in abundance. I call attention here to the fact reported in my first paper on "a fatal form of septicæmia in the rabbit," viz.: that the guinea-pig is less susceptible than the rabbit, and that the dog shows no susceptibility. Nevertheless two out of three of my guinea-pigs succumbed, one in three and one in seven days, while Talamon's guinea-pigs did not die. Moreover, Talamon injected six rabbits subcutaneously, and these all withstood the injection, and showed no special indications of ill health. If then the organism injected was the same as that which I have found to kill rabbits almost without fail, within forty-eight hours, we must admit at least that it has not the same pathogenic potency. My own observations lead me to believe that this micrococcus when obtained from the same source differs in pathogenic power at different times, and that while probably present in the saliva of healthy persons generally, it has not in all cases the same degree of pathogenic power. Thus, in my original experiments, I report as follows:

"The saliva of four students, residents of Baltimore (in March), gave

negative results; eleven rabbits injected with the saliva of six individuals in Philadelphia (in January) gave eight deaths and three negative results; but in the fatal cases, a less degree of virulence was shown in six cases by a more prolonged period between the date of injection and the date of death. This was three days in one, four days in four, and seven days in one."

I also mention the fact that the buccal secretions of two Cuban gentlemen, medical students in Philadelphia, proved to be quite as virulent when injected beneath the skin of rabbits as my own. This, taken in connection with the circumstance that I have spent much time in the South, led me to think that possibly this unusual degree of pathogenic power might be owing to the fact that the variety of the micrococcus to which it is due, and which is constantly in cultivation in my mouth, came from a southern latitude. This supposition receives some support from the experiments of Claxton[1] made in this city, at the University of Pennsylvania, in 1882. The results reported were in general in conformity with those previously reported by myself, but they showed that the saliva of all persons does not exhibit the same pathogenic potency, as manifested by its effects upon rabbits, for of eighteen rabbits injected with the saliva of seven individuals four recovered, five died in less than five days, four in five to ten days, and four in ten to fifteen days. Claxton remarks: "I also have observed the same remarkable virulence in the residents of tropical countries, as Cuba and Brazil, as also in the case of negroes, the saliva of which latter race exhibits it to an extreme degree."

The difference in pathogenic power shown by this oval micrococcus as found in the buccal secretions of healthy individuals corresponds with a difference in the results obtained by three different experimenters who have injected pneumonic sputum into rabbits, in different latitudes. Thus, Friedländer reports a negative result from nine injections made through the thoracic walls, while Talamon had sixteen fatal cases out of twenty injected, and Salvioli,[2] whose experiments were made in Italy, reports a uniformly fatal result, within forty-eight hours, from similar injections made into four rabbits. The greater pathogenic power of the material injected by Salvioli is shown by the fact that his rabbits all died within forty-eight hours, and also by a uniformly fatal result from injections into guinea-pigs (9). The pathological appearances resulting from the

[1] Philadelphia Medical Times, June 17, 1882.

[2] G. Salvioli. Natura infettiva della pulmonite crupale. Arch. per le Scienze Mediche, vol. viii. pp. 127–148 (1884).

injections practised in these two species of animals were identical, and corresponded with those which I had previously obtained from the injection of normal human saliva. All of the authors mentioned refer to tumefaction of the spleen as a constant result. Both Talamon and Salvioli refer to the abundant presence of the oval micrococcus in the blood and effused serum in the pleural cavity of animals which have succumbed to the injections made. The paper of Salvioli is illustrated by some very well-drawn figures, which illustrate the morphology of the organism found by him in the pneumonic exudate and in the blood of animals into which this has been injected. Fig. 6 is copied accurately

Fig. 6.

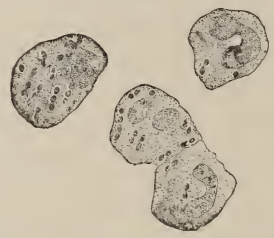

Copied from illustration accompanying the paper of Dr. G. Salvioli in the *Archivo per le Scienze Mediche.* Turin, vol. viii. Tav. viii. Fig. 2. "Cells of the pleuritic exudation containing pneumonia-cocci, mounted in Canada balsam." Stained with gentian-violet.

from this author's Fig. 2, and shows that his pneumonia-coccus is identical morphologically with my *Micrococcus Pasteuri.* The results obtained by the author last mentioned, like those of Talamon and Friedländer, are supposed by their author to establish the fact that croupous pneumonia is an infectious disease. Without denying this fact, we submit that these results are in conformity with the claim made in the present paper as to the specific identity of the oval micrococcus found constantly in the pneumonic exudate with the micrococcus found in normal human saliva which produces an infectious form of septicæmia in rabbits. In support of my claim as to the physiological identity of the oval micrococci from these two sources I offer the following literal translation of the experiments of Salvioli upon rabbits:

"*Jan.* 17, 3 P.M. Rabbit weighing 1970 grammes; very thin when purchased. Injected into right thoracic cavity 1.5 c.cm. of the usual exudation. The rabbit died at 10 A.M. on the 19th. At the post-mortem examination made immediately after death we noted: collection of turbid serum in the right pleural cavity which coagulated after being drawn. Fibrinous pseudo-membrane upon the surface of the lung, especially the inferior lobe. Lung, especially the inferior lobe, enlarged

and congested; contains little air. Upon section a little serum escapes from the surface. Spleen congested. Characteristic pneumonia-cocci in the pleuritic exudation; not in spleen. Upon microscopical examination of an indurated piece of lung, micrococci were found in the costal and visceral pleuræ, and in the pulmonary tissue, presumably between the lymphatics; and in the pulmonary alveoli. Near the pleura a slight collection of fibrinous exudation."

"*Jan.* 20, 3 P.M. Rabbit weighing 2080 grammes, of Sardinian race, of exceptional resistance, and therefore adapted to the experiment. Injected into right thoracic cavity 1 c. cm. of the exudate from the dog"—killed at a previous experiment.

"At noon on the 21st the rabbit was found dead. At the autopsy a turbid liquid, rich in pneumonia-cocci, was found in the right pleural cavity; infiltration of the mediastinal cellular tissue by a turbid serum rich in cocci; fibrinous pseudo-membrane upon the right pleura. Spleen enlarged, and with cocci in its pulp. At the examination of a hardened specimen cocci were found in the pleura, visceral as well as parietal, and also in the pulmonary tissue in the vicinity of the pleura. In this, also, was found a little of the fibrinous exudation in the alveoli."

"On the 28th I received another specimen of exudate from the medical clinic, which had been extracted[1] from a patient with fibrinous pleuro-pneumonia, in the twelfth day of sickness. The slightly turbid liquid had an alkaline reaction and pale yellow color. When allowed to stand a sediment was deposited corresponding to one-eighth of the liquid column. A microscopic examination of the sediment showed the presence of leucocytes, red globules, a quantity of granular material, and some very rare pneumonia-cocci, but slightly stained, notwithstanding a repetition of the preparation; instead, I observed some smaller granules which did not take the color, which resisted drying, and which I have called spores. This exudate I injected into two guinea-pigs, two rabbits, and two dogs. *Only the rabbits gave me a favorable result.*[2] The other animals survived and did not present the slightest disturbance."

"*Jan.* 28, 1 P.M. Rabbit weighing 1920 grammes; injected into right thoracic cavity 1 c. cm. of the above serum after mixing up the sediment. The rabbit was found dead on the morning of the 29th, and at the autopsy there was an abundant, turbid, sero-fibrinous exudation in the right pleural cavity, fibrinous pseudo-membrane upon the pleura.

[1] I understand that the liquid was extracted from the pleural cavity by an aspirating syringe, although this is not distinctly stated.—G. M. S.

[2] Italics by translator.

The cellular tissue of the mediastinum was infiltrated with turbid serum, parenchyma of right lung partly deprived of air by compression, with this exception normal [free translation for '*del resto nulla di particolare*']. Spleen enlarged; pneumonia-cocci in the pleuritic exudation and in the splenic pulp. At the microscopic examination of a hardened piece the pneumonia-cocci were found in the pleura, in the pulmonary tissue also, at a distance from the pleura.[1] In some alveoli, in the vicinity of pleura, was found a fibrinous exudation.

"*Jan.* 28, 2 P. M. Rabbit weighing 1890 grammes; injected into right thoracic cavity 1 c. cm. of limpid serum. On the morning of the 31st the rabbit died, and at the autopsy were found turbid exudation in right pleural cavity, fibrinous pseudo-membrane upon the pleura, right lung enlarged, resistant, non-crepitant; the inferior lobe presented the aspect of red hepatization; pronounced tumefaction of the spleen. The characteristic pneumonia-cocci were found in the exudate, in the pulmonary juice, and in the splenic pulp."[2]

I shall now record some recent experiments made by myself.

Nov. 29, 1884. Inoculated rabbit subcutaneously with pneumonic sputum brought to me by a medical gentleman in Baltimore, from a patient, aged sixty, in the sixth day of the disease. The doctor had carried this sputum in his pocket for twenty-four hours before handing it to me. Result negative.

Jan. 2, 1885. Inoculated two rabbits subcutaneously with pneumonic sputum, collected with great care by my friend, Dr. Rohé, and brought to me at once—from a white male patient, aged nineteen, in the seventh day of illness, second day of bloody expectoration. Both rabbits were found dead on the morning of January 4th. In both the pathological appearances were identical with those constantly observed by me in rabbits killed by the subcutaneous injection of my own saliva, viz., extensive inflammatory œdema extending from point of injection, enlarged spleen, and presence of oval micrococci in blood and in effused serum in the subcutaneous connective tissue. Fig. 2 is drawn from a slide mounted at the time, and represents this micrococcus as seen in the blood.[3]

Remarks.—It may be asked whether possibly my *Micrococcus Pasteuri* may not have been present, accidentally, in the pneumonic sputum, as a

[1] They had invaded the blood and were distributed through the capillaries generally.—G. M. S.

[2] Op. cit., p. 133.

[3] This and the other figures illustrating the present paper are from camera lucida drawings made by my laboratory assistant, Dr. A. C. Abbott, of Baltimore.

result of the fact that the exudate into the alveoli of the lungs must come in contact with the buccal secretions of the patient when it is expectorated. In reply to this supposition I would say that I have a slide, which I shall be happy to submit for the inspection of microscopical experts, which shows the capsule of Friedländer in a most beautiful and unmistakable manner. This slide is from a surface culture which was started from the blood of one of these rabbits inoculated with pneumonic sputum. (See Fig. 4.) I cannot, then, doubt that this is in truth the micrococcus described by Friedländer; and, as in the blood of the rabbits, it was identical morphologically with my *Micrococcus Pasteuri* (compare Figs. 1 and 2), and shows identical physiological characters when injected beneath the skin of these animals, I feel justified in assuming the specific identity of the micrococci from the two sources.

March 14. Four rabbits were injected subcutaneously with a small quantity (about 1 c. cm.) of my own saliva. Two of these rabbits were found dead on the morning of March 16th, and the other two died during the morning. All presented the usual pathological appearances so often described, viz., enlarged spleen, extensive subcutaneous œdema, slight hemorrhagic extravasations, etc. The blood of all these rabbits contained the oval micrococcus in abundance. (Fig. 1 is drawn from a preparation mounted at the time.) Cultures were started from this blood, and served for the following experiment:

March 31. I injected into the thoracic cavity of two rabbits, by means of a hypodermic syringe, a small quantity of a culture of *M. Pasteuri*, in Koch's flesh-peptone gelatine. Both rabbits were found dead the following morning. In both the pleural cavity contained turbid serum, and there was a fibrinous deposit upon the surface of the lung on the side (right) into which the injection was made. The margin of the lung in one appeared congested, but there was no inflammation of the lungs, which floated in water.

Remarks.—Death occurred in these cases more promptly than when I have injected the same material subcutaneously. This is not surprising, for it seems probable that the blood would be invaded by the parasite more promptly when it is thrown into the pleural cavity than when injected subcutaneously. As a matter of fact, in injecting saliva or culture fluids subcutaneously I have observed that the animal commonly presents no indications of being ill during the first twenty-four hours, and that during this time the inflammatory œdema at the point of puncture has made but little progress, as shown by the slight extent of local tumefaction. The pleurisy and fibrinous exudation upon the surface of the lung in these rabbits correspond with what the authors above referred

to have reported as a result of the injection in the same way of pneumonic exudate. It may be that if death had not occurred at so early a period, the lungs would have become involved, and that these cases could have been placed beside those reported by Talamon, in which unmistakable pneumonia is said to have been produced by the injection into the thoracic cavity of rabbits, of pneumonic exudate, or of culture fluids. The superior pathogenic potency of the micrococcus in my experiment above reported is shown by the brief period between the time of injection and the date of death. But, although this period was less than twenty-four hours, the blood of these rabbits, as well as the effused serum in the pleural cavity, contained the oval micrococcus in vast numbers.

I have been led to suspect, from the fact that while fibrinous pleurisy is a constant result in the experiments reported by Talamon and by Salvioli, fibrinous exudation in the lung tissue is only occasionally found, that perhaps the development of pneumonia depends upon the penetration of the lung by the point of the syringe and the injection of the infectious material directly into the lung substance. I can easily understand how this result might occur, if the local effect of the presence of the micrococcus in the lung is the same as when it is introduced into the subcutaneous connective tissue—that is, the infiltration of the tissue with an inflammatory exudate, which gives rise to the appearance which I have generally spoken of as an inflammatory œdema.

April 7, 4 P. M. Injected through the walls of the thorax, on the right side, by means of a hypodermic syringe, a small quantity of pneumonic sputum, from a case in the practice of Dr. Mitchell. The sputum was collected with due care by my laboratory assistant, Dr. A. C. Abbott. Both rabbits were found dead the following morning. There was considerable turbid serum in the right pleural cavity, and a fibrinous deposit upon the surface of the lung of the same side. The lung floated in water and gave no evidence of being inflamed, but was stained of a reddish color. The spleens of these rabbits were but slightly enlarged.

Remarks.—I have frequently noticed that, in cases so quickly fatal, tumefaction of the spleen is not so marked as in cases of longer duration. The blood of one of these rabbits contained the oval micrococcus in great abundance; blood drawn from the femoral vein of the other contained a small number of the same organism in pairs and chains of three or four. The turbid serum from the pleural cavity contained the microbe in great numbers.

Since the above was written the following experiment has been made:

On the afternoon of April 9th Dr. Councilman, Assistant in Pathology

in Johns Hopkins University, and Pathologist at Bay View Hospital, handed me a portion of hepatized lung from a case of pneumonia at Bay View, in which the post-mortem examination was made within six hours after death. The exudate, scraped from a freshly cut surface of the lung tissue, was spread upon thin glass covers, and stained by the method recommended by Friedländer for the demonstration of his so-called pneumonia-coccus. Micrococci of oval form in pairs and in chains of three or four elements were found in abundance, but they were not surrounded by a capsule.

April 9, 4 P. M. A little of the exudate, scraped from a freshly cut section of the hepatized lung above referred to, was mixed with distilled water and injected into the right thoracic cavity of a small rabbit, by means of a hypodermic syringe. At the same time a little of my own saliva was injected into another small rabbit, of the same litter, in the same manner. Rabbit No. 1, injected with pneumonic exudate, was found dead on the morning of April 12th. Upon opening the cavity of the thorax the lungs were found to present a normal appearance, except that the inferior lobe of the right lung had a blood-red color, apparently due to a hemorrhagic infarct; both lungs floated in water. The right pleural cavity contained turbid serum, in which, as well as in the blood, the presence of numerous oval micrococci was demonstrated by microscopical examination. Several specimens were stained by the method recommended by Friedländer, but no distinct appearance of a capsule was made out. The spleen was considerably enlarged.

On the morning of April 13th, rabbit No. 2 was found dead. There was but slight evidence of pleurisy, but the right lung was indurated, of a gray color, and sank in water.

Remarks.—The spleen of this rabbit was not enlarged, and its blood did not contain the septic micrococcus. The development of pneumonia in this case was doubtless due to the fact that the point of the syringe had penetrated the lung, and the injection had been made directly into the lung tissue. Such a result must depend to a great extent upon accident, and in making injections through the thoracic walls it is impossible to say in advance of the post-mortem examination whether the fluid has been injected into the pleural cavity or into the lung substance.

A microscopical examination of the lung after it had been hardened in alcohol showed that there was a necrotic focus of some extent surrounded by an extended area of indurated lung tissue, which presented the appearance of catarrhal rather than of croupous pneumonia. There was also interstitial hemorrhage in the vicinity of the necrotic centre, and there can be little doubt that this marked the point to which the syringe

had penetrated when the injection was made. The oval micrococcus was not found in the inflamed lung tissue, and I am not able to ascribe to it any special import in the development of the inflammation in this particular case.

I must now refer to Friedländer's experiments upon mice, guinea-pigs, and dogs, and shall quote from the recent work of Prof. Sée already referred to:

"All of the mice succumbed in from eighteen to twenty-eight hours after the injection. At the autopsy the lungs were found to be highly congested, almost empty of air, and to contain foci—*noyaux*—of red induration. Out of eleven guinea-pigs six died with pneumonic lesions. Out of six dogs only one succumbed. In another series of experiments mice were made to inhale a spray of a culture fluid containing the coccus in suspension. Several of these animals succumbed. At the autopsy Friedländer says that he found the appearance of typical pneumonia, and verified the presence of numerous micrococci with capsules in the lungs, the spleen, the blood, and the pleural liquid." (Op. cit., p. 90.)

I would like to inquire how it is that to produce pneumonia in animals Friedländer and his followers consider it necessary to introduce the infectious material into the pleural cavity or into the substance of the lung itself with a sharp-pointed instrument. If this coccus is the germ of infectious pneumonia, one would think that to inject it subcutaneously ought to give rise to the local lesion, just as the subcutaneous injection of tuberculous sputum gives rise to tuberculosis of the lungs. We find from the accounts given that when injected into the lung or introduced by inhalation, the micrococcus invades the blood, and produces enlargement of the spleen; but to produce the characteristic local inflammation which it is supposed to be the especial function of this micrococcus to produce, it does not suffice to inject the micrococcus beneath the skin or into the blood; it must be injected through the walls of the thorax with a sharp-pointed syringe. And when so injected only a certain proportion of the animals have pneumonia. Prof. Sée, while accepting Talamon's experiments upon rabbits as demonstrating the infectious nature of croupous pneumonia, is not inclined to accept the demonstration which Friedländer claims to have made by his experiments upon mice. He says:

"The rather brief description of the lesions in the mouse, which Friedländer has given, leaves some doubt in the mind; for the presence of centres—*noyaux*—of induration in the congested lungs does not suffice to characterize fibrinous pneumonia."

I would here call attention to the fact referred to in my first paper on

a fatal form of septicæmia in the rabbit, viz.: that in this infectious disease there are sometimes found hemorrhagic infarcts in the lungs. I quote from this paper as follows:

"Pasteur says, 'The lungs are frequently filled with the *noyaux* of pulmonary apoplexy.' (I have found this to be the case in one out of three rabbits examined since my attention has been directed to this point.) 'A character more constant than the last (not more constant, however, than that which relates to the volume and color of the *ganglions*), is the state of the trachea, which is almost invariably red, congested, with little hemorrhages from the smallest vessels.' (I have found a marked congestion of the vessels of the trachea in the three cases in which I have examined it, and in one case the lymphatic glands of the axillæ were enlarged and congested.)"

The possibility has frequently occurred to me that this same micrococcus may be concerned in the etiology of diphtheria. The fact that it causes inflammatory œdema of the subcutaneous connective tissue, and that when introduced into the pleural cavity it causes a copious fibrinous deposit upon the lung, taken in connection with the fact that it has been shown to be a pathogenic organism having different degrees of potency under different circumstances, seems to justify the suspicion that there may be a pathogenic variety which has a special propensity for locating itself in the mucous membrane of the fauces. Certainly the suddenly developed inflammatory œdema and fibrinous exudation which characterize malignant diphtheria, correspond with the local effect produced when this micrococcus is inoculated into susceptible lower animals. The experiments of Löffler[1] seem to show that the widely distributed spherical micrococcus which forms long chains and zooglœa masses is not the germ of diphtheria, and this observer speaks of a *bacillus* as being found in the deeper portion of the pseudo-membrane in cases of diphtheria. I have no exact information as to the morphology of this bacillus, but knowing that, in the nomenclature of some bacteriologists, the name micrococcus is reserved exclusively for spherical organisms, I am not prepared to dismiss this supposition without further investigation.

I herewith submit the following conclusions for consideration:

The pneumonia-coccus of Friedländer is identical specifically with the micrococcus previously described by me, and which is commonly found in normal human saliva. The capsule, or mucous envelope, which sometimes surrounds this micrococcus, described by Friedländer in 1883, and

[1] I have not the paper of this author at hand, and am indebted to an editorial in the Medical Record of January 31, for the facts here given.

photographed by me two years previously, cannot be accepted as a distinguishing character of this species, inasmuch as it is not constantly present, and the circumstances upon which its development depends have not been accurately determined. It is established that this is a pathogenic organism, so far as certain lower animals are concerned, and that its pathogenic power varies under different circumstances. It seems extremely probable that this micrococcus is concerned in the etiology of croupous pneumonia, and that the infectious nature of this disease is due to its presence in the fibrinous exudate into the pulmonary alveoli.

But this cannot be considered as definitely established by the experiments which have thus far been made upon lower animals. The constant presence of this micrococcus in the buccal secretions of healthy persons indicates that some other factor is required for the development of an attack of pneumonia; and it seems probable that this other factor acts by reducing the vital resisting power of the pulmonary tissues, and thus making them vulnerable to the attacks of the microbe. This supposition enables us to account for the development of the numerous cases of pneumonia which cannot be traced to infection from without. The germ being always present, auto-infection is liable to occur when from alcoholism, sewer-gas poisoning, crowd-poisoning, or any other depressing agency the vitality of the tissues is reduced below the resisting point. We may suppose also that a reflex vasomotor paralysis, affecting a single lobe of the lung, for example, and induced by exposure to cold, may so reduce the resisting power of the pulmonary tissue as to permit this micrococcus to produce its characteristic effects.

Again, we may suppose that a person, whose vital resisting power is reduced by any of the causes mentioned, may be attacked by pneumonia from external infection with material containing a pathogenic variety of this micrococcus having a potency, permanent or acquired, greater than that possessed by the same organism in normal buccal secretions.

Figs. 1, 2, 3, and 4 are from camera lucida drawings made by my laboratory assistant, Dr. A. C. Abbott, of Baltimore, to whom I am also indebted for valuable assistance in conducting the recent experiments herein recorded. The drawings were made with an amplification of 2500 diameters, obtained by the use of a Zeiss's one-eighteenth inch homogeneous oil-immersion objective and a high eye-piece (Powell and Lealand large stand, tube drawn one inch). These drawings have been reduced by photography to two-fifths, in order to give an amplification of 1000 diameters in the figures.

[Dr. Sternberg has since modified his views as to the specific identity of his *M. Pasteuri* and of Friedländer's "pneumococcus." At his request

the following communication, published in *The American Journal of the Medical Sciences* for July, 1886, is appended to his paper read before the Pathological Society in April, 1885.]

In a paper read before the Pathological Society in April, 1885, the writer gave the name *Micrococcus Pasteuri* to a pathogenic micrococcus which was first observed by him in 1880, in the blood of a rabbit injected subcutaneously with normal human saliva. In the paper referred to, and in a second paper published in the October number of the *American Journal of the Medical Sciences*, the *specific* identity of this micrococcus with the so-called "pneumococcus" of Friedländer was maintained.

In my second paper I say:

"In claiming that the micrococcus of Friedländer is specifically identical with my *M. Pasteuri*, it must be understood that I use the word *species* in its botanical sense, and that I recognize different varieties—physiological or pathogenic varieties of more or less permanence—of the same species."

I had not at this time seen cultures of Friedländer's coccus, but felt justified in assuming *specific identity* on the grounds stated. I have since had an opportunity to compare the Friedländer coccus in pure cultures, obtained from Dr. Koch's laboratory in Berlin, with my *M. Pasteuri*, and I recognize differences which I cannot reconcile with the idea of specific identity.

My inference was based chiefly upon the experimental data showing the presence of *M. Pasteuri* in pneumonic sputum, for I could not doubt that the organism which I found in this material and which I tested by inoculation into rabbits, and by cultures in liquid and in solid media, was identical with the micrococcus which I had so often obtained in pure cultures by the injection of my own saliva beneath the skin of a rabbit. I am still convinced that this is true, and also that in the experiments of Talamon[1] and of Salvioli[2] my *M. Pasteuri*, and not Friedländer's micrococcus, was the organism found in the blood of rabbits after inoculation with pneumonic exudate. This is shown by their account of the results of their experimental inoculations, which correspond entirely with my own, whereas the Friedländer coccus does not kill rabbits.

Talamon inoculated twenty rabbits with pneumonic exudate or with

[1] American Journal of the Medical Sciences, 1885, p. 114.

[2] G. Salvioli. Natura infettiva della pulmonite crupale. Arch. per le Scienze Med., vol. viii. pp. 127–148, 1884.

liquid cultures, and of these all but four died. In the non-fatal cases the animals were sick for five or six days and then recovered. Of the fatal cases, two presented no alterations of the lungs, which were scarcely congested, but a "fibrino-serous pleurisy" and fibrinous pericarditis were found. In eight rabbits there was fibrinous pneumonia, sometimes involving an entire lung, sometimes only the inferior lobe. In these cases also there were pleurisy and pericarditis with fibrinous and serous exudation. The blood of the rabbits which succumbed, contained the oval micrococcus in abundance. Salvioli's injections of pneumonic exudate also proved fatal to rabbits, and, as stated, the pathological appearances described correspond with those which I have reported from similar injections.

Both of the authors mentioned infer from their experiments that croupous pneumonia is an infectious disease, and that the micrococcus found by them in the blood of inoculated animals—*M. Pasteuri*—is directly concerned in its etiology. The experimental evidence which they offer is quite as good as that upon which Friedländer has founded the claim that his micrococcus is the specific germ of croupous pneumonia; for his experiments upon mice, which furnish the only support for this claim, are generally conceded not to be convincing. My inference that the organism found by Talamon and by Salvioli in pneumonic exudate, was identical with that which I had previously found in the blood of rabbits inoculated with normal human saliva, is confirmed by the recently published experiments of Fränkel.[1]

This author, when he commenced his experiments, about three years ago, had no knowledge of my previously published experiments.[2] It was by injecting my saliva as a control experiment that I discovered, in the summer of 1880, that it contained a pathogenic organism fatal to rabbits. In like manner Fränkel discovered that his saliva contained the same organism, and, extending his experiment, ascertained that the saliva of other persons in health, or sick with various diseases, contained the same pathogenic micrococcus.

The morphological and physiological characters of this micrococcus as given by Fränkel correspond precisely with my own recorded observations, and the figures which illustrate his paper, upon comparison with my photo-micrograph published in 1881, will be found to sustain

[1] Zeitschrift für klin. Med., Band x., H. 5 und 6, S. 402–460, 1886.

[2] Published in the Bulletin of the National Board of Health, of April 30, 1881, and also in Studies from the Biological Laboratory of Johns Hopkins University, vol. ii., No. 2, 1881.

the view that the organism as discovered by him in Berlin in 1883, does not differ from that which I obtained from a similar source in New Orleans in 1880. This is fully recognized by Fränkel, who also agrees with me as to the identity of this micrococcus with that discovered by Pasteur in the blood of a rabbit inoculated with the saliva of a child who died of hydrophobia in one of the hospitals of Paris, December 11, 1880.

Fränkel's experiments correspond with my own also in showing a difference in the pathogenic potency of the saliva of different individuals, and of the same individual at different times. His own saliva was uniformly fatal to rabbits when he commenced his experiments, but a year later it was without effect. I also have found a notable diminution in the pathogenic potency of my saliva during the past two years. During the years 1880–1883 my inoculations almost infallibly caused the death of a rabbit within forty-eight hours. During the past two years I have had quite a number of failures, and in fatal cases death more commonly occurs on the third or fourth day. This result I believe to be due to a diminution in the pathogenic power of the micrococcus, rather than to its absence at times from my buccal secretions.

My earlier experiments showed that the blood of an infected rabbit just dead, is more potent than a liquid culture, or than saliva containing the micrococcus. In short, there is evidence that the organism differs in pathogenic power at different times and under different circumstances.

I have noted that in those instances in which an animal recovers after the injection of my saliva, it is found to be immune when subsequently injected with the more potent virus—blood from a rabbit just dead; and also that a non-fatal attack and subsequent immunity result from the injection of infectious material—blood—which has been subjected to the action of certain chemical agents—sodium hyposulphite, and alcohol.[1] In referring to these results in a later publication, I said:

"It seems probable that a variety of antiseptic substances will be found to be equally effective when used in the proper proportion. Subsequent experiments have shown that neither of these agents is capable of destroying this micrococcus in the proportion used (one per cent. of sodium hyposulphite, or one part of ninety-five per cent.

[1] Experiments with Disinfectants. National Board of Health Bulletin, Washington, 1881, vol. iii., No. 4; also Studies from Biological Laboratory of Johns Hopkins University, Baltimore, 1882, vol. ii., No. 3.

alcohol to three parts of virus), and that both have a restraining influence upon the development of this organism in culture fluids."[1]

The experimental evidence here referred to I believe to be the first recorded with reference to the "attenuation of virus" by the use of chemical reagents.

Fränkel has obtained some interesting results by inoculating rabbits in the ear. He has thus produced a local infection from which the animal recovers after a few days, and has proved that this is subsequently immune.

His inoculations into guinea-pigs, fowls, and dogs gave results corresponding with those previously reported by me—fowls and dogs immune and guinea-pigs less susceptible than rabbits. He has also tested the pathogenic powers of the organism upon cats, pigeons, and mice. The first-mentioned animals are not susceptible, but mice die within forty-eight hours after being inoculated. He finds, as I have found, that the disease produced by subcutaneous inoculation is at first local, and that an inflammatory œdema is induced, which extends in all directions from the point of inoculation. General blood-infection does not usually occur until a short time before death. I have recently obtained a pure culture of the organism by drawing a little serum from the œdematous connective tissue near the point of injection, through a capillary pipette, in a rabbit which was still in apparent good health.

Fränkel has always been able to obtain a pure culture from blood taken from the heart of a rabbit just dead, and it is from this source that I have usually obtained my pure stock for experimental purposes. He also finds that the organism may be cultivated in veal broth which has been carefully neutralized, but that it does not grow at the ordinary room temperature. A temperature of 30° to 35° C. is necessary for its development. Upon agar-agar, or on solidified blood-serum, it grows, within twenty-four hours, in the form of a superficial, nearly transparent deposit of gelatinous consistence. In surface cultures I have often found the organism to form long chains, and, if we accept the classification of Zopf, it must be assigned to the genus *Streptococcus*. In fluid cultures it is commonly found in pairs or in chains of four elements. Fränkel finds the maximum temperature at which the organism will grow to be 42.5° C.

Very interesting are the results obtained by Fränkel in his inoculations with cultures made at different temperatures, and especially with a fluid culture which had been kept at a temperature of 35° C. for sixteen

[1] Bacteria, Magnin-Sternberg, 2d ed., 1884, p. 207.

days. I quote in full the record of the last-mentioned experiment, in which we have evidence of a remarkable modification of pathogenic power which is very significant.

On March 12th, 0.4 c. cm. of a pure culture in veal broth was injected into the right lung of a rabbit. This culture had been kept in the incubator at 35° C. since the 25th of February. Temperature of rabbit before injection, 39.4° C.; the following day the same; March 14th, 40.7°; March 15th, 39.6°; March 16th, dead. Since the preceding day there had been severe dyspnœa. At the autopsy fibrinous pleuritis on both sides, and fibrinous pericarditis was found. In the right pleural cavity only a few drops of fluid exudate. Enormous tumefaction of the spleen; typical cocci in the blood. *The inferior lobe of the right lung entirely hepatized, grayish-red, in part already changed to gray hepatization.* Sections of granular consistence, as in genuine croupous pneumonia in the human lung. The left lung also presented an evident engorgement.

The results obtained by Fränkel with reference to the influence of various temperatures on the pathogenic power of this micrococcus are as follows: In fluid media a temperature of 42° C., maintained for two days, suffices to neutralize the virulence of the culture. The same result is obtained at a temperature of 41°, maintained for four or five days. Between 39.5° and 40.5° the virulence is no longer abolished, but is so far modified that inoculations no longer give rise, in the rabbit, exclusively to the typical condition of the blood and enlarged spleen of septicæmia, but simultaneously to an intense localization of the virus in the serous membranes of the heart and lungs.

In his experimental injections of pneumonic sputum Fränkel has obtained results identical with my own, detailed in my paper published in the *American Journal of the Medical Sciences* for July, 1885, and with those of Talamon and of Salvioli. He finds that no sputum is more certain to contain this micrococcus than the rusty sputum of patients with pneumonia. In the course of two years he has made thirty-eight subcutaneous injections into rabbits of sputum mixed with distilled water, or with a dilute solution of carbonate of soda (0.3 per cent.). Twenty rabbits were injected with sputum obtained from genuine cases of croupous pneumonia between the second and sixth day of sickness. Exactly one-half of these animals died of typical "sputum-septicæmia;" the remaining ten were not affected, or suffered from other septic processes. The remaining eighteen rabbits were injected with the saliva of healthy individuals (five), or with the sputa of patients suffering from other pulmonary diseases than pneumonia—mostly acute or chronic bronchial catarrh. Of these eighteen, only three had typical septicæmia.

Fränkel has made a very interesting observation with reference to modification of virulence which is in accord with the results of my own experimental studies. He finds that the micrococcus does not disappear from the sputa of patients with pneumonia after the termination of the disease, and has proved by injection experiments that it may still be present at the end of some weeks. But his experiments show that the virulence is no longer so considerable, and that death may occur as late as the sixth day, instead of in from twenty-four to forty-eight hours, as is the case when the rusty sputum of the inflammatory stage of the disease is the material injected.

The experimental evidence on record shows, then, that M. Pasteuri, which is present in the buccal secretions of healthy individuals in various parts of the world, is also found, with greater certainty, in the exudate of croupous pneumonia. Whether it is found in this material simply because it is at hand in the buccal cavity, and finds in the pneumonic exudate a suitable medium in which to develop, or whether it is concerned in the etiology of croupous pneumonia, is an unsettled question. We have experimental evidence, however, that this micrococcus does give rise to local inflammation, accompanied with a serous or sero-fibrinous exudate, when it is injected into the subcutaneous connective tissue, or into the pleural cavity of rabbits.

In my paper heretofore referred to, I have ventured to suggest an hypothesis which seems to reconcile clinical observations with the experimental data, and enables us to account for the occurrence of isolated cases of croupous pneumonia, without denying the infectious character of the disease. (See page 179.)

This hypothesis does not exclude the view that Friedländer's micrococcus, and perhaps other pathogenic organisms, may act in like manner. We may eventually find that there are various pneumonia-cocci, just as we have learned that the pus of acute abscesses contains sometimes one and sometimes another coccus, or again two or more in association. It can scarcely be doubted that these pus organisms are responsible for the local inflammatory changes which give rise to the formation of abscesses. But furuncles and abscesses cannot generally be traced to external infection, and it seems probable that, as a rule, they are due to auto-infection, and that the organisms which produce them are widely distributed and always at hand ready to take advantage of circumstances relating to the individual which are favorable to their development. In like manner general blood infection—septicæmia—may, perhaps, result from auto-infection in certain cases.

The conclusions of Fränkel are in accord with the views stated in

my paper referred to. This author concludes his elaborate paper as follows:

"Finally, as regards the relative frequency of the two hitherto investigated microbes, in cases of pneumonia, no positive statement can yet be made. Nevertheless, I am inclined to regard the lancet-shaped pneumonia-coccus, which is identical with the microbe of sputum-septicæmia, as the more frequent and the usual infectious agent of pneumonia, on the ground that this organism is so much more frequently found in the sputum of pneumonic patients than in that of healthy individuals. This conclusion is further supported by the circumstance that it has not hitherto been possible to isolate directly from the rusty sputum, Friedländer's bacillus."

The evidence furnished by Talamon's experiments is decidedly favorable to the view that this micrococcus may be concerned in the etiology of croupous pneumonia. Thus Prof. Germain Sée, in his recent work,[1] says:

"The rather brief description of the lesions obtained by Friedländer in inoculated mice, leaves some doubt in the mind; for the presence of indurated foci—*noyaux*—in congested lungs does not suffice to characterize fibrinous pneumonia. But the lungs of rabbits presented by Talamon to the Anatomical Society, in support of his communication, cannot be the subject of discussion. As he remarks, the appearances are not at all those of foci of broncho-pneumonia in a congested lung, as one constantly observes in rabbits dead of septicæmia, but a veritable lobar fibrinous pneumonia with pleurisy and pericarditis of the same nature. The naked-eye appearances, as well as the microscopical examination, showed no difference between the lesions produced in the rabbit and the pneumonia of man." (Op. cit., p. 92.)

Evidently Prof. Sée supposes, as I did for a time, that the micrococcus which Talamon encountered in pneumonic exudate, and which produced the effects described, is identical with that of Friedländer. That this is a mistake is now apparent. No doubt, Talamon's results were due to the presence of *M. Pasteuri* in the pneumonic material and culture-fluids which he used in his inoculation experiments. This is shown by the fact that sixteen out of twenty rabbits injected died, while Friedländer's coccus does not kill rabbits. Of the twenty rabbits injected directly into the lung, eight are said to have presented the lesions of fibrinous pneumonia, together with fibrinous pleurisy and usually fibrinous pericarditis. "The blood of the rabbits contained the *elliptical* coccus in

[1] Maladies Spécifiques (non-tuberculeuse) du Poumon. Paris, 1885.

abundance." Both Fränkel and Talamon sometimes speak of this coccus as lancet-shaped or lanceolate. Prof. Sée says:

"Seen in the fibrinous exudate, the microbe has an elliptical form like a grain of wheat. Cultivated in a liquid medium, an alkaline solution of meat extract, it is more elongated and takes the aspect of a grain of barley."

I have commonly spoken of this micrococcus as oval, but in the blood or in a rich culture medium, when in active growth, it is often so long an oval as to appear lanceolate.

On the other hand, in surface cultures it often approaches more nearly a spherical form.

Sänger,[1] in a paper recently published, maintains that neither the capsule nor the nail-shaped growth in gelatine is peculiar to Friedländer's pneumococcus. This author has isolated five different micrococci by means of plate cultures, from pneumonic exudate.

Thost,[2] of Hamburg, has demonstrated the presence of Friedländer's coccus in great numbers in the nasal secretions of patients suffering from ozæna. It was found in twelve out of seventeen cases, and was isolated by Koch's plate method. The coccus obtained from this source was proved by culture and inoculation experiments to be identical with that described by Friedländer. It does not kill rabbits, but is fatal to mice. These experiments were made in the laboratory of Prof. Frisch, of Vienna.

---

16. *Notes on the morbid anatomy of pneumonia.*

Read by Dr. William Osler.

My post-mortem records include 105 cases of lobar pneumonia, all of which, with one or two exceptions, occurred at the Montreal General Hospital. For the purposes of this article, I shall exclude five cases, in which the data are incomplete. As is the case at most large hospitals, the death-rate from this disease is high, due, first, to the fact that, as a rule, only the severer cases are brought in; and, second, that a con-

[1] Bacteriologische Untersuchungen über die Pneumonie und pneumonische Metastasen. Archiv f. exper. path. u. phar., B. xx. H. 5 u. 6, 1886.

[2] Pneumoniekokken in der Nase, Deutsche med. Wochenschrift, No. 10, March 11, 1886.

siderable proportion of the cases occur among enfeebled and dissipated paupers, who rapidly succumb to such an acute affection as pneumonia. In the statistical report of Dr. James Bell,[1] the mortality for a period of ten years was somewhat over 25 per cent., one-third of the deaths occurring within forty-eight hours of admission. As a contrast, it may be stated that the mortality of the cases of pneumonia in the practice of Prof. R. P. Howard, of Montreal, during a period of twenty years, was only 4.8 per cent.

The statistical details are as follows:

Sex.—Of the 100 cases, 70 were in males, and 30 in females.

Age.—In 94 instances the age was given: up to 10th year, 5 cases; between 10th and 20th, 6; from 20th to 30th, 12; between 30th and 40th, 18; between 40th and 50th, 21; between 50th and 60th, 12; and over 60, 20 cases.

Lung affected.—In 51 cases, the right; in 32 cases, the left; in 17, both. As to the position of the inflamed region in the lung the figures are: in the right whole organ solidified (except, perhaps, narrow margin at apex and anterior border) in 17; lower lobe alone, in 18; upper alone, in 7; middle and lower, in 3; middle and upper, in 2; upper and lower, in 3. In the left lung, entire organ in 10; lower lobe in 16; upper lobe in 6. In the cases of double pneumonia, it was most often the lower lobes which were affected together, but in three instances the lower lobe of one lung and the upper of the other were affected; in three cases both upper lobes; and in Case LXIX. the most extensive inflammation of both lungs occurred—the left was in a state of uniform red hepatization, with the exception of the anterior border, and the right in the stage of gray hepatization, except still smaller portions of the corresponding regions. Altogether, in 39 instances a lower lobe was involved, in 19 an entire lung, and in 16 the upper lobe.

Weight of lungs.—To estimate the amount of solid exudation, the lungs were generally weighed. The heaviest was in Case XLVIII., a man æt. 40 years, whose left lung, uniformly solid, weighed 2303 grammes, and the right, very congested and œdematous, 900 grammes. (The normal lung weight is between 600 and 700 grammes.) In eight cases the affected lung weighed about 2000 grammes, representing rather more than three pounds of solid exudate.

State of lung tissue affected.—In about one-half the cases, the inflamed area was in a state of red hepatization. In 30 per cent. there were regions

[1] Montreal General Hospital Reports, vol. i. Dawson Bros., 1880.

of gray hepatization with the red, and in 22 cases there was gray hepatization, either dry or passing into the condition of purulent infiltration.

State of uninvolved portions.—Usually the crepitant parts of the affected lung were greatly congested or intensely œdematous. The latter was invariably the case when the whole organ was involved, except the apex and anterior border, which then presented a condition of almost gelatinous œdema. The unaffected lung was generally congested and œdematous, particularly at the posterior part. It was not uncommon to find the anterior portions quite dry and bloodless, while the dependent regions were full of blood and serum. No doubt this is largely due to post-mortem subsidence. We do not always find extensive congestion or œdema in the uninflamed parts. Thus, in Case XXXII., in which the lower lobe of the right lung was hepatized, the upper and middle lobes were noted as "very dry and bloodless," whereas the left lung was œdematous, except at its anterior borders. So, also, in Case LVIII., a woman, æt. 50 years, with red hepatization of the left lower lobe, the upper lobe was crepitant throughout, dry on section, no redness, and no blood. The right lung was also crepitant (except a fibroid apex), dry, no œdema, and very little blood.

Air passages.—The bronchi generally contained a frothy, serous fluid—not often the tenacious mucus characteristic of pneumonic expectoration. The mucous membrane was usually reddened, rarely swollen. In the affected regions the smaller bronchi very often contained fibrinous plugs, and in twelve instances these were noted as very abundant and extending into the larger tubes of the inflamed region, forming perfect casts of the bronchi.

The *bronchial glands* were invariably swollen and succulent, occasionally very soft and pulpy. In no instance was there suppuration.

The pleuræ.—When the inflammation reaches the surface of the lung the pleura is inevitably involved, with the result, commonly, of a thin sheeting of exudate, perhaps of such delicacy that it produces only turbidity of the membrane. In only two instances the pneumonia was deep-seated, and did not reach the pleura; in every other instance this membrane was involved in a greater or less degree. In some cases the fibrinous exudate was extraordinarily thick and extensive, as in Case V., in which the right lung was uniformly solid, weighing three pounds six ounces, and every portion of the pleura was covered by a creamy fibrinous layer an inch in thickness.[1] In several cases there was copious serous exudation amounting to three or four pints. In six cases there was

[1] Specimen in the museum of McGill College.

extensive double pleurisy, with pneumonia on only one side. Case XV. illustrated how readily the inflammation could cross the anterior mediastinum and spread from the pleura of the left upper lobe to that of the right.

Among the more uncommon terminations of pneumonia, there were cases of abscess, gangrene, and fibroid induration.

Abscess.—When a lung in a state of purulent infiltration is examined, we wonder that softening and breaking down of the lung tissue is not a more frequent result of this process. In four instances there were definite small abscesses. In Case XXXIV., a woman, æt. 56 years, with gray hepatization of the right upper lobe, there was a small abscess cavity, the size of a walnut, with shreddy walls, in the interior portion of the lobe. The tissue about it was in a state of purulent infiltration. In Case XXXVI., male, æt. 60 years, with gray hepatization of upper half of left lung, there were in the central part of the upper lobe several spots of softening, the size of marbles, irregular, with ragged, uneven walls and purulent contents. In Case LXXVII., female, æt. 64 years, with almost uniform consolidation of left lung, the upper lobe was in a state of intense purulent infiltration, and there were in the middle portion several large abscess cavities communicating with each other, with ragged walls and purulent contents.

Gangrene.—In three instances this termination was met with. Case LIV., female, æt. 35 years, a hard drinker, was admitted with pneumonia of the left lung, which had existed for some days, during which she had been neglected and much exposed to cold. The lower lobe presented at its apex and extreme base signs of consolidation, but in the rest of its extent was represented by a large gangrenous cavity, occupied by shreddy and necrotic lung tissue and blood clots, the whole forming a stinking mass.[1] The walls were not defined, except at the lower part, where a separation between the sloughing and firmer lung tissue could be plainly seen. In Case LX., male, æt. 63 years, with pneumonia of the left lung, there was a spot of gangrene at the apex surrounded by dark consolidated tissue. Case LXXIV., male, æt. 50 years, a hard drinker for twenty years, was admitted supposed to be suffering with delirium tremens; had had convulsions before admission. Rigidity of muscles of arms, coma, and death thirty-six hours after admission. At apex of right lung was a gangrenous mass the size of a hen's egg, surrounded by greenish-black consolidated tissue. Suppurative meningitis of cortex.

[1] Specimen in museum of McGill Medical Faculty.

Fibroid induration.—The production of a chronic—so-called interstitial—pneumonia from the ordinary croupous form is, perhaps, the most rare termination of the disease. The following case is of special interest, from the fact that the man was under observation almost from the outset, and the induration was in patches and in an early stage: Louis Phillippe, æt. 58 years, a laborer, was admitted with cough and pain in the side. Had a chill five days before admission. Temperature 101° F.; pulse 106; respiration 26. Expectoration not bloody. Physical signs of pneumonia over right lower mammary, infra-axillary, scapular, and infra-scapular regions. During the first ten days in hospital patient made no satisfactory progress; temperature ranged from 99° to 103°; he was heavy and dull, not delirious; pulse weak, 100 to 120. Defective resonance in infra-clavicular regions on right side; in mammary region, a flat tympanitic note; behind, absolute dulness, feeble blowing-breathing; a few râles on deep inspiration. The note over right mammary was markedly tympanitic. Patient emaciating. No heart murmur; very little expectoration, muco-purulent, not bloody. On the twenty-sixth day he had a chill, and the temperature went up to 104°. No change in physical signs. Died at noon on the twenty-seventh day after admission. The right lung was uniformly solid, grayish in color, with recent pleuritic exudation, and the surface, on section, was bathed with serous fluid. On carefully inspecting the cut section, three features called for attention. In the first place, in certain regions the air-cells could be seen with their fibrinous plugs, of a very opaque white character, undergoing fatty change. This state existed in very considerable areas. Secondly, there were small localized areas densely infiltrated with pus, and breaking down into definite abscesses. The largest of these was about the size of a marble. And thirdly, in several areas of the lung there were spots which had a very translucent aspect, were firm, smooth, homogeneous, not granular, and had the look of recent connective tissue. In these areas a fibroid change was going on in the lung; the alveolar walls were thickened, and the fibrinous plugs filling the air-cells were undergoing transformation into a new growth of connective tissue.

State of the other organs.—Heart: Distention of the chambers, particularly the right, with very firm, tenacious coagula, is a very constant feature in pneumonia autopsies. The right auricle is usually very full, and a solid mould, capped usually with a buffy layer, can generally be removed with the extensions into the cava and many of its branches. I have seen a complete cast of the branches of the superior cava, even to the smaller vessels, and a mould of the inferior cava, including the

hepatic and the iliac branches. From the pulmonary artery there can be withdrawn, by careful manipulation, a dendritic clot representing the vessels of quite small calibre. In no disease, I think, are we likely to meet with such solid coagula—so firm and fibrinous; and on several occasions, when I did not know the nature of the case, the preliminary incisions for the right chamber have enabled me to make a shrewd guess as to the existence of pneumonia. In many instances the engorged state of the right side and condition of general venous stasis, suggested the possibility that a copious venesection might have relieved the overloaded chambers—and I have in several cases acted with benefit upon this suggestion. In extensive red hepatization the circulation in the inflamed area must be very much impeded, and the work of the right ventricle greatly increased. If we may reason from the experiments of Welch,[1] the collateral œdema which we have so much dreaded under these circumstances, has no existence; for he seems to show very clearly that to produce pulmonary œdema the blood pressure must be raised to a point very much beyond that which can be induced by the cutting off of certain territories of capillaries, however extensive, in a pneumonia. Yet there are difficulties in the way of explaining the œdema of the sound portions of the lung on the view which Prof. Welch holds—viz., that the left ventricle is first weakened or paralyzed and the continued action of the right gradually produces the engorgement and œdema. It seems natural to think that the engorged right ventricle would more quickly fail than the left, which is rarely found so full, and certainly has not to bear the strain and tension of the right chamber.

The left chambers usually contained coagula, but were rarely distended, never to the degree often met with in the right.

The tricuspid orifice was frequently found dilated, measuring from five to six inches in circumference.

Turbidity and moderate fatty change were sometimes noted in connection with the heart muscle. The endocarditis will be considered with the complications.

Spleen: Friedreich and others have called attention to the very general enlargement of this organ in pneumonia. The normal weight may be taken at about 170 grammes. In only 35 cases was the weight over 200 grammes—the heaviest, in Case LXXV., was 670 grammes. In 12 cases the weight was under the average; in Case LV. it was only 72 grammes. Usually the pulp was very soft; but in 4 cases the note is, "pulp firm, and cuts well." In many cases the weight was not

[1] Virchow's Archiv, lxxii.

recorded, but the note entered was either "normal" or "slightly enlarged."

Kidneys: In exactly twenty-five per cent. these organs showed signs of interstitial changes, being hard and fibroid, with adherent capsules and often small cysts. In eight cases there was marked parenchymatous swelling; in Case XXIII., chronic parenchymatous nephritis; in Case XXV., amyloid degeneration; and in Case XXXII., extensive fatty changes in the tubules.

Other diseases and injuries.—One case occurred in connection with diabetes and one with erysipelas. Three cases followed injuries, one a burn, and one came on in the course of a carbuncle. In all, the pneumonia was fibrinous and lobar. These cases of "contusions-pneumonia," as Litten terms this form,[1] are very interesting, and may come on after slight or severe injuries, or after operations.

Complications.—Pericarditis occurred in five cases. In two there was extensive double pleurisy with the pneumonia. In one there was endocarditis as well. Except in Case XCIII., a portion of lung contiguous to the pericardium was involved in each case.

Endocarditis: I have on several occasions called attention to our exceptional experience in this respect; though, indeed, a review of the literature shows that the occurrence of this complication in pneumonia is by no means infrequent. In 16 cases there was endocarditis, either of the simple or malignant types, most often of the latter. In five instances these were simple warty vegetations, and there were no special cardiac symptoms. In 11 cases the lesions were more extensive, usually of the ulcerative form, and the character of the disease was much altered, or even masked by this complication. Our cases bear out Bouillaud's suggestion that endocarditis most frequently complicates left-sided pneumonia, but in a review of 36 cases of endocarditis occurring in this disease, and in which the lung affected was mentioned, I find that in 20 it was in the right side and in only 10 the left, so that it seems doubtful if contiguity has anything to do with it.

Meningitis: In 8 cases there was meningeal inflammation, in 7 pia-arachnitis, and in 1 dura-arachnitis. In 5 of these cases there was also ulcerative endocarditis. Brief details of the cases may be given:

Case II., male, æt. 38 years. Red hepatization of upper lobe of right lung, extensive exudation at base of brain, in longitudinal sinus and along the Sylvian fissure.

Case LXVII., female, æt. 64 years. Gray hepatization of left lung,

[1] Zeitschrift für klin. Medicin., Bd. v.

with small abscess cavity; the under surface of the dura mater of left hemisphere covered by a sheeting of recent lymph, which could be detached in flakes. No lymph beneath the arachnoid or at the base.

Case LXXXIV., male, æt. 50 years. Gray hepatization of right upper lobe and a spot of gangrene. Intense congestion of cortical meninges and exudation of lymph in patches over the frontal and occipital lobes; none at the base.

The following cases were associated with endocarditis:

Case XXVIII., female, æt. 29 years. Upper half of right lung hepatized. Mitral ulcerative endocarditis. Meningitis of the cortex. A thick flake in the neighborhood of the left fifth nerve, and another about the optic chiasm.

Case L., male, æt. 40 years. Lower lobe of right lung. Extensive endocarditis of mitral and aortic valves. Thick, creamy lymph over sides and upper surfaces of the hemisphere. None at the base.

Case LXXIX., male, æt. 43 years. Lower half of left lung affected. Endocarditis, mitral and aortic. Meningitis of the left hemisphere, with exudation of lymph over the frontal and parietal convolutions. None at the base or on the right side.

Case LXXXVII., male. Double pneumonia; right apex. Ulcerative endocarditis of mitral. Cortical meningitis. No lymph at the base.

Case XCIX., female, æt. 19 years. Red hepatization of central part of right lung. Endocarditis of anterior segment of mitral valve. Meningitis of cortex—both hemispheres.

The complication of meningitis is one of the most serious that can occur in pneumonia, and it would appear, in a considerable proportion of the cases, to be associated with ulcerative endocarditis. We may suppose the inflammation of the heart and the meninges to be induced by a common cause, or, what would appear likely in many cases, the meningitis is embolic in origin, for it also occurs in malignant endocarditis, unassociated with pneumonia. In twenty cases of meningitis in this disease, only fifteen occurred with pneumonia. The infective material may possibly be derived directly from the infiltrated lung-tissue, and carried off by the pulmonary veins. We know that occasionally large emboli may be derived from this source, as in a case of pneumonia occurring at the General Hospital in 1879, in which, during the progress of the disease, and not associated with endocarditis, there was embolism of one femoral artery and gangrene of the leg, necessitating amputation above the knee.

The inflammation in these cases is almost always cortical, and the

chief symptoms are initial delirium, then stupor and coma, sometimes rigidity of the muscles.[1]

Croupous colitis: In Cases III., XXVIII., XLII., LXXXV., and XCIX., this unusual complication was met with. In Case III. the cæcum was covered with a thin layer of adherent lymph, and scattered throughout the colon and sigmoid flexure there were numerous elevated patches of lymph, about the size and shape of rupia-crusts, which on section were found firmly attached to the mucosa. In this instance, the process was very extensive and the patches much thicker than in any subsequent case. More often there is a thin, flaky exudation, involving only the surface of the mucous membrane. In none of the cases was there ulceration.

Croupous gastritis: In Case IV. the stomach and duodenum were found "greatly distended with gas. The mucosa was pale, except about the fundus, where, just to the left of the cardia, there was an extensive area of croupous inflammation, represented by a thick, adherent, grayish-white exudate, covering an area 12 by 8 cm. Beneath the mucosa the membrane was deeply injected."

This paper is meant to be merely a statement of facts, a record of observations upon a common and well-known disease. As opinion is still divided as to the general or local nature of pneumonia, it is interesting to note how strongly the evidence from morbid anatomy tends toward the former view. The frequency of the occurrence of various consecutive inflammations finds a parallel only in some of the specific fevers.

While this paper has but a trifling value as a pathological contribution, to the writer, as doubtless to the students who performed the autopsies under his direction, the careful study and observation of the cases upon which it has been based have been of the greatest service. In the investigation of disease a knowledge of the morbid phenomena observed during life and of the organic alterations found after death are inseparable. The teaching of the post-mortem room must supplement and illustrate the lessons of the ward, and, as Bichat says, it is neither from the one nor the other, but from both, that "la veritable pathologie" can be gained. *April* 23, 1885.

[1] The literature of meningitis in pneumonia is scanty. From Vulpian's clinic a good thesis was written by Surugue (1875). In the St. Thomas's Hospital Reports, 1878, some cases are given by Greenfield, and there are valuable references in that storehouse of clinical material, Traube's Gesamelte Abhandlungen.

17. *Specimens from a case of pneumonia.*

Exhibited by Dr. M. H. Fussell.

The subject from whom the specimens were removed was a child, æt. 7 months, with the following history: mother is syphilitic, was under treatment for perforating ulcer of palate at time of death of child. Had previously had a syphilitic iritis. I had treated the child itself for snuffles and a syphilitic eruption. On the 2d of May child suddenly taken with convulsions. He had three more before I saw him on the 3d.

At first visit, aside from a little dulness, there was nothing wrong that could be discovered. Slight rise of temperature, 99.5°. No eruption. No lung symptoms. Pupils were normal. He was put on iodide and bromide of potassium, and continued to have convulsions until midnight of same day, passing through eight in all.

May 4. Temperature normal. Still nothing abnormal noted.

5*th.* Temperature had risen to 101.8°. Respiration hurried; a few fine râles noticed over both chests.

6*th.* Respiration 60, pulse 160, temperature 100°. Physical signs of a capillary bronchitis.

8*th.* Blowing-breathing noted over right chest posteriorly, some dulness in same position. A friction sound was also noted. The crepitant râle was absent.

10*th.* Temp. 103°. Blowing-breathing and dulness over right chest, especially posteriorly. Child looked remarkably well, was bright and took notice of parents. When sleeping he had an "expiratory moan."

13*th.* Lay in stupor all day. Pulse 180. Respiration jerky, and 80 per minute. Died at 8 o'clock on the 14th.

Post-mortem examination.—On opening thoracic cavity the lungs had not receded, but almost met in the median line. The edge of the lung was very light in color. Left pleural cavity contained a small amount of purulent liquid. Lung was connected to chest wall by a few recent adhesions easily broken-down. Right pleural cavity was almost entirely obliterated. On separating the lung from the chest wall the latter had the appearance of an abscess cavity. There was no liquid exudate in this side. Between the base of the heart and the overlying lung was a patch of puriform membrane the size of a nickel five-cent piece. The entire right lung, with the exception of a strip a half inch deep extending along the anterior edge, was consolidated. The *pleura* was converted into a puriform membrane one-half line in thickness, over the entire

lateral part of the lung, covering a surface of about two and a half by three inches. A strip of similar membrane was along the posterior edge. All the lobes of the lung were united by membrane; there was also a patch on the diaphragmatic surface. On section of the consolidated portion of the lung a purulent liquid exuded from severed bronchioles. The anterior crepitant edge was filled with a frothy liquid.

The left lung was crepitant throughout, except a small portion of the base. Pleura converted into a thin membrane in different portions.

The *pericardium* was filled with a serous fluid—both surfaces roughened. Over the base of the heart, just under the position of membrane between the lung and the pericardium, was the seat of greatest amount of disease, as though this had been the starting-point of the pericarditis.

The lower surface of the left ventricle of the heart was covered by a thin puriform membrane which was easily detached.

Heart: The right ventricle was filled with a chicken-fat clot which extended into both branches of the pulmonary artery. The left ventricle contained a clot which extended down the aorta two inches. Valves all normal.

The *abdominal viscera* were all normal.

The *head* was not examined.

The microscope showed the consolidated portion of lung to be the seat of a typical catarrhal pneumonia. The alveoli were partially or entirely filled with epithelial cells.

The left lung showed a microscopic picture that might be expected in a case of capillary bronchitis.

This case interested me from both its clinical and pathological aspects.

Clinically, as to what relation the convulsions had to the lung trouble. It was not until the third day after the first convulsion that any evidence of lung trouble appeared, and until that time the patient was not apparently seriously ill between the convulsions. The lung lesion was not *overlooked* until the third day, because I had made a careful examination at each visit. At first I supposed it likely that the convulsions were due to the syphilitic taint, because of the absence of anything else to explain them, but the subsequent history of the case, I think, proved that they actually marked the beginning of the lung trouble. The absence of any cerebral symptoms in the progress of the case goes to prove this.

Pathologically, the case is interesting from the unusual amount of tissue involved in the pneumonic process, for it is the rule in cases of catarrhal pneumonia to have scattered patches of consolidation instead of, as in this case, almost an entire lung. It is also interesting to trace the

sequence of the lesions found. Doubtless, the first trouble was a bronchitis, this was soon followed by the pneumonia, which in turn gave rise to the pleuritis. The pericarditis doubtless arose from the irritation caused by the inflamed portion of pleura overlying the base of the heart, for immediately under this spot is the seat of the greatest disease in the pericardium. So here the disease spread both by continuity and contiguity of tissue. *June* 11, 1885.

V. THE GENITO-URINARY APPARATUS.

a. KIDNEYS, BLADDER, ETC.

1. *Secondary tuberculosis of the bladder, urethra, kidney, and suprarenal body.*

Exhibited by Dr. W. E. Hughes.

Ida G., white, æt. 19 years, had suffered with the usual symptoms of phthisis for about nine months before she came under observation. Her father and a sister had died of phthisis, and she had always taken cold on the slightest exposure. When first seen she was standing leaning over the back of a chair suffering the most agonizing pain in the region of the bladder. Desire to urinate was constant and irresistible, and the passage of the small quantities of urine gave rise to such suffering that she would shriek and almost faint. Till two weeks previous there had been no trouble with the urine, then the pain began, slight at first, and became gradually more and more severe. She had passed frequently masses of clotted blood with great suffering. Under anodynes the pain became less, and an examination of the bladder showed it to be much contracted, with roughened walls; examination also brought on a slight hemorrhage. The urine contained nothing abnormal except blood and pus. Under the continued use of anodynes the pain decreased and finally disappeared. After the cessation of pain the blood disappeared from the urine, but was replaced about two months afterward by a small quantity of albumen and a few granular tube casts. About this time œdema began in the ankles and gradually involved the whole of the lower extremities. The tissues finally became so distended that her legs were utterly useless. The urine never contained more than one-tenth of its bulk of albumen, and the tube casts were always few in number. She died of asthenia four months after coming under observation.

Autopsy, fourteen hours after death.—Extensive degeneration of lungs. Liver was extremely fatty, being of a uniformly yellow color with no distinction whatever between its lobules. The bladder was small and firmly contracted, its walls thickened, its inner surface roughened, rugose, papillomatous, its mucous membrane thickly studded with tubercle granulations. The substance of the right kidney contained numerous

gray miliary tubercles, its pelvis was dilated and presented the same appearance as the inner surface of the bladder. The corresponding ureter was as thick as an index finger, its walls firm, hard, infiltrated with tubercular deposit, its mucous membrane in the same condition as that of the pelvis of the kidney. The right suprarenal body retained none of its original structure, it was a mass of cheesy tubercles firmly adherent to the kidney. The left kidney, as well as the other organs, was normal. *January* 24, 1884.

---

2. *Two cases of suppurative nephritis.*

Exhibited by Dr. W. E. Hughes.

In both of these cases the kidney lesion had been preceded by cystitis; in one, of some months standing, in the other, of more recent origin. In both of them there was a history of gonorrhœa, and in one, well-marked symptoms of stricture of the urethra; in this case the cystitis seemed to have been originated by septic matter carried into the bladder on a catheter, although a tendency to inflammation had most likely been developed by the long-standing stricture. In one case the kidney lesion may have originated in emboli derived from a suppurating surface, though this is unlikely from the fact that no such emboli were found elsewhere.

Case I.—A male, æt. 55 years, had locomotor ataxy for years. He had had gonorrhœa, but following it no change from the normal in urination, so that it is scarcely probable that there was any stricture of the urethra. Six months ago, as the result of exposure, a cystitis developed, with the usual signs of frequent passage of urine containing large quantities of mucus and pus; there were no tube casts and no more albumen than could be accounted for by the pus corpuscles present. After being under observation about two months large bedsores developed over the sacrum and trochanters; they soon induced a septicæmic condition which rapidly produced death. At the autopsy the nervous lesions characteristic of locomotor ataxy were shown. The urinary bladder was dilated, its walls thickened, its inner surface crossed in every direction by bands of hypertrophied muscular tissue, the mucous membrane thickened and slate colored. In the kidneys were numerous cone-shaped masses in which the tissue of the kidney was broken down and infiltrated with pus and the bloodvessels filled with micrococci. The remainder of the

kidney tissue appeared healthy. There were no abnormal appearances about the pelvis and ureters.

Case II.—A male, æt. 72 years, had several attacks of gonorrhœa and symptoms of urethral stricture lasting over thirty-two years. The stricture had been dilated several times, but during the six months before he came under observation it had been neglected and had begun to grow troublesome. When first seen his urine was normal, and there were no signs of cystitis. He had been failing in health for some time and was much troubled by a cough. Physical examination showed breaking down of the lung structure at the apices. A few days after coming under observation his nose bled so freely that it became necessary to plug his posterior nares. Soon after this, his stricture almost preventing the voiding of urine, a catheter was passed into the bladder. The next day he complained much of pain and tenderness in the region of the bladder, and the urine, which was passed every few minutes, contained large quantities of blood, pus, and mucus. The acute symptoms were soon relieved, but the urine continued loaded with mucus and pus; in fact, it was often so stringy that it was only with the greatest difficulty that he could pass it. It never contained casts nor more albumen than could be expected when there was so much pus and blood. He died two months after he was first seen. The autopsy showed tuberculosis and disintegration of the pulmonary tissue. The kidneys were identical in appearance with those in Case I., with the addition that their pelvis contained numerous particles of uric acid. The cavity of the bladder was small, its walls thickened and hypertrophied, the mucous membrane dark red, thickened, softened, and thrown into folds.

Dr. Tyson said that the relation of bladder to kidney trouble was as yet pretty much guesswork, although it is certain that in a prolonged cystic disease suppurative interstitial nephritis will sooner or later arise. But rarely can we state from an examination of the urine that renal disease has supervened. He happened, however, now to have under his care two cases of cystitis with renal disease in which it was comparatively easy to determine the presence of the latter along with the former by reason of the presence of compound granular cells and fatty tube casts in addition to pus. The character of the casts pointed rather to tubular nephritis than to the interstitial form, contrary to the ordinary belief with regard to these cases. *February* 28, 1884.

3. *Cystic degeneration of a fœtal kidney.*

Exhibited by Dr. G. E. de Schweinitz.

I desire to present this evening an example of cystic degeneration of a fœtal kidney. The specimen was removed from an eight months' old fœtus brought to the University Museum by Dr. George Horn, of this city. The fœtus in question, in addition to this anomalous condition of its kidneys, presented also other interesting abnormalities, having, at the position of the posterior fontanelle, a large meningocele; further, an imperfect development of the external genital organs; and last, but not least remarkable, six fully developed fingers upon each hand, and a similar number of equally fully developed toes upon each foot. Upon opening the abdominal cavity both kidneys were found to present appearances of the one I exhibit to-night. It is enlarged, having a length of about four and a half inches, and a breadth of nearly three, or about the size, or a little greater than the size of a normal adult kidney. The capsule can be detached with a moderate degree of ease, and the organ is surrounded with its usual envelope of perinephritic fat. Both upon the free and also the cut surface are seen numerous cysts, varying in size from a small marble to a split pea, or even smaller; each cyst having a moderately firm capsule, and upon incision discharging fluid contents. Very distinct lobulation of the kidneys is a marked feature. It is perfectly plain that we have here a specimen of what is referred to by systematic writers upon pathology as congenital renal cysts. Rindfleisch speaks of kidneys of this sort producing death to the child either during birth or immediately after by pushing up the diaphragm, and thus occupying space necessary for the movements of the lungs. He further indicates that the Malpighian corpuscles constantly prove the points of departure for these cysts, although degeneration in the continuity of a urinary tubule may also contribute in the formation of the cystoid change. Both Virchow and Rindfleisch consider "an intercalation of a mass of connective tissue between the renal calices and renal papillæ" as a cause of this congenital cystoid degeneration. A rather hurried microscopical examination of this specimen reveals the following points: Nearly a total absence of any true renal structure, the greater mass of the organs being composed of connective tissue through which are scattered numerous free nuclei; cysts, the walls of which are lined with a single layer of cubical epithelium, and in such, which evidently arise from Malpighian corpuscles,

the remains of the vascular tuft are sometimes seen, the wall having been drawn back from the vascular coil, as Rindfleisch puts it; quite large vascular channels and bloodvessels, usually filled with blood-corpuscles, and finally, decided areas of fatty infiltration; the fat cells having inserted themselves between the connective tissue. Further, fuller microscopic examination of the organ may possibly discover other and different changes which have not been described. Joh. Klein demonstrated renal cysts in an adult case to arise from degenerated Bowman's capsules, which contained cholesterine crystals, fat granules, and calcareous grains, or, as he expressed it, "renal sand." Such conditions were not discovered in this case.

Dr. Tyson said that it was remarkable how long persons with this congenital cystic trouble will live. Adults are found post-mortem with kidneys the size of a fœtal head, with cysts as large as marbles, and apparently no renal tissue left, conditions which have evidently existed for years. *February* 28, 1884.

---

4. *Tumor of bladder; retention of urine; false passages made by soft catheter; septic fever; death from exhaustion.*

Exhibited by Dr. J. H. Musser.

J. M., æt. 84 years. In early life was unusually robust, and active in his calling as gardener. The latter ten years of his life have been sedentary, chiefly on account of a large leg ulcer and varicose veins. Moderate user of alcoholic stimulants; smoked to excess. Never confined to bed from any illness. Family history good. Six months previous to coming under my care he experienced difficulty in micturition. This gradually increased until, finally, the effort to relieve his bladder had to be continued one-half hour before being successful. I saw him the fifth day of complete retention of urine. After some difficulty I passed a soft catheter and drew off about one-half the contents of the bladder, this organ having reached to the umbilicus. The operation had to be repeated twice a day until his death. It was noticed that the instrument twisted in its course. For one week chills and irregular fever followed the passage of the catheter. Death occurred from exhaustion three weeks after the retention took place. It may be noted that in the rectum by the finger a growth was discovered corresponding to the prostate gland. There never was any vesical hemorrhage.

Autopsy.—Heart, liver, kidneys, and bladder alone examined. The

rigor mortis was marked, the body not emaciated. The man was very large, and yet his heart was unusually small, especially when the condition of the kidneys is taken into consideration. They were cystic, and the seat of interstitial inflammation. Neither organ was weighed, and they were not allowed to be removed. The liver was removed for examination. It was much enlarged, its walls thin and markedly "ribbed;" its mucous membrane not inflamed. In the trigone corresponding to the middle lobe of the prostate a tumor, soft, readily titillating, with a flat base and pointed apex, was seen. It grew directly into the mouth of the ureter, completely occluding it. It was very red, but not ulcerated. The catheter had passed through the floor of the urethra one-half inch from the vesical terminus, and emerged in the bladder to the right of the base of the tumor. I purposely have not made any sections, as I desired to show the growth in its entirety. I suggest its reference to the Committee on Morbid Growths. I may say that, on account of the above named physical characters, the tumor appeared to be a papilloma.

Report of the Committee on Morbid Growths: "Your committee reports that this specimen is a hypertrophy of the third lobe of the prostate gland." *November* 13, 1884.

---

5. *Hypertrophy of prostate gland; chronic cystitis; cystic and cirrhotic kidneys; death from exhaustion.*

Exhibited by Dr. J. H. Musser.

C., æt. 60 years, under the care of Dr. R. M. Girvin. In good health until 1879, when he began to suffer from pain at the neck of the bladder with frequent micturition, which soon developed into a cystitis. From that time until his death he suffered from constant pain and irritable bladder, with recurring attacks of cystitis; the urine presented the usual changes of that disease. Two or three times he passed a little blood. After a year's illness catheterization, which had to be performed occasionally, became the rule. On account of the pain morphine had to be given in increasing doses until death. The combined influence of his depressing disease and the morphia habit rendered Mr. C. unfit for any duties; the nutritive processes failed, and death resulted, February, 1884, from exhaustion.

On examination, eighteen hours after death, rigor mortis was well

marked, the body was emaciated, the face swollen in appearance. Abdomen alone examined. The stomach and intestines presented the usual appearances found when death is from long-continued exhaustion. The kidneys were granular in appearance, very hard, the capsules were adherent, the cortical portions constricted. On the surface numerous small cysts were seen in both organs. They were not weighed but both were atrophied. The liver was fatty; the lumbar lymphatic and mesenteric glands normal. The bladder was small and its walls much thickened and somewhat ribbed. At the base the mucous membrane was congested but not ulcerated. The prostate was much enlarged, very hard, and encroached on the cavity of the bladder.

The interest of the case centred in the microscopical examination of the prostate, for, ten years previous to the present illness, Dr. Girvin had removed a small tumor, probably a fibroid, from the patient's head, while shortly afterward a persistent tendency to ulceration on the femur, recurring for a year, was only checked by frequent applications of nitrate of silver. Then there was a marked tendency to carcinoma in his family; with other evidence, that of his sister's history, she having had mammary carcinoma. Sections of the tumor showed the histological appearances of a chronic inflammation with hypertrophy of the gland.

December 11, 1884.

---

6. *Alveolar sarcoma of the kidney.*

Exhibited by Dr. M. Longstreth.

The patient, J. E., æt. 9 months, was first under the care of Dr. McOscar, to whom I am indebted for the specimens and this history, suffering from an attack of summer complaint. The patient was at that time three months old, and had been ill for a week or two. He was in a state of great emaciation, and upon examination of the abdomen a swelling was found in the right flank. The little patient recovered from the bowel trouble, but the general condition did not materially improve. During the remaining six months of life the child was only occasionally under observation, and at those times suffered from paroxysms of pain apparently in connection with the tumor. The bulk of the tumor, as felt through the abdominal wall, did not seem to increase greatly up to his death. The urine was not carefully inspected. Three days before death the pain increased to great violence and in this condition death came.

The post-mortem examination showed the enlarged right kidney more firmly adherent to the posterior abdominal wall, and to the ascending colon and mesentery, as well as portions of the small intestine attached to its anterior surface. The diseased organ weighed fifty-two ounces, and presented itself as a rounded, slightly oval mass, regular in outline, smooth of surface, and with a moderately firm, elastic consistence. The capsular surface was of pretty dense, shining whiteness, with conspicuous small vessels passing over it. On section—which measured three and one-half by three inches in the two diameters—the tissue presented a very varied appearance. In parts it was of a dense white, perfectly homogeneous aspect; in others, the pinkish-white mass showed streaks of yellow with numerous small spots of red, and there were also large, blood-red areas. In other parts, the tissue was breaking down into cysts, of which several large ones were present, the largest the size of an English walnut. The cysts were all situated on the periphery of the mass, but they did not cause any protrusion of the capsule. At the upper extremity of the mass there was found a portion of kidney tissue not invaded by the new formation. On section, this portion occupied about a half inch of the long diameter of the mass and was seen to be separated from the new growth by a thin partition of connective tissue; externally it showed itself like a lobule of kidney, fitting like a cap on the spherical tumor, as does the suprarenal capsule on the kidney itself.

The *microscopical examination* showed the new formation to be a small, round-celled sarcoma. The greater portion of all sections presented cells nearly rounded in figure, embedded in a perfectly homogeneous basis substance. The uniform area of cells was, however, interrupted by streaks of spindle cells, running in narrow bands, enclosing greater or less areas of round-cell tissue. These circumscribing bands of spindle cells sometimes formed circular areas looking like the cross-section of a tube; in other places the bands pursued a very tortuous course, resembling the outline of a twisting, undulating tube cut in a longitudinal direction. The bands of spindle cells were never of great breadth, rarely more than four or five spindles. The spindle cells were not regularly or closely fitted, but were embedded like the round-cell elements, in a homogeneous basis substance. In the spindle-cell bands there were occasionally seen fine capillaries, filled with red blood-corpuscles, which sometimes ran along for a considerable length; many other capillaries were seen cut transversely or obliquely, also in the spindle-cell tissue. Many areas of hemorrhage were visible. In many places a scanty, fibrillar tissue, with various shaped nuclei, oval, angular, and spindle, was seen. This tissue was thrust in and filled the interstices between the

areas of round cells, circumscribed by the spindle-cell tissue. Thus, in the section one passed from areas of round cells to the narrow bands of circumscribing spindles, and then into fibrillar tissue, with open meshes apparently without any intercellular basis substance. The whole picture resembled the cortical portion of the kidney, transformed by the presence of a new growth; the lumen of the convoluted tubes, greatly enlarged, was filled with a round-celled homogeneous basis substance tissue, the basement membrane of tubes transformed into spindle-cell bands, and, finally, areas of hyperplastic intertubular connective tissue, in which, or along the basement membrane of the tubes (spindle-cell bands), ran the intertubular capillaries. The left kidney weighed five ounces. On section it presented a normal aspect; the capsule separated easily, was not thickened, and the surface of the kidney remained smooth. The microscope showed no alteration of its tissues. The liver was large, smooth, blunt-edged, pale; under the microscope a very high degree of fatty infiltration was found. The other organs showed nothing especial to note. No secondary new formations were found. *January* 18, 1885.

---

7. *Pyelonephritis and chronic parenchymatous nephritis in the same patient; complicating cystitis.*

Exhibited by Dr. J. Tyson.

E. D., a prostitute, æt. 25 years, white, was first admitted to the Philadelphia Hospital September 10, 1883. She was at that time suffering from diarrhœa, and stated that she had previously passed blood—although apparently none was passed after admission. She had no symptoms which attracted attention to the urinary organs, and no examination of the urine was made. The history of the case at present attainable does not show whether or not she had had gonorrhœa. Her diarrhœa disappeared under treatment, but she regained strength slowly. She was discharged October 4th, apparently in fair health, but was readmitted on October 25th. She now presented œdema of the legs and face, and an examination of the urine made about this time disclosed the presence of pus. She complained of pain in the lumbar region and in the head, and was much debilitated. The treatment was directed to warding off a threatened uræmia. The dropsy disappeared, but her other symptoms progressively increased until death relieved her. She died with symptoms of uræmia.

Autopsy.—December 2, 1883. Nothing noteworthy in external appearance. Slight pleuritic adhesions, thoracic organs otherwise normal. Abdomen—peritoneum normal; liver normal; spleen not examined. Kidneys: left, typical large fatty organ; right, swollen to more than twice its normal size; when opened found to present a marked pyelonephritis with great distention of the pelvis, the calices filled with pus —partly fluid and partly inspissated. Bladder was in a condition of chronic cystitis. Cause of death, pyelonephritis with large white kidney.

Dr. Tyson said that the chief interest attaching to the specimen lay in the association of those two very opposite conditions, apparent pyelonephritis, or suppurative interstitial nephritis, with chronic parenchymatous nephritis. The former condition is a well-recognized result of cystitis, the latter not. He had never before met these conditions in association. Usually, as a result of a long-continued cystitis, however induced, we have a suppurative nephritis of one or both kidneys, but never, so far as he knew, suppurative nephritis. He thought the most reasonable explanation of the association was that of coincidence—that there had existed previously perhaps a parenchymatous nephritis; that upon this a cystitis had supervened, and upon this a pyelonephritis. He said that he would like to ask the members whether they had ever found association of these two varieties of diseased kidneys with cystitis.

Dr. Formad thought that he had seen one such case, but there was no history.

Dr. Osler said that the condition of this kidney is not infrequently met with in persons dying of intercurrent affections, and that he should not interpret the case as previous speakers had done. The kidney disease was probably of many years' duration, the cystitis was secondary to it, and the other kidney affected with parenchymatous nephritis had become subsequently diseased. It is well known that the ordinary scrofulous kidney, with pus in the urine, etc., often lasts for many years, ending in general tuberculosis, or inspissation of the pus. He would like to ask how long had pus been observed in the urine, the state of the bladder, and whether there were other findings of tuberculosis in the various organs.

Dr. Tyson replied that he was in possession of no definite facts as to the duration of pus in the urine. The case had been under observation for only three months, and certainly pus had been detected two months before her death. *January* 22, 1885.

8. *Organs from a case of parenchymatous nephritis, which was accompanied by intestinal ulcerations and pelvic abscess.*

Exhibited by Dr. H. M. Fisher.

Elizabeth H., æt. 32 years, widow, colored, was admitted to the Episcopal Hospital February 17, 1885. I am indebted to the resident physician, Dr. O. Hopkinson, Jr., for the following notes of the case:

She has had three children. Menstruation was regularly performed until one year ago, when it appears to have ceased. (The patient's mind was very dull, and it was with difficulty that any facts were elicited from her with regard to her previous condition of health.)

She had been able to work until one month ago, when she was suddenly seized with great weakness, diarrhœa, and high fever, followed by profuse sweating, which prostrated her and left her helpless. Upon admission she was extremely weak. There was complete motor paralysis of the left arm and partial paralysis of the left leg. No facial paralysis was noticed and no strabismus.

There was pretty general anasarca, but the œdema was most noticeable in the dependent portions of the body, such as the left arm and leg, the patient lying chiefly upon her left side. There was much diarrhœa and the passages were very offensive. There was also a very profuse greenish-white vaginal discharge.

The tongue was clean; the abdomen tympanitic. Hepatic dulness began in the fourth interspace in the mammary line and extended to the seventh rib. There was a faint basic systolic murmur audible. At the apex the first sound had a flapping character. The urine was pale, had a specific gravity of 1.008 and contained albumen in considerable quantity. Under the microscope fatty and pale granular casts and pus cells were seen. During the remainder of the time she remained under observation (about ten days) her condition changed very little. The diarrhœa was held in check, to a certain extent, by astringents, though she still continued to have two or three large watery, blackish stools daily. The day before her death I noticed a double basic as well as a double mitral murmur.

It was noticed that her heart continued to beat fifteen minutes after all sign of respiration had ceased. She had been taking for twenty-four hours tr. digitalis gtt. xxxv every four hours, which may, perhaps, have induced this result.

Post-mortem examination, thirty-six hours after death.—The skull was very thick, measuring seven-sixteenths of an inch in the frontal and one-

half of an inch in the occipital region. The veins were very much enlarged and there were some capillary hemorrhages in the pia.

The left lateral ventricle contained one-half drachm of bloody serum No clot or embolus detected.

Right pleural cavity contained six fluidounces of clear serum, the left still less.

Lungs: Lower halves of all lobes showed intense congestion, and upper portions free (hypostatic). The lungs crepitated throughout.

Heart: Pericardial cavity contained about one-half ounce clear serum. White firm fibrinous patch of the size of a dime at apex of heart. Right auricle contained large chicken-fat clot and was much dilated, and there was a clot adherent to the tricuspid valve. The right ventricle was also somewhat dilated. The left ventricle contained black fluid blood. The mitral valve admitted two fingers easily and appeared by hydrostatic test to be not thoroughly competent. The aortic valve was not competent and its leaflets were thickened. The aorta appeared also thickened and atheromatous. Apparently some marks of congestion of endocardium at valvular orifices, but no vegetations anywhere seen. Heart muscle soft, possibly partly in consequence of commencing decomposition.

Subcutaneous fat of abdomen about one-half inch thick; omentum and mesentery were also loaded with fat. *No peritonitic adhesions* were anywhere visible in the upper portions of the abdominal cavity.

Small intestine showed throughout its entire extent very decided hyperæmia, and was filled with black fluid fecal matter.

The ileum was of a reddish brown hue and showed intense congestion, and about three feet from the ileo-cæcal valve there were several irregular ulcers extending down to the muscular layer. There were clots still adherent to the surface of several of these ulcers. The largest of the ulcers were about one-half an inch in length; there were also numerous minute round ulcerations.

Peyer's patches and the solitary glands did not appear to be involved in the ulcerative process. Nor was there any marked involvement of the mesenteric glands. The mucous membrane of the ileum was roughened and eroded.

The *right kidney* weighed eight and one-half ounces; its capsule was non-adherent. Upon section cortex and medullary portions had about normal relations as to thickness, but the tissue was of a dull yellowish-white hue, to which the pinkish hue of the pyramids stood out in marked contrast.

The *left kidney* weighed seven and one-half ounces and presented the same morbid appearances.

The *stomach* showed no marked pathological changes.

The *spleen* weighed only three and one-half ounces, and seemed unusually firm and dry.

The *liver* appeared rather larger than normal, pale, and apparently fatty, and showed areas of congestion. In none of these organs were any infarctions visible.

The *gall-bladder* was much distended with bright yellow bile.

The *uterus* and *vagina* showed intense congestion of their mucous lining. The uterine cavity was markedly dilated and filled with creamy pus. Behind the left broad ligament an encysted collection of pus was seen, which appeared to have been formed in a pouch of the Fallopian tube (pyosalpinx). Both ovaries and Fallopian tubes are enveloped in false membrane and the uterus is adherent to the bladder and the rectum through pseudo-membranous exudations.

This case presents, I think, many interesting points for study. Bartels, in *Ziemssen's Cyclopædia*, refers to intestinal ulcerations occurring in the course of parenchymatous nephritis as a consequence of œdema of the submucous layer of the intestine. In this case, however, I was unable to detect any œdema of the intestinal parietes—the mucous membrane looked rather as if it had been acted upon by some corrosive poison. This ulceration might, I think, be due to the general atheromatous condition of the arterial system, the irritant in this case being perhaps an accumulation of effete products (urinary salts?) in the blood. The question also naturally arises whether this ulceration might not have been due to septic infarctions, originating from the purulent focus in the pelvic peritoneum. Opposed to this view of the case was the absence of general peritonitis and the absence of splenic changes pointing to a septicæmic process; the absence, too, of any apparent infarctions of other organs. Though there was an obscure history of a previous febrile attack the patient's temperature was normal or subnormal while in the hospital. The hemiplegia was undoubtedly due to the plugging of one of the cerebral vessels, as no clot was found in the brain, and a more careful examination would probably have revealed such an embolus.

March 12, 1885.

---

9. *Primary tuberculosis of the kidneys.*

Exhibited by Dr. M. H. Fussel.

The reporter never saw the subject alive from whom the specimens were removed, having performed the post-mortem examination for a friend.

Case of Edward B., æt. 40 years, single, by trade a paper-maker. In following his calling he was forced to stand in a dust-laden atmosphere from morning until night. He worked at this trade from boyhood steadily, with the exception of four years during the late war. His grandfather died of bladder trouble; his father died of apoplexy; his mother, brothers, and sisters are all living and healthy. He was always a robust man; his weight was 170 pounds, and he never had any serious illness; he had gonorrhœa during the war. Four years ago while in camp he made a misstep and fell. The next morning he passed much blood in his urine; previous to this he was perfectly well. From this time until death he was troubled with slight pain in his loins and with frequent micturition; his urine was sometimes bloody, sometimes milky. The patient's bladder finally became incontinent and he was forced to wear a urinal.

The patient's general strength did not seem to suffer until the past six months, when he began to lose flesh and strength, and at death he was much emaciated. He had never had any cough or diarrhœa. Two weeks before death he began to vomit; this increased in frequency until he was unable to retain anything on his stomach. Just before death breathing was rapid and full. The patient was very restless, vomited, and passed urine freely. The pupils were dilated.

Dr. Fussell examined the urine several times. The specific gravity ranged from 1.002 to 1.010. Large amounts were passed. Albumen was present. The microscope showed pus, blood, and granular epithelium. Many of the cells were irregular in shape, the pyramidal form predominating. No casts were found at any time. Unfortunately, a critical physical examination of the patient was never made. At different times surgeons had sounded him for stone and had failed to find any.

Post-mortem examination.—Nothing especial noted on the exterior of the body.

Thorax: Heart about normal in size. The muscle looked normal, and the cavities contained a large amount of fluid blood and currant-jelly clots. A small decolorized clot on the left side. Valves normal.

Lungs: Both pleural cavities obliterated. The pleuritic adhesions were tough, the lungs being with difficulty torn from the cavity. In places the pleura was much thickened. The surface of both lungs was studded with miliary tubercles. On section the lung substance was crepitant and studded with myriads of miliary tubercles. No caseous masses or cavities were found in either lung. The bronchial glands were enlarged, not caseous.

Abdomen: Viscera in normal position, peritoneum free from tubercles and of a healthy look.

Liver of normal size and color. Over the surface a few stellate cicatrices noted, but no tubercles seen on the surface nor on section of the organ. The bile-ducts free.

The *stomach* contained greenish-black fluid, the mucous membrane of a greenish color corresponding to the contained fluid. The rugæ were much enlarged, especially at the cardiac end. Near the pylorus there was a small injected spot.

Kidneys: The right measured six inches in length and three inches in width, and was of a reddish hue; the surface was studded with tubercles; on stripping off the capsule the larger of these remained with the kidney structure while some of the smaller ones were torn off. On section the cortical substance was seen to have a thickness of about one-third of an inch. Numerous foci of softening were seen. Three had the diameter of a nickel five-cent piece. There were very many smaller ones situated mostly in the pyramids. Numerous miliary tubercles throughout the substance of the kidney. The foci of softening were evidently due to breaking down of the tubercles. The ureter was dilated, measuring half an inch across in some portions. The mucous membrane was ulcerated. The pelvis of the kidney was not dilated and showed miliary tubercles.

The left kidney was large and was converted into five or six cysts, with but little kidney substance remaining. The surface of the kidney was studded with a few tubercles. The cysts were lined by a thick leathery membrane which could be stripped from the kidney substance. On puncturing the cysts a perfectly clear serous fluid at first escaped, soon followed by a milky substance containing some cheesy masses. The pelvis was smaller than normal, the ureter entirely occluded.

The *suprarenal capsule* had undergone degeneration and was of a uniform yellowish-white color, and presented tubercles.

The *bladder* was slightly contracted, the mucous membrane ulcerated, the muscular coat being exposed. The vesical trigone was of vivid red color and studded with miliary tubercles.

The *intestines* were normal—no enlargement of lymphatic elements. The mesenteric glands were slightly enlarged. The prostate gland and spleen were not examined.

Prof. Wm. Osler kindly made sections of the kidney and suprarenal capsule, and the reporter is indebted to him for the following report:

First, extensive, widespread, small-celled infiltration between tubules and Malpighian tufts. Second, distinct miliary tubercles with centrally placed giant-cells. Third, areas of softening and disintegration. Tubercle bacilli carefully sought for, but only two undoubted specimens found.

Suprarenal capsule showed miliary tubercle with centrally placed giant-cells.

Dr. Formad referred to a similar specimen which had been exhibited by Prof. Tyson at a former meeting of the Society.

Dr. Osler remarked that Dr. Fussel's case corresponded in all essentials to what is known as tubercular nephritis. The bacilli, however, were scarce and difficult to find. Since the report of Dr. Tyson's case a few weeks ago, he had had occasion to look over the notes of several cases and found that they formed a complete series from cases of unilateral disease to instances with tuberculosis of the entire urinary tract and general infection. The condition was not infrequently met with accidentally in persons dead of other affections.

April 23, 1885.

---

10. *Tubercle bacilli in the urine.*

Exhibited by Dr. W. Osler.

Dr. Osler showed a slide of pus from the urine in another case of tuberculous kidney with the tubercle bacilli stained.

April 23, 1885.

---

11. *Multiple hemorrhage of the kidney.*

Exhibited by Dr. F. P. Henry.

Anne J., æt. 59 years, a Dane, was admitted April 27, 1885. She had been ill for ten days. Her right lung was consolidated from base to apex. There was a soft, systolic, aortic murmur. Temp., on admission, 104°; resp. 32; pulse 140. The urine was scanty, bloody, and contained granular and bloody tube casts. The symptoms improved decidedly under treatment, but the patient remained in a condition of stupor from which she could be readily aroused until the 29th, when she died with marked symptoms of uræmia.

Autopsy.—Right lung consolidated, with a cavity the size of a walnut at the apex, and breaking down of the middle lobe. Left lung congested but otherwise normal. The heart was of normal size with a

slight stenosis of the aortic orifice, but without vegetation or ulceration of any of the valves. The kidneys weighed respectively six and three-fourths and five and three-fourths ounces. The capsules were adherent in spots. The cortical substance of both organs is the seat of a great number of round hemorrhagic spots varying in size from a hemp-seed to a large pea. They are not infarctions, but extravasations, as is evidenced positively by their shape, and negatively by the absence of vegetations on the cardiac valves or embolism in the renal vessels, for which careful search was made. The tumors are confined to the cortical substance and many of them occupy the extreme periphery and involve the capsule. Under the microscope the tumors were found to be made up of extravasated blood disks, and engorged capillaries. The kidney was also seen to be the seat of slight interstitial inflammation.

May 14, 1885.

---

12. *Specimens of extremely contracted kidneys.*

Exhibited by Dr. F. P. Henry.

Male, æt. 60 years, was admitted to hospital with great weakness, nausea, vomiting, dizziness, and occasional attacks of dyspnœa. There was slight œdema of feet and marked arcus senilis. Urine very pale, specific gravity 1.010; contains small amount of albumen and a few granular casts. Died about two weeks after admission in uræmic coma which was preceded by slight convulsions. The kidneys weigh respectively five and three-fourths and three and one-fourth ounces. They presented all the characteristic features of interstitial nephritis, the granulations being particularly prominent. From the surface of one of the kidneys projects a tumor which, until it was laid open, was taken for a cyst, but it is seen to be solid and to be composed of blood; it is as large as a walnut and of circular outline. It appears to be a cyst in which hemorrhage has occurred. The heart was the seat of very considerable hypertrophy and weighed one pound, eleven and a half ounces. Notes of the case were taken by Dr. Hopkinson, one of the resident physicians. *May* 14, 1885.

13. *Hydatids passed with the urine.*

Exhibited by Dr. W. Osler.

The patient, George S., æt. 58 years, an Englishman, resident of Ontario for thirty-five years, at present a farmer, but formerly a butcher for fifteen years. Always enjoyed good health until about four years ago, when he had a severe attack of nephritic colic on the right side, lasting only a short time and quickly relieved. Had no further trouble until two years afterward, when a similar attack occurred, confining him to bed for several weeks; some days he was better, but always worse on exertion. After a period of improvement for several weeks, during which time he was able to attend to his farm duties, he felt pain and uneasiness over the right kidney, followed in a day or two by pain at the point of the penis, which continued for several hours, and was relieved by the passage of gelatinous-looking masses in the urine. These bodies—hydatid—he has continued to pass at intervals of from two to four weeks. The discharge is always preceded by an uncomfortable feeling of fulness in the region of the kidney and pain or uneasy sensations at the penis No tumor has at any time been discovered in the neighborhood of the kidney. With the exception of these attacks of pain and distress in the urinary organs, prior to the discharge of the hydatids, he enjoys good health. He lost no weight; appetite good; bowels regular.

The specimens, which were given to me for examination by Dr. Palmer Howard, of Montreal, consisted of ten or a dozen hydatid cysts, ranging in size from a pea to a grape, and contained in a small quantity of urine. They were evidently the daughter-cysts of a larger one which was in communication with the urinary passages. Several of the cysts contained smaller ones (grand-daughter cysts). On examination of a drop of the urine in which they were, numerous hydatids and the characteristic hooklets could be seen.

Echinococcus of the kidney or urinary passages is very uncommon. Statistics show that the left organ is more frequently affected than the right. The points of interest in this case are: the long duration, the absence of evident tumor, and the excellent condition of the patient. Here is evidently a cyst of considerable size, possibly in the right kidney, and which bursts at times into the pelvis with the discharge of the hydatids.

In 1882 Dr. Osler had reviewed the literature of American cases of

echinococcus disease, and had made inquiries of the curators of the principal museums, the result of which was the collection of sixty-one instances of the disease (*American Journal of the Medical Sciences*, 1862). In not one of these was the cyst in the kidney. Since that date six other cases have been reported by Carson (*St. Louis Courier*, 1884), cyst of liver; Schæffer (liver), *Transactions* of the Medical Society of Pennsylvania, 1884; liver (liver and mesentery), *New York Medical Journal*, 1885; Helen (cyst of liver, ruptured into intestine), *New England Medical Journal*, 1883–4; Welsh (spleen), *Medical News*, 1884.

June 25, 1885.

---

b. FEMALE ORGANS OF GENERATION.

14. *Carcinoma of the uterus, fatty kidneys, and emphysema.*

Exhibited by Dr. W. A. Edwards.

The specimens which I show you to-night were taken from the body of A. E. this morning, I have not, as yet, had the opportunity of examining them microscopically. The patient was visited but once before her death by Dr. J. S. Wolf, for whom I made the post-mortem examination. The history of the patient is, of course, imperfect—in fact, little if any could be obtained; the symptom of which she complained most was an ill-smelling, irritating discharge from the vulva, so our attention was first directed to the womb, which presents a scirrhus carcinoma of the external and internal os and of the cervical canal. The mucous membrane of the organ is softened and very rugose-looking, not unlike a mammillated stomach; a microscopic section will probably show cellular infiltration. The uterus is enlarged; our subject was a multiparæ, æt. 45 years, nine children and two miscarriages. A cyst was seen in the right parovarium; its contents were pure serum. The ovaries presented areas of calcareous degeneration; other pelvic viscera normal. The kidneys were small and appear to have undergone some fatty change; the right one was a rib higher than its normal position.

The heart muscle had undergone some fatty degeneration, as had also the aorta; valves almost normal, ante-mortem clots in each ventricle, that in the right was of unusual size.

Pericardium contained the usual straw-colored effusion.

Lungs.—Left normal. Right: the pulmonary and costal pleuræ were in many places adherent by thick, well-organized lymph which

beautifully illustrates the *rationale* of friction râles, their sudden appearance, short duration, and equally sudden disappearance. About a pint of purulent effusion was collected in the base of the right chest. The diaphragmatic pleura was tightly adherent to the pulmonary, requiring some tearing in order to separate. The lobes of this lung are bound down by recent lymph. Scattered throughout the mesentery were to be seen areas of calcareous degeneration about the size of almonds.

December 27, 1883.

---

15. *Case of multiple ovarian fibro-cysts, with subperitoneal fibroids and general peritonitis.*

Exhibited by Dr. H. M. Fisher.

Barbara K., æt. 40 years, married, born in Germany, was admitted to the Episcopal Hospital early in July. Her father died of a tumor in the axillary region, one sister of paraplegia at the age of 16, and one brother and one sister are still alive and healthy. She married early, and had three children. Of these one lived but a day, one died at the age of 12 of "dropsy," and the third (a boy of 18) is still living. Two weeks after the birth of the last child she was obliged to make severe muscular exertion, actually laboring in the fields. Soon after this she noticed that she was losing blood *per vaginam*, and that she could no longer nurse her child. This bleeding appears to have recurred at intervals of two weeks for a year or more, and often amounted to a positive hemorrhage. Notwithstanding that this was the case, and that she had occasional attacks of severe pain, she continued to work as usual until three or four years ago. Three years ago she came to this country. At about this time she noticed a lump in her left groin, and from this time her abdomen steadily increased in size; she was seldom entirely free from pain, her appetite failed, and her bowels were habitually constipated.

Status præsens.—Patient is anæmic, and has a careworn, haggard look. Abdomen much distended. Distance from xiphoid to umbilicus two inches greater than from umbilicus to symphysis. Percussion clear over abdomen anteriorly, dull in flanks, and fluid moves freely with patient's movement. Hepatic dulness begins in third interspace in mammary line, but not apparently increased in width. Examination of heart reveals a faint systolic apex murmur; examination of lungs gives negative result. Much dyspnœa. The dyspnœa becoming urgent, she

was (July 14) tapped in the median line, two inches below the umbilicus, and eight quarts twelve ounces of a straw-colored fluid, rich in albumen, were removed. Immediately after the tapping an exceedingly hard mass was noticed in the left iliac region, apparently the size of a turkey's egg. On the 23d she complained of much pain in the left leg, and the tissues were noticed to be œdematous. This œdema was only slightly relieved by several punctures which were then ordered to be made. From this time till her death patient complained much of dyspnœa, hypogastric pain, and obstinate constipation. She was tapped time and again, and on each occasion a large amount of straw-colored fluid was removed. September 21st patient had a sudden attack of severe dyspnœa in the evening, and died in ten minutes. The post-mortem examination was made by the resident physician, Dr. J. K. Mitchell, sixteen hours after death, who furnished me with the following notes:

"Drew off fourteen quarts of fluid from the abdominal cavity by trocars and canula, all clear and straw-colored. On reinserting canula a small quantity of dark brown fluid, looking like beef-tea, came through. The belly walls were very thin; peritoneum everywhere much inflamed; whole intestinal surfaces and peritoneum covered closely with small whitish or pinkish points of tubercle; glands not much enlarged, but very hard; omentum as thick as one's hand, and of an almost wooden hardness and stiffness. Liver and kidneys apparently perfectly healthy. Two cysts in the broad ligaments of the uterus, one about the size of a base-ball, or a little smaller, the other still smaller. One had been tapped by the canula, the other contained about four ounces of the same brown 'ovarian' fluid. The ovaries, macroscopically, seemed healthy, and the uterus was normal in size and position. The lungs, though much compressed, showed no signs of disease and no adhesions. The heart had also been forced upward with the lung; otherwise nothing wrong with it."

A subsequent examination of the specimens brought the following facts to light: The uterus is decidedly hypertrophied, measuring about four inches internally, and appears abnormally hard. Closely attached by false membranes to the lower part of the body of the uterus upon the right side there is a *hard fibrous nodule* the size of a pigeon's egg. A somewhat *larger mass of similar character* is seen higher up and to the left of the uterus. The right *ovary* is enveloped in false membranes and closely adherent to the fundus of the uterus. The left Fallopian tube opens directly into the larger cyst of which mention has been made above. This has at its base a fibrous nodule (about two and a half by

three-quarters inches), which is covered on its under surface by a mass of false membrane. This is probably the mass that was detected during life in the left inguinal fossa.

In addition to the cyst above mentioned there were two other much smaller cysts, but it was found impossible to make out the exact relations of these to the other cysts, without a careful dissection, and this I failed to make. None of these cysts appeared, however, to be connected, as was stated above, with either broad ligament. The left broad ligament was found to be perfectly free; the right was wasting, but appears to have been removed during the autopsy, or subsequently.

The case is a complicated one, but the sequence of pathological events appears to have been the following: The patient having made severe muscular exertion a fortnight after confinement, was attacked by perimetritis and metritis. This inflammation, at first acute, soon became chronic in consequence of patient being unable to get proper care and the rest that she required. Whether the subperitoneal fibroids, from which she had suffered, had been already developed at the time this acute pelvic inflammation occurred, it is impossible now to say; but it is probable that they were of later development. Coincident with the periodical hemorrhages and attacks of pain from which the patient suffered fresh portions of the pelvic peritoneum were invaded. Finally, the peritoneum adjacent to the ovary was reached, and a perioöphoritis was the result. The inflammation of the peritoneal investment of the ovary extended, as Heitzmann states, to the ovary itself, causing a proliferation of connective tissue in the cortex of the organ, and from here to the adjacent connective tissue stroma. In this way the bursting of a ripened follicle may, as he says, be prevented, and a path may be opened for the formation of an ovarian cyst. Supposing this to have occurred in this particular case, we may easily see how the connective tissue proliferation may have gone on hand in hand, as it were, with the cystic degeneration of the ovary, until the whole ovary was converted into the multiple fibro-cyst that we see in the specimen.

The inflammation extended but slowly from the pelvis to the general peritoneum; probably because the products of inflammation were for a long time, in great measure, circumscribed by false membranes. Little by little, however, these products were taken up by the lymph channels, until finally the whole peritoneal surface was infected by them. The occurrence of general peritonitis probably did not antedate much the occurrence of the abdominal dropsy, three years ago, as before that time the patient, though occasionally incapacitated for work by pain, was still

able to attend to her usual occupations during the greater part of the time.

Report of the committee on morbid growths.—"Your committee reports that this specimen is one of peritoneal carcinoma, primary in the uterus and thence spreading to the peritoneum, and expressing itself as a miliary carcinosis." *November* 13, 1884.

---

16. *Cyst of the broad ligament.*

Exhibited by Dr. C. M. Wilson.

The cyst shown to-night is chiefly remarkable for its enormous size. It was taken from a woman, æt. 48 years, who had not yet reached the menopause. Prior to the operation the patient weighed 172 pounds, measuring around the abdomen at the umbilicus 84 inches. The cyst has thin walls with numerous large veins coursing over its peritoneal surface. Its removal was complicated by two firm adhesions, one to the abdominal parietes high up in front, and one to a portion of the small intestine. The cyst was filled by a thin, albuminous fluid, of a pinkish tinge. The cyst contents measured twelve gallons. The cyst and contained fluid weighed ninety-nine pounds four ounces. At this, the eighth day after the operation the patient is practically well, her temperature never having risen above 100.4° F. or her pulse above 100.

February 26, 1885.

---

c. MALE ORGANS OF GENERATION.

17. *Carcinomatous sarcoma of the left testicle.*

Exhibited by Dr. W. G. MacConnell.

This specimen was removed from a young man, by Prof. Brinton, at the surgical clinic of the Jefferson Medical College Hospital, on November 7, 1883. History: Jacob A., æt. 26 years, a clerk, about eighteen months ago struck his testicle in mounting his horse on the pommel of the saddle. The pain was so intense that he fainted; no inflammatory enlargement, however, of the organ ensued. Last May he noticed that the left testicle had begun to enlarge. It continuously increased in size until it had attained its present volume. There

was a sense of heaviness in the tumor, but no pain was experienced until about two weeks prior to its removal, when he noticed a periodical pain of a burning nature, which, with the increasing size of the organ, caused him to apply for relief. The tumor weighed about eight ounces, and measured, in its long diameter, four and a half inches; transversely, three and one-quarter inches, and about two and one-quarter inches in thickness. No lymphatic involvement was present, nor was the cord involved; the veins of the scrotum were enlarged and prominent. The tunica vaginalis testis was slightly thickened and very opaque, the tunica albuginea was also thickened, a slight remnant of the epididymis existed in the form of a small fibrous lump. The shape of the tumor was somewhat that of a kidney, and upon section showed a moderately firm, buffy colored tissue; it did not cry under the knife. In color and consistence it resembled the soft fibromata. Distinct remains of the fibrous septa are to be seen; there are no cystic changes or chondroid tissue present. Its macroscopical appearance and consistence suggested a spindle-celled sarcoma, and as such upon section I diagnosed it. Microscopically, at a first observation, from the great ecstacy of the epithelium present, I was inclined to regard it as a pure medullary carcinoma, but after a careful study of several sections I am inclined, by reason of the juvenescence of the connective tissue, both round and spindle cells being present, to call it a carcinomatous sarcoma. There was no history of syphilis, scrofula, or tubercle, nor had any member of his family ever labored under any form of tumor.

Dr. Nancrede called attention to the fact that modern microscopic study has shown that carcinoma of the testicle is a rare disease, most malignant tumors of that organ being really sarcomata. In this connection it is of much practical interest to note that the system becomes infected at a relatively late period of the disease, so that when a sarcomatous testicle is removed at an early stage of the disease, prolonged immunity, if not actual cure, results. The inguinal and retroperitoneal glands are those usually affected, their enlargement, by pressure, pain, etc., being the ultimate cause of death. Even more distant lymphatic glands are in rare cases involved.

Dr. Formad agreed with Dr. Nancrede. Some years ago he had paid special attention to the study of malignant growths of the testicle and ovary. Of the former, he had examined thirty cases, all of which were sarcomata. He did not believe in the existence of such a growth as true carcinoma of either the testicle, ovary, or kidney. The so-called carcinomata of those organs exhibit cells of a *connective tissue* type rather than of an epithelial. Dr. Formad considered, with many other ob-

servers, that the so-called epithelial cells of kidney, testicle, and ovary are really *endothelial*, and gave reasons in support of this view. He further said that there is a variety of endothelial carcinoma occurring in the breast which is that usually described as alveolar sarcoma. Here the endothelial cells of the lymph-spaces proliferate, but the glandular elements of the mamma do not participate. It is doubtless from the examination of such tumors that Virchow, Cornil, and Ranvier have gained the erroneous idea that true carcinoma takes its origin from connective tissue. The speaker would suggest the term "*endothelial* carcinoma" for such tumors instead of "alveolar sarcoma."

Dr. Davis did not think that Dr. Formad was correct in absolutely denying the existence of carcinoma of the testicle, ovary, and kidney.

Dr. MacConnell agreed with Dr. Nancrede as to the relative frequency of sarcoma of the testis, having examined a large number of such specimens. He could support the views of Dr. Formad as to the growths of the testicle originating largely in proliferation of the endothelia of the lymph spaces and tracts. *November* 22, 1883.

---

18. *Malignant disease of the testicle tapped for hydrocele.*

Exhibited by Dr. J. B. Roberts.

This case is clinically interesting because it resembled a hydrocele and misled me as well as another surgeon who had previously seen it. When the man came to me I found a large oval swelling of the left side of the scrotum which he gave me to understand had existed for two years. The tumor was six or eight inches long in the vertical direction, had a sharply defined upper limit, as has hydrocele of the vaginal tunic, and was indistinctly elastic, as is a tense hydrocele. The veins on the surface, however, were well marked, and it looked at the lower part as though the subcutaneous tissue was about to suppurate. It was this which gave rise to the pain that induced him to seek medical advice at this time: for he had previously postponed having another surgeon draw off the yellow water which he had been told was in it. I did not try to transmit light through the supposed hydrocele, because it is very often a fallacious test—at least, absence of light-transmission does not negative the existence of hydrocele.

I, accordingly, thrust a trocar into it and drew about six fluidounces of pure coagulable blood through the canula. Reinserting the trocar,

I pushed it in various directions, but met only solid tissue and no blood, except when it was pushed in the direction originally taken. Then blood flowed in a quite free stream.

No marked reaction followed, but the pain and tendency to suppuration were removed.

Two weeks later I removed the mass by the ordinary method of enucleation, and found the solid tumor here presented, which is, of course, the enlarged and infiltrated testicle.

On questioning, the patient now says that fifteen years ago, when he was about eighteen years old, the testicle or scrotum began to grow longer.

He is now rapidly convalescing from the operation. There was no involvement of the inguinal glands. *March* 27, 1884.

---

19. *Sarcoma of testicle.*

Exhibited by Dr. G. E. de Schweinitz.

This growth was removed from S. H., æt. 37 years, married, a patient of Dr. John Ashhurst in the surgical ward of the University Hospital. His father and mother are living and in good health. His grandparents died in old age, having led healthy lives. Of his two brothers and two sisters all are living, and three of them have been thus far in good physical condition. One sister had a growth removed from the orbit, probably a sarcoma, which is now beginning to recur. His own health has been good. He denied any venereal disease. Two and a half years ago he first began to notice a globular swelling at the bottom of the left testicle, which gradually increased in size until eight months ago, since which time the growth had been rapid, so that at the time of operation the circumference of the testicle measured fourteen and a half inches. Pain had been insignificant until last April, since which time he had suffered with severe dragging pains. The inguinal glands on both sides were slightly enlarged. The growth occupied the body of the testis, being surrounded by the tunica albuginea and tunica vaginalis, which are intact. It is a large, somewhat irregular, moderately soft, blood-stained mass. In one end there is an area of cystic degeneration. Microscopic examination shows this tumor to be a sarcoma of the round-cell variety, the cells being moderately large, containing oval nuclei and

sometimes nucleoli. In places a faint reticular network is demonstrable, producing a picture similar to the "lymph-gland like" round-cell sarcomas. *May* 23, 1884.

---

20. *Sarcoma of testicle.*

Exhibited by Dr. G. E. de Schweinitz.

A. K., æt. 43 years, a native of Germany, married, presented himself May 22d, in the surgical dispensary of the University Hospital for an opinion concerning a tumor of the left testicle with which he was suffering. His general health had always been good until one year ago, when he first noted a beginning globular swelling of the left testis. A short time previous to this he had suffered with gonorrhœa, which was followed by an attack of orchitis. He knew of no member of his family that had ever been afflicted with any form of morbid growth. Examination revealed a very large, somewhat pear-shaped growth of the left testicle, over which the skin was freely movable. The veins were much enlarged. The inguinal glands of the left side were also involved, and the thigh and leg of that side swollen from œdema. Above the line of Poupart's ligament both palpation and percussion revealed another mass situated in the left iliac fossa. A very unfavorable prognosis was given, and operative interference not advised. He, however, earnestly begged for the removal of the tumor of the testicle, which caused him severe dragging pain and incommoded him in walking. The dangers of the operation, and the fact that it would at best be only palliative were explained to him, and as he still asked for its performance the growth was removed. The case progressed very well for a few days, when he died rather suddenly. Dr. Hughes and myself made the post-mortem examination, and found the following conditions: Lungs showed commencing phthisis of apex, left pleural sac occupied by a pint of serum in which floated some flakes of recent lymph. Heart normal, cavities occupied by post-mortem clots. Liver very fatty, right kidney apparently normal. The retroperitoneal glands were all converted into a huge sarcomatous mass, as were also the glands and tissues of the left iliac region, and from there the growth passed up to the lumbar region and surrounded, although apparently did not greatly involve the kidney. Upon cutting into the tumor of the testicle about a pint of bloody serum escaped from the cavity of the tunica vaginalis. The growth occupies the body of the testis, is soft and friable, in places breaking down, and

the cavities thus formed filled with semi-fluid contents. The growth has burst through the tunica albuginea, thus showing the first step in the march of this morbid process up the spermatic cord, into the abdominal cavity, to the retroperitoneal glands and other tissues involved by the disease. Microscopically the tumor is a sarcoma composed of round and spindle cells, which are in relation to the remnants of connective tissue stroma. A very distinct tendency to alveolar arrangement is observable in places. It would probably be classed by some pathologists as an endothelial carcinoma or carcinomatous sarcoma.

Dr. Shakespeare said that the history of the case, the post-mortem finding, and the microscopic examination, forcibly reminded him of the last discussion by the Society of the same subject. In this case the disease had evidently travelled along the deep lymphatics as far as the retroperitoneal lymph glands of the lumbar region. In this particular it followed the course of systemic infection pursued by a carcinoma rather than a sarcoma. But it seems to be now well established that the well-known law governing the generalization of sarcomata meets with frequent exceptions in the case of so-called sarcoma of the testicle. Dr. de Schweinitz had spoken of the presence in this tumor of an alveolar structure, and, in truth, the manner in which the growth had exceeded the bounds of the testicle brings to mind at once the history of an alveolar sarcoma. The reporter had spoken of this tumor as "an endothelial sarcoma." Dr. Shakespeare objected to this use of the term "endothelial," and thought that the tumor in question would be more properly defined as "an alveolar sarcoma." He thought that the term "endothelial" was most commonly applied to carcinomata of certain kinds rather than to sarcomata, and did not think that the tumor named by Klebs "an endothelial carcinoma" differed from other genuine carcinomata in the form or nature of its cells and alveolar structure, but only in the fact that it may originate or be propagated in the lymph spaces or channels. If the term "endothelial" be insisted upon in this case, why not call the growth "an endothelial carcinoma?" This naturally raises the question of pathogenesis. We are told that the testicle is a derivative of the mesoblast. If this be true, here is ground for debate as to the proper name to give a tumor of the testicle, which has an alveolar structure and a clinical history analogous to that of true carcinoma. He who believes that true carcinoma never has a real connective-tissue origin will not consent to call such a growth of the testicle a carcinoma unless he can satisfy himself that, by some chance, a few epithelial cells from the blastoderm have become misplaced in the process of development, and have remained here to form a nidus of a future

carcinoma. Malignant tumors of the testicle seem to occupy an anomalous position. They are called sarcomata in the main, and yet, as a rule, their clinical history does not correspond to the sharp outlines which comprise this class of tumors in other localities. On the whole, Dr. Shakespeare was inclined to agree with those writers who accepted in general a connective tissue origin for true carcinoma in contradistinction from the epithelial origin of true epitheliomata, and therefore saw no well-grounded objection to applying the name of true "carcinoma" to those growths of the testicle which present a typical clinical history and anatomical structure of carcinoma, although they may spring from connective tissue. As bearing upon the subject of pathogenesis of carcinoma he referred to the observations of a few authors who deny the pure epithelial origin of some glandular structures, mentioning in particular the opinion of Creighton, who, after a careful and extensive series of observations on the development and involution of the mamma, concludes that the acini of this gland are not developed from the cutaneous epithelium, but are derived from the connective tissue.

June 12, 1884.

---

21. *Urethral polypi.*

Exhibited by Dr. G. E. de Schweinitz.

These specimens of urethral polypi were removed from a patient with the following history: ——, æt. about 30 years, contracted gonorrhœa, which was unusually stubborn and prolonged in its course. The disease had lasted about five months, when I first saw the patient. He was then suffering, on account of some imprudence, from a moderately sharp attack of cystitis. Having recovered from this and from the acute symptoms of the exacerbation which had probably caused the cystitis, he returned to his former condition of a drop or two of purulent discharge in the morning, which no treatment seemed to relieve. Suspecting then that the long-standing discharge, the diminished calibre of the stream of urine, and the feeling of weight in the perineum might be due to a polypus, I explored the urethra with an improvised endoscope, and found first two and later these three polypi, removed them, and had the satisfaction of seeing a cure follow this treatment. They were all situated within the first three inches of the urethra. I think no doubt these little tumors are papillomas, and belong to the more common varieties of new growths which are seen in the male urethra. A rough

examination of them with a pocket lens reveals quite nicely their dendritic formation. Tumors of the urethra, in the male at least, are usually stated to be of rare occurrence; although as Belfield, of Chicago, has remarked, they may not be so rare as is usually supposed, as the urethra is seldom systematically examined upon the post-mortem table. Belfield himself, in a series of seventy autopsies, discovered two urethral tumors. *January* 22, 1885.

---

d. MAMMARY GLAND.

22. *Recurrent scirrhus of the male breast.*

Exhibited by Dr. G. E. DE SCHWEINITZ.

This case possesses peculiar interest for two reasons: 1. On account of the comparative rarity of cancer of the *male* breast. 2. Because the second growth had its point of beginning where one of the sutures had been introduced at the primary operation. This suggests the question, whether it would not be an interesting study to make sections of the edges of flaps that are about to be approximated after the removal of malignant growths and note whether any morbid manifestations would present themselves, ready to be lighted up into active growth by any irritation, as in this instance, by the passage of a suture. It teaches one practical lesson, that all incisions for such purposes should be carried as far into healthy tissue as possible. There was no family history of cancer or injury, but some enlarged axillary glands, the patient stated, were present at the time of the first operation. *November* 8, 1883.

---

23. *Spindle-celled sarcoma of the breast.*

Exhibited by Dr. G. E. DE SCHWEINITZ.

I desire to exhibit a few sections this evening cut from a tumor of the breast, removed by Dr. John Ashhurst, in the University Hospital. The history of the case in brief is as follows: Annie S., married, æt. 35 years, the mother of four children. Family history good. Her own health good until two years ago, when she began to suffer from malaria. The tumor of the breast first began to be manifest one year ago and

grew gradually without much pain until the date of operation, when it had attained the size of an orange. There was no enlargement of the axillary glands. The nipple was not retracted. The growth was hard to the touch, and in spots the skin had become adherent, giving rise to "the pitted, somewhat brawny or lardacous appearance" which is described by surgical writers as rather indicative of scirrhus of the breast. This appearance was sufficiently marked to cause the diagnosis of hard carcinoma to be suggested as probably correct. After removal, when the mass was laid open, both cut surfaces did not appear concave, as is usually the case in a scirrhus. Microscopic examination cleared up the diagnosis, for, as you will see by examining the specimens, they show the typical appearances of a small spindle-cell sarcoma. It seemed a good case to illustrate the difficulties sometimes encountered in correctly diagnosing tumors of the breast, and for this reason I have briefly placed it upon record. *November* 11, 1883.

---

24. *Fibroma mammæ.*

Exhibited by Dr. W. G. MacConnell, for Dr. W. H. Pancoast.

The patient was 22 years of age, and the growth was of seven months duration. Fibromata of the breast are very frequently found, although some English authorities consider them to be of rare occurrence. They have been variously described under different names by writers. Birkett considers them a form of adenoma, Broca adenoma with predominance of stroma, etc. This tumor was of an ovoid shape, firm, and elastic, and on section presented a marrow-colored tissue, which, under the microscope, is seen to be composed of dense bundles of mature fibrous tissue with but few nuclei. In some portions bands of wavy connective tissue are seen. The epithelial elements of the acini are hyperplastic.

December 13, 1883.

---

25. *A case of Paget's disease.*

Exhibited by Dr. W. G. MacConnell, for Dr. J. Hearn.

This breast was removed at the Jefferson College Clinic, by Dr. Hearn, May 17, 1884. History: Mrs. Baker, æt. 39 years, has been married for nineteen years, and has borne four children, and had one

miscarriage. No other member of her family has ever labored under any form of tumor. Four years ago, following a pustular eruption on her abdomen, a lump was noticed in the left breast, which was the seat of lancinating pain of an intermittent character. Previous to the discovery of the lump an eruption of eczematous nature was noticed; it had existed some seven or eight months before she noticed the lump, the nipple, at the time of operation, was thoroughly retracted; indeed, had melted away. There was no axillary involvement, although there was noticed a gland at the upper and inner quadrant of the breast. On section of the tumor, after its removal, several small nodules of a hard, fibrous consistence were encountered. Microscopically, I found them to be the seats of carcinoma of a scirrhus nature; the gland revealed a similar condition. *May* 23, 1884.

---

26. *Colloid carcinoma of the mamma.*

Exhibited by Dr. W. G. MacConnell, for Dr. J. Hearn.

This tumor was removed by Dr. Hearn, of the Jefferson Medical College Hospital, about one week previous to the removal of the other breast. History: Miss C. B., æt. 67 years; general health good; family history of phthisis. No other member of her family had ever labored under any form of tumor. About three years ago she felt a lancinating pain in the right breast; on examination she found a hard, roundish lump, about the size of an English walnut. It increased until, at the end of eighteen months, it had attained the size of an egg. She consulted a quack, who applied a salve, which caused some bleeding, two months before her admission to the hospital. She stated "that the breast began to gather," and one week previous to the operation "it broke, and a dark greenish fluid escaped," which was afterward followed by the extrusion of a mass of greenish-colored slough. The growth was attached to the overlying skin, but not to the pectoral tissues beneath; the subcutaneous veins were enlarged and prominent; no glandular involvement existed. On section the tumor was found to be densely hard, and the seat of small cavities filled with a glairy, gelatinous, semi-solid fluid. Microscopic examination showed alveoli filled with epithelium that had undergone fatty degeneration, not a few of them showing the

laminated appearance peculiar to colloid. The connective tissue of the stroma was in a state of active proliferation, due probably to the inflammation resulting from the cystic change already mentioned.

May 23, 1884.

---

27. *Cysto-sarcoma of breast.*

Exhibited by Dr. G. E. de Schweinitz.

Dr. Agnew, who removed this specimen, permits its exhibition. The patient, a single woman, æt. 45 years, eighteen years ago first noted a painless induration in her breast. The physician whom she then consulted, advised against any operative interference. The growth for many years was practically stationary. From time to time the patient consulted surgeons in regard to the advisability of its removal, but invariably received discouraging replies. Two years ago the tumor became more active, and a marked increase in its size was noted, and within the last four months this increase in bulk was rapid and attended with dragging and shooting pains. There was some cachexia, but no glandular involvement. On May 19, Dr. Agnew removed the breast and sent it to me for microscopical examination. The tumor is a lobulated mass, about the size of two clenched fists, surrounded by a distinct capsule, and situated somewhat below but rather to the outer side of the nipple line. The growth is apparently composed of two parts, the outer one separated from the inner by a sulcus caused by a constriction in the capsule. This outer mass on section shows a slightly lobulated exterior, and the surface of the section is smooth, semi-translucent, and resisting. The inner mass is markedly lobulated and, on section, exhibits numerous cystic cavities, most of which are occupied by collections of papillary excrescences. Further, there are here and there small sac-like cavities filled with a translucent, gelatinous-like substance which is a myxomatous change of the tissue. Similar spots of degeneration exist throughout the tumor mass. Microscopical examination of this tumor in various parts shows practically the same structure. Sarcoma tissue, the cells of a mixed character, the spindle shape predominating; smaller and larger cystic cavities, lined with columnar epithelium, these cavities being sometimes round, sometimes oval, more often branched clefts extending hither and thither; finally areas of mucous degeneration. The diagnosis is then clearly a *cystic mixed-celled sarcoma*, undergoing myxomatous changes.

June 26, 1884.

28. *Sarcoma of the breast.*

Exhibited by Dr. G. E. de Schweinitz.

Some weeks ago I had the pleasure, through the kindness of Dr. Ashhurst, of exhibiting a specimen of cysto-sarcoma of the female breast, and to-night I am once more indebted to him for the privilege of showing this tumor, also a cysto sarcoma, but differing in type from the previous growth. It is another instance of the truth of the remark, so justly made by Rindfleisch, that "the expression cysto-sarcoma is by no means to be conceived as the designation of a definite, perhaps round-celled, sarcoma with cysts, but it only tells us that as new formation with the textural character of histioid tumors has attacked the mamma and dilated its preformed cavities." This growth was removed from the person of a lady of middle age, married, but childless. She assigned no cause for its appearance. The growth of the tumor has been slow, it having originally been noticed six years prior to the date of operation. The weight of the mass immediately after removal was three pounds and one ounce. On palpation there was a distinct sense of fluctuation; the skin over the tumor was discolored, but not adherent. On section the growth is seen to be composed of two parts, the one about the size of a closed fist and the other somewhat smaller. The section evacuated a quantity of bloody, mucus-like fluid. The centre of each mass is seen to be cystic, or rather the masses are the papillary and irregular excrescences which have protruded into the dilated ducts. The growth is composed of numbers of variously shaped nodules, whitish or yellowish-white in color, but, in some spots semitranslucent, resembling somewhat colloid material. The microscopic examination of various portions shows similar results, differing only in degree. Large round-celled sarcoma tissue and some spindle cells, generally diffuse, but in places tending to alveolar arrangement. Here and there round, stellate, and spindle cells, branched and anastomosing (mucoid tissue). Numerous bloodvessels, usually wall-less or mere channels passing through the tissue. In many places the sections show the enlarged ducts, cut transversely, and lined with a single layer of columnar epithelium. Surrounding these is a dense matrix of connective tissue. It may not be uninteresting to state that the specimen has been preserved in a solution of hydrate of chloral (gr. xx–ʒj) after the manner originally recommended by Dr. W. W. Keen, with what success the beautifully fresh and natural appearance of the growth plainly attests. *May* 14, 1885.

VI. THE NERVOUS SYSTEM.

1. *Phantom brain.*

Exhibited by Dr. Guy Hinsdale.

The model is constructed in colossal proportions, and is intended to show the course of the fibres in the human brain, and their relation to the several nuclei and the spinal cord. This preparation has been recently purchased for the Mütter Museum of the College of Physicians, and was constructed by Buechi, of Berne, Switzerland, under the supervision of Professor Aeby.

The height is 125 cm.; its width, 70 cm. The cortex is dotted over with numerous corks 2 cm. long, which are distributed in systematic order. The basal nuclei, of a much larger size, are seen in their appropriate places. The spinal cord, made up of ganglia and columns of wires of different colors, is represented throughout a portion of the cervical region. These columns of the cord, of different colors to distinguish their functions, lead to their appropriate ganglia, of corresponding color, or to the areas in the cortex, which are marked by similarly colored corks.

Taking first the anterior and lateral columns of the cord painted red, we can trace these motor fibres to the anterior and lower portion of the medulla, where they decussate, through the pons, to the internal capsule, where, between the caudate nucleus of the corpus striatum and the optic thalamus, they radiate to the cortex. They are seen to come chiefly from the convolutions about the fissure of Rolando. Where red balls are seen, from that point a red, motor fibre descends to the anterior or lateral columns. It will be seen that the column of Türck, or direct pyramidal tract, is in relation with the posterior part of the lateral column of the opposite side. As regards the exact localization of the sensory and motor tracts of the spinal cord, there is still some discrepancy of opinion. Professor Ferrier states that the antero-lateral columns are usually regarded as the chief motor paths, but quotes the recent and careful experiments of Ludwig and Woroschiloff (1874), who place the motor paths in the lateral columns only. The anterior columns (of Türck) are regarded more as commissural connections between the

motor nerves and adjacent segments, and not at least the direct paths of motor impulses proceeding from the brain.

Tracing the fibres of the posterior columns, colored blue, we find them represented as wholly decussating in the medulla, forming the posterior third of the internal capsule, and passing to the corpora quadrigemina and optic thalami, colored blue, which are the great centres of sensation.

The external portion of the lateral columns, colored green, are seen to lead to the cerebellum, decussating near its superior surface. The yellow fibres of the model place the basal nuclei in communication with the cortex; the white fibres, constituting the corpus callosum, are purely commissural. The columns of the cord as represented in the model correspond precisely with the arrangement given by Flechsig, and endorsed by Charcot and Hammond. Ludwig and Woroschiloff argue that "a vicarious interchange of function potentially exists between different parts of the cord." Ferrier admits that in determining the course of the cerebral fibres, anatomy reveals very little, and that physiological experiment is practically the only means at our command. Many more observations and experiments will have to be made before it can be said that the sensory and motor paths have been exactly defined and all views reconciled. *September* 25, 1884.

VII. ORGANS OF THE SPECIAL SENSES.

1. *Necrosis of the temporal bone and brain abscess.*

Exhibited by Dr. Guy Hinsdale.

This specimen was removed from the body of Margaret P., æt. 46 years, who died in the Episcopal Hospital, September 21, 1882, after long-standing aural disease.

In early childhood she had scarlet fever; this was followed by aural catarrh, and the discharge from the ear continued until her death. She stated that when twenty-two years of age a polypus could be seen in her ear. Fifteen years ago this was removed; again, masses were removed thirteen years, two years, and one year ago.

In May, 1883, four months before her death, the patient consulted Dr. Burnett, who has very kindly furnished me with notes of that date. The patient presented at that time a most wretched appearance. Extreme weakness, pallor, and emaciation betrayed the intense suffering of this unfortunate woman. Paralysis of the right side of the face had occurred during the previous winter without the supervention of additional ear symptoms. At the time of examination she presented great sensitiveness of the auriculo-temporal nerve, and complained of intense pain over the right temporal bone. To control this pain she was accustomed to use morphia suppositories. An examination of the ear revealed a mass of granulations filling the entire lumen of the auditory canal, half an inch from the entrance. Late in May a large polypoid mass was extracted; bare bone was then discovered on the posterior portion of the canal; the channel was narrowed, and blocked with granulations. About two fluidounces of blood escaped after removing this mass.

When I saw the woman at the Hospital, in September, she was in a very low state, and evidently near her end. Her mind was seriously affected, conversation was impossible, and she groaned with pain, which large doses of morphia did not altogether control. There was a moderate but constant purulent discharge from the ear and from a sinus which was found above the meatus. The whole temporal region was boggy. The probe passed in freely over an inch, and loose particles of

dead bone could be everywhere felt. The disease had long been beyond the reach of any remedy, and there was nothing to be done but relieve pain and await her death.

The specimen removed embraces portions of the right temporal, parietal, and occipital bones. Almost all the temporal bone has been destroyed. Only the mastoid process and the upper border of the squamous portion remain. An area of bone of one and a half by two inches has entirely disappeared. Adjacent to this region, and lying next the middle fossa of the skull, was a brain abscess, the walls of which were greatly thickened. On opening this cavity about an ounce of thick, yellowish pus was found. A probe easily reached this cavity through the auditory canal, and the sinus above it, and many loose fragments of bone were found at the outlet. The styloid process was found loose, but held in position by the various ligaments that arose from it. The inflammatory process, in which the meninges had, of course, shared, was not acute, the brain substance beyond the abscess walls had no unusual appearances, and the left cerebral lobe, with its membranes, was normal.

Dr. C. H. Burnett thanked the Society and Dr. Hinsdale for the opportunity of seeing this very interesting specimen, and of making a few remarks upon the case. The great destruction of bone tissue was remarkable, and unusual in extent, being three inches in length, and one and a half to two inches in breadth. The necrosis seemed to have originated in the tympanic region rather than in the mastoid, and hence belongs to the class of cases second in frequency—the most frequent being those fatal cases where the bone disease originates in and extends from the mastoid cavity. The case, when seen by Dr. Burnett in the spring of 1883, presented very grave symptoms, and the patient was extremely weak; so much so that Dr. Burnett was surprised that she lived until September. The occurrence of extensive granulations in the external auditory canal constituted a very unfavorable feature, as they acted like a dam, preventing the escape of the products of inflammation, and held them back, in the tympanic cavity and mastoid cells, forcing them to break an escape through more important and vital tissues. The case furnishes another example of the evil of neglect of purulent disease of the ear. Dr. Burnett inquired whether there were symptoms of destruction or implication of any of the nerves passing the cavernous sinus, as would be shown by alteration in parts supplied by the oculo-motor, the pathetic and ophthalmic nerves.

Dr. Hinsdale replied that no eye-symptoms had ever been detected.

December 27, 1883.

2. *Slides from an adeno-fibroma of lachrymal gland.*

Exhibited by Dr. G. E. de Schweinitz.

These sections were made from a tumor of the lachrymal gland which was removed by Dr. Agnew. The growth occurred in a young man, was of five years' duration and painless, having been situated in the upper and outer part of the orbit. The eye was sightless from atrophy of the optic nerve. The tumor, which was about the size of an English walnut, was surrounded by a dense fibrous capsule; the main body of the growth was composed of fibrous tissue, through which the remains of the gland tissue are seen. The epithelium is, in places, in a state of proliferation, but apparently no formation has taken place which could be justly characterized as malignant. The tumor may be classed, I think, as a fibroma or adeno-fibroma of the lachrymal gland.

January 22, 1885.

---

3. *A case of mastoid abscess ending in basilar meningitis.*

Exhibited by Dr. G. E. de Schweinitz, for Dr. B. A. Randall.

Willie G., æt. 2½ years, was admitted into the Children's Hospital in the middle of February last, suffering with caries of the mastoid. His aunt, the only relative, stated that a discharge from both his ears had begun in January; he had been promptly taken to an ear clinic, but received little attention, partly because her own ill-health (pulmonary phthisis, of which both parents seem to have died) interfered with regular attendance. An incision was made over the left mastoid and something inserted—probably a tent, but perhaps only a seton; the case grew, however, rapidly worse—the whole auricular region became swollen, the face was drawn to the opposite side, and the discharge from the ear and from the opening behind it became copious and extremely fetid. This was the condition at the time of his admission. Hourly syringing with permanganate solution was unequal to keeping the ear clean, and the bedding and clothing were continually stained by the foul sanious discharge. The facial palsy of the left side was complete—the eye staring open and the conjunctival sac full of muco-pus. Inspection showed a large opening close behind the ear, nearly an inch in its vertical diameter and half an inch wide, leading into a large cavity

in the diseased bone. The carious process seemed to be progressing in all directions, the honeycombed dead bone showing but few points of granulation tissue, and these anything but healthy. There was also some slight burrowing along the sterno-cleido-mastoid. A probe passed in through the external meatus occupied the centre of the cavity, and showed that all traces of membrana tympani and ossicles, and, indeed, most of the tympanic bone were missing. The concha and posterior wall of the meatus were deep purplish in color, and seemed entirely unsupported by bone. The stapes could not be discovered, and a dark point in the inner wall was recognized a little later as the open oval window—the entire inner wall being rough and corroded, and the destruction extending as far forward as the isthmus of the Eustachian tube. The discharge from the right ear had ceased before his admission, and there were no symptoms of trouble upon this side—a cursory examination revealed nothing but a small patch of eczema above the auricle. The child did not talk, but was evidently not deaf. He was feeble and emaciated, but showed no other paralyses or notable symptoms; there was marked hectic fever, however, rising often to 103°, yet generally falling by morning to 99° or below. (Highest point noted, 103.6°—lowest, 98.4°; no regular temperature sheet was kept, unfortunately, and the scattered data are not at hand.)

During the last week of April he steadily failed, no longer recognizing his aunt at her visits—taking little notice and lying quiet. The temperature no longer fell so markedly in the morning, remaining about 100°, and he died on April 30th, apparently from exhaustion, without developing any new symptoms.

Autopsy, twenty hours after death.—Body much emaciated, face still drawn to the right and general aspect unchanged. Only the head was examined. The fontanelle was still open; the calvarium was normal, but some firm adhesions of the dura mater, especially at the occiput, rendered its removal very difficult. Some post-mortem clotting in the longitudinal sinus, as well as in those later examined; but in most respects the dura was perfectly normal, its arachnoid surface being smooth and glistening. There were marked œdema and venous congestion of the convexity of the cerebrum, and the brain was soft and somewhat lacerated by the force necessary in removing the calvarium. On removal the central portions of the base of the brain were found covered with a thick yellowish-green exudate, extending from the upper part of the medulla forward beyond the optic chiasm and surrounding the apparent origins of the first eight cranial nerves. It did not pass into the fissures nor extend out upon the lobes of the cerebrum or cere-

bellum. The brain showed little further abnormality, the ventricles being but moderately distended with clear fluid, and there were one or two minute extravasations in or *upon* the floor of the fourth ventricle. The exact quantity of fluid in the cavities and at the base could not be measured as it was in great part lost in opening the skull; it was, however, but slightly excessive.

Examination of the base of the skull showed little abnormality, except that the left internal auditory meatus was full of purulent matter, which infiltrated thoroughly the seventh and eighth nerves, and, to a slight extent, the dura mater about them. The dura was everywhere else smooth and apparently normal, except that over the posterior part of the tegmen tympani it showed a faint dark coloration, the yellowish centre of which indicated pus close beneath. There was no perforation, however, although the lack of bony resistance at this point showed that the tegmen was in large measure destroyed. The lateral sinus seemed entirely normal.

The temporal bones were removed and are now before you. The *right* temporal shows nothing abnormal, except the perforation involving the lower portion of the drum membrane, now somewhat exaggerated by the drying of the specimen. There was pus in the tympanum—probably inspissated during life, but softer post-mortem—the remains from the otorrhœa which had ceased several months before. The *left* temporal bone shows complete destruction of the outer wall of the mastoid antrum, above and behind the meatus externus, as well as loss of the posterior wall of the meatus itself and of the greater part of the tympanic bone. The tympanum, antrum, and meatus externus are thus thrown into one, forming a cavity of approximately ovoid shape—the space between the meatus and the mastoid opening having been covered by the soft parts only. About the centre of the inner wall, the round and oval windows are recognizable and above the latter two more openings, one into the facial canal, the other into the external (horizontal) semicircular canal or its ampulla. The facial canal seems to be empty, the nerve having been wholly destroyed at this point. The tegmen is necrosed and riddled with perforations, but posteriorly the lateral sinus seems protected by fairly normal bone. Study of the intercranial surface of the bone, after laying the dura aside, shows necrosis only at the roof of the antrum. There are, however, some discoloration and honeycombing of the anterior wall of the lateral sinus, and in and around the meatus internus the dura is separated from the discolored bone by pus. There is little change in the membrane itself at this latter point; but in both of the others its periosteal surface is rough and thickened.

The dissection has not been carried further as yet, and the exact condition of the deeper parts remains to be studied. The exudate upon the base of the brain seems to contain minute nodules, perhaps tubercular, and some of it has been reserved but not yet submitted to microscopic study. As there was no clinical evidence of cerebral trouble the ophthalmoscope was not employed—indeed, the muco-purulent conjunctivitis, which was part of the time rather severe, would have rendered the study of the eye-grounds very difficult. The optic nerve entrances were removed, however, and show no macroscopic changes.

The specimens are presented now, although their study has not yet been completed, since they show some points of interest which may be less notable or lost when the dissection is carried further.

The clinical interest of the case seems to lie mainly in the fact that, although the cranial cavity was opened by the carious process and the dura mater was involved, the extension of the disease was through the internal auditory meatus, along the course of the auditory, and, perhaps more especially, the *facial* nerve. The fibrous dura mater protected all that lay within it; even the lateral sinus where the bony wall was carious. The tubercular character of the meningitis may have been secondary, the inflammation seeming to have been a direct extension of the mastoid suppuration.[1] *May* 14, 1885.

---

4. *Two specimens of sarcoma of the choroid.*

Exhibited by Dr. G. E. de Schweinitz.

Dr. William F. Norris kindly permits me to exhibit these specimens, both the patients from whom they were removed having been under his care, the one in private practice, the other in the University Hospital.

J. McT., æt. 21 years, applied for treatment at the Eye Dispensary of the University Hospital three weeks ago. He stated that for three months the vision of his left eye had been gradually diminishing, and for the last month the eye had been totally blind. This loss of sight was accompanied by no pain in the eye, neither did he suffer from headache or ciliary neuralgia, nor was his general health or nutrition in any way impaired. His occupation was that of a weaver, but there was

[1] The microscope showed tubercular nodules underlying the exudate at the base of the brain, but attempts to show the bacillus by Ehrlich's stain were not successful.

no history of injury or inflammation. He was examined by Dr. S. D. Risley and myself, and the following account is taken from Dr. Risley's description at that time: The vision of the right eye was normal, $\frac{20}{xx}$; in the left eye there was absolutely no light perception. The pupil, under the influence of a solution of homatropia, was dilated widely, but not so completely up and in as elsewhere. Using transmitted light, the eye looking directly in front, there was not the slightest reflex from the eye-ground. When the eye was slightly turned down, a small area of the ordinary red reflex was seen below, shut off above by an abrupt dark line, curved downward. In this space detachment of the retina was easily detected. Oblique light showed a reddish-brown mass occupying the upper and inner half of the eye-ground, coming almost to the posterior plane of the iris, so near as apparently to exclude the lens. This, however, was present and not opaque. When the eye was strongly rolled down, the upper lid raised, palpation over the ball detected an area of increased resistance and density as compared with the remainder of the eye. Over this region the perforating branches of the anterior ciliary vessels were enlarged and markedly tortuous. The general tension of the ball was not increased apparently. The diagnosis of intraocular tumor was made, and the patient advised to have the eye-ball enucleated. To this he consented. Dr. Norris performed the operation. The optic nerve was cut off one-half inch from the ball, and the succeeding hemorrhage rendered the tissue about the oblique muscles so tense as to make it doubtful in the case of the superior oblique whether this thickening was due to escaped blood or infiltration of the new growth. This suspicious orbital fat was removed. On section of the eye the cavity is seen to be occupied by a melanotic sarcoma growing from above and out, leaving a small space posteriorly and below, with attached retina and subretinal fluid.

The second specimen was removed by Dr. Norris from a girl, æt. 18 years. The history of the duration of the tumor is deficient. Here the new growth almost entirely filled the eye. The section which I exhibit to-night shows that the growth is composed of round and spindle cells, many of the cells of an epithelioid type, and portions of the tumor separated into an alveolar arrangement by a fine vascular structure. The tumor may be classed as an alveolar sarcoma. The optic nerve entrance shows atrophy of its elements, but no true infiltration by the new growth. A year after the operation no return *in situ* had occurred.

Dr. Tyson had examined the specimen with interest, and was at first at a loss to name the growth, as there were round cells of a connective

tissue type, epithelioid cells, and some suggestions of an alveolar arrangement.

Dr. Formad thought that the growth should be classed as an alveolar sarcoma.

Dr. Tyson thought it was an alveolar sarcoma, the sarcoma carcinomatoides of Rindfleisch and others.

Dr. Shakespeare said that the growth was a most extensive combination of epithelioid and connective tissue elements, evidently springing from the choroid, leaving the hexagonal choroidal elements untouched. There was also an evidence of dilatation of the bloodvessels, and filling up of their lumen with detritus and, perhaps, proliferated endothelial cells and leucocytes. In one portion of the growth there is a channel with as perfectly formed cylindrical cells as in an adenoma or cylindrical epithelioma. The fact that the patient has lived over a year since the removal of the eye, free from disease, would lead us to believe that the growth was benign. Whether it can be positively classed as a sarcoma is doubtful. By following around the section there can be no doubt that in the portion represented by the section the retina is not affected, as the hexagonal layer of choroidal cells can be traced unbroken.

Dr. de Schweinitz said that the retina was certainly not affected.

Dr. Shakespeare said that the non-recurrence of the growth was also against its sarcomatous nature, as the alveolar sarcoma was the one most likely of all to become generalized; besides, this growth contained germinal epithelial cells. *June* 11, 1885.

VIII. TUMORS NOT OTHERWISE CLASSIFIED.

1. *A case of sarcoma in the anterior mediastinum.*

Exhibited by Dr. E. T. Bruen.

A. N., a male, came under my notice in the Philadelphia Hospital in December, 1882. His family record was free from any history of malignant disease, and he had enjoyed good health until eight months before. His illness had been chiefly characterized by emaciation and pain in the chest. He was a tall, slightly built man, and when I saw him had evidently lost half his weight. The pain was most severe over the upper segment of the sternum, and radiated around the chest. There was dulness on percussion over the upper part of the sternum, and the respiratory murmur at the right border of the sternum was bronchial. The cardiac sounds, particularly the second, were almost inaudible. The remarkable feature about the above physical signs of percussion and auscultation was the localization of the pathological physical signs to a district scarcely more than four inches square at the upper part of the sternum ; the dulness downward was continuous with the cardiac dulness. Elsewhere, throughout the lungs, the physical signs were normal. The pressure-symptoms were very few, principally consisting in some evidences of pressure on the venous trunks, such as lividity of the face, with enlargement of the veins of the upper part of the neck. The other viscera throughout the body were normal. The patient died from exhaustion February, 1883, worn out by pain, which increased with the progress of the case.

Post-mortem examination.—On removing the sternum and cartilages, they were found to be adherent upon the right side to a mass which occupied the anterior mediastinum. The growth was seven inches long, measuring from the sternal notch, and terminated in a somewhat diffused thickening of the visceral pleura, which covered the anterior margin of the upper and middle lobe of the right lung. The growth was sausage-shaped and about two and one-half inches broad. It overlaid the aorta, pulmonary artery, and the vessels of the neck, thereby compressing them, and accounting for the muffling of the cardiac second sounds during life. The point of origin of the growth was obscure; it was evi-

dently unconnected with the anterior mediastinal glands, or with the thymus gland; some of the lymphatic glands at the root of the lung were slightly swollen, but not generally involved. The calibre of the trachea was not diminished. The glands of the neck were unaffected on either side. Laterally, at the lower portion of the growth, the pulmonary pleura was thickened at the line of contact with the growth, but the lungs were free from any traces of disease. The pericardial tissues at the right side of the chest were also somewhat thickened. The growth itself was of a fibrous consistence, of a gray-white color, and contained a softened tissue running through its centre. It was found, on microscopical examination, to be composed of medium-sized lymphoid cells, mixed with spindle-shaped cells, and embedded in a homogeneous stroma, or a stroma which consisted of reticulated fibres and wavy fibrous tissue. The peripheral thickenings of the pleura and pericardium were made up of similar elements.

There are certain reflections, based upon the clinical history of these tumors, which may be profitably considered in this connection. The age of patients suffering from sarcoma is commonly less than in cancerous malignant growths. In *Virchow's Arch.*, Bd. xciii. Heft iii., the statement is recorded that in 7566 autopsies, 158 malignant mediastinal growths were observed; of these, 31 were cases of sarcoma, the average age of the greatest number of cases being 41 years. Twenty of these occurred in males, the average being 38 years; 11 in women, whose average age was 48.

One hundred and twenty-seven of the above (158 cases) were carcinomatous growths, 81 in men with an average age of 53 years; 46 in women, average age of 56 years. In the *Trans. of the Path. Soc. of London*, since 1866, five cases of mediastinal sarcoma have been reported—one by Fenwick in 1882, æt. 29 years, a male; one by F. S. Eve, æt. 20 years, in 1880. In 1872, E. Clapton and J. F. Payne reported a case in a male, æt. 37 years. In 1871, T. B. Peacock, one in a male, æt. 27 years; and in 1870, one in a male æt. 20 years, by R. D. Powell.

Sarcomatous tumors, however, sometimes occur in the aged, as, for example, a case of sarcoma involving the pericardium in a woman æt. 76 years (*Virchow's Arch.*), and a case reported to the Philadelphia Pathological Society, January, 1884, by J. C. Wilson, occurring in a woman over 60 years old.

The majority of tumors of this character originate and are found in the anterior mediastinal region.

In 24 cases reported by Kahnlich (*Virchow*, Bd. xciii.), 13 occurred

in the anterior mediastinal region, originating from the connective tissues therein, 5 from the periosteum of the sternum, 3 from amid the cervical glands, 2 among the bronchial glands, and 1 from the pericardial substance. The thymus, or thyroid glands, may also form foci of origin for these growths. In the cases quoted from the *London Pathological Society Transactions*, the origin of the tumors was invariably in the anterior mediastinum; in two of them, however, the posterior mediastinal glands were also involved. The invasion of the various intrathoracic organs in the above cases was chiefly by contiguity, and in general there seems little or no tendency to excite inflammatory action in their vicinity. The lungs were secondarily involved in all the cases to which I have had access, with the exception of two cases: the one reported in this article, and one reported by R. D. Powell, M.D., both of which are unique because the disease was localized only in the mediastinum.

It would seem that the growths in distant parts of the lungs follow the distribution of the lymphatic vessels, the principal site of secondary processes being in the connective tissues surrounding the minute bronchial tubes. It is an interesting fact that while the lung would seem never to be the site of primary sarcoma, yet the pleural tissues may be primarily involved. In the *Medical Record* for January 5, 1884, a number of cases are quoted from Lepine, Birch-Hirschfeld, Böhme, Eppinger, and Schultz, and one by R. W. Greenish (*Journal of Anatomy and Physics*), in which the growths were abundantly distributed in the pleural tissues as primary formations. The point of origin is believed by these observers to be either directly from the ordinary connective tissue cells or from the endothelium of the lymphatics.

In mediastinal sarcomata the glands of the neck are less commonly involved than when the process is cancerous.

The origin of cancerous growths in the mediastinal region is usually in the posterior portion. In contrasting the respective sites of these two morbid growths, we may expect the physical signs and pressure-symptoms to correspond with the location. The vessels of the neck suffer either directly from pressure or by being converted into rigid tubes, allowing of no adaptation to the amount of blood passing through them. The descending vena cava and bloodvessels of the neck are often dilated. The trachea is very liable to pressure, also the aorta, which is usually covered by the growth, and by being pressed away from the sternum the sounds of the aortic semilunar valves, and those of the pulmonary artery, may be much reduced in intensity. Pressure-symptoms from an aneurism, growing laterally, or outward, are analogous; yet, in most cases, by means of bruit or other characters, an expansile

blood-containing tumor can be easily distinguished from a solid neoplasm.

The possible predisposing causative influences of occupation deserve a passing mention. In the case reported at the outset, the patient was a shoemaker, accustomed to press his tools of trade against the sternum. The question might be stated thus: Given, a pure family history, free from taint of malignant disease, the etiology of these tumors in this region may be more readily linked with irritation than is the etiology of cancerous tumors. The cases instanced in this paper were mostly free from an ancestry tainted with malignant disease. The anterior location of these growths in so many cases would also favor the theory of a traumatic etiology.

Sarcomata in the chest, as elsewhere, show a rapidity of development which contrasts with the cancerous type of growth. The general symptoms in cases of intrathoracic sarcoma, such as emaciation or pain, are relative to the size and location of the tumor, and the cachexia of malignant disease is usually well marked.

In the case of the patient recorded under my own observation, the opinion was entertained that we had to do with a malignant growth which would prove a sarcoma. The diagnosis was chiefly based upon the location of the disease in the anterior instead of the posterior mediastinum, upon the age of the patient, upon the rapidity of the progress of the case, which began in April and terminated in the following February, and the exclusion of aneurism chiefly by the absence of the usual signs of a blood-containing tumor. *November* 8, 1883.

---

2. *Tumor of the anterior mediastinum, with secondary deposits in the lungs.*

Exhibited by Dr. J. C. Wilson.

The specimens were removed from the body of an unmarried woman, æt. 60 years, who died in the hospital of the Jefferson Medical College, January 7, 1884. The patient had been singularly free from sickness until about eighteen months before coming to the hospital, three weeks prior to her death. The earliest symptoms were fixed pains of varying intensity in the sternal region, with attacks of palpitation and dyspnœa. These symptoms increased in severity, and were aggravated by exertion. After a time she began to experience difficulty in swallowing. Six weeks before admission to the hospital her feet and legs were, for the first

time, observed to be swollen. The dropsy soon became general. She had no knowledge of her family history.

On admission she suffered from constant dyspnœa, paroxysmal, often urgent, worse at night; inability to lie down; occasional unproductive cough; a sense of weight and oppression in the chest, and particularly in the precardial region; pain under the sternum, and great discomfort in swallowing. There was a high degree of general anasarca, and the evidences of pleural and peritoneal effusion. The surface was cool, the skin bluish. The examination of the chest was rendered difficult by the unusual thickness of the tissues, the patient being not only enormously dropsical, but also very fat, and the breasts being hugely developed. It was nevertheless noted that the impulse of the heart was feebly felt, the apex beating in the sixth interspace and somewhat to the left of its usual position; that a faint, systolic, blowing murmur was heard at the apex, feebly propagated toward the left; that the heart sounds at the base were unusually obscure, and that the pulse was feeble, frequent, and irregular. There was flatness with absent respiratory murmur at the base of the chest on both sides, and harsh broncho-vesicular respiration over the upper regions of the chest.

In the upper sternal region the cutaneous osseous twigs were conspicuous, without rising, as is sometimes seen, above the base of the skin. They were dilated and tortuous, and symmetrically arranged beyond the sternal borders, at which they abruptly ceased.

The thyroid body was enlarged and formed an egg-like projection in the median line. It was exceedingly hard, but not sensitive, over the seat of pain. The patient regarded it with indifference, and said that *the lump* had existed for "many years."

I was unfortunately prevented from being present at the necropsy, and this tumor was not removed.

The boundaries of dulness in the præcordium could not be distinctly made out. It was, however, noted that the distribution of pressure-signs absolutely negatived the existence of aneurism of the aortic arch as their cause. The pupils were equal in size and in response to light; the voice was unchanged; the radial pulses equally feeble.

The patient died suddenly in an attack of dyspnœa at 9 P. M. on the 7th of January.

Necropsy.—Body much swollen and œdematous; face and thorax very blue. Both the pleural sacs and the peritoneal cavity contained fluid in large amounts. Strong pleural adhesions in left side. The anterior mediastinum in its upper segment was occupied by a large, firm mass, mammillated in structure, extending from the notch of the sternum down-

ward five inches, and adherent to that bone and the costal cartilages. The width was about three inches, and its depth in an antero-posterior direction about the same. It comprised exactly the position of the thymus gland. Its visceral surface was embossed but smooth; in its upper portion only adherent to the great vessels. No adhesions existed between the parietal pericardium covering its posterior surface and the visceral layer of the pericardium. *January* 24, 1884.

---

3. *Lipoma.*

Exhibited by Dr. J. H. Musser, for Dr. T. B. Reed.

The mass was attached by a pedicle about an inch in diameter and two inches long to the under surface of the upper portion of the calf of the right leg. It had been growing for four years. The past six months it grew rapidly, half of its bulk having been added in that time. It was absolutely painless, not even the piercing of a needle causing pain. The raw surface is due to its having been burned when a cast of it was taken, the patient not experiencing any pain from the hot application. After removal, the soft tumor was found to weigh a full pound, and you see it is about the size of an egg-plant. It may be said that the pulsation of a small artery could be distinctly felt in the pedicle prior to the removal of the growth. Its histological elements were found, on microscopical examination, to be fat and connective tissue, the former in excess, the latter in striations throughout the tumor. *May* 8, 1884.

---

4. *Cystic papillary adenoma of the neck.*

Exhibited by Dr. J. M Barton.

Dr. Barton presented the specimen which he had removed from a patient at his clinic at Jefferson Medical College on September 6. The patient was a married woman, æt. 31 years, the mother of three children. The tumor was of slow growth, having existed for five years, and having increased but little in the last two years. It gave no pain and but little deformity. It was about the size of a walnut, and lay beneath the clavicular extremity of the left sterno-cleido-mastoid muscle

in close proximity to both the subclavian and carotid arteries, from which it received a decided pulsation; on strongly pressing the tumor upward and outward the pulsation ceased. The tumor was closely adherent to a number of large veins of new formation, which greatly increased the difficulties of its removal.

On section it presents a number of alveoli, of variable diameter, communicating with each other, and lined with a thick membrane, similar in appearance to the inner coats of the arteries. This membrane seems to have undergone calcareous degeneration in some portions. When the tumor was fresh these cysts, on incision, were filled with a dark red fluid like disintegrated blood. *September* 11, 1884.

Report of the committee on morbid growths.—"A section made from the tumor of the neck presented by Dr. J. M. Barton, shows a stroma of fibrous tissue in which cavities are seen, varying in size, lined with epithelium having a cuboidal shape; from the margins of many of these cavities papillary ingrowths are noted, covered with cylindrically shaped epithelium; other cavities are filled with the remains of cells or a structureless colloid-like substance. The tumor may, therefore, be considered a cystic-papillary adenoma, in which a colloid degeneration has occurred, or, from its location, it is not improbable that it may be either an outgrowth from, or a supernumerary thyroid gland."

October 9, 1884.

---

5. *Sarcoma of skin; secondary sarcoma of liver; ovarian tumor; rapid development of hepatic symptoms; death from exhaustion.*

Exhibited by Dr. J. H. Musser.

K. I., female, white, single, æt. 28 years, housekeeper, good habits. Family history good. No previous illness. Under care of Dr. Ludlow in Presbyterian Hospital. Health good until five weeks ago. She then experienced an attack of abdominal pain which occurred suddenly, and, although relieved, continued with more or less severity until death; she noticed one week after this accident a swelling below the ribs of the right side. During the two years previous to the development of these symptoms she had to micturate frequently, but since then the urinary symptom subsided.

On admission, Nov. 22, 1883, the abdomen was distended from ascites, and a tumor was noted in the epigastrium and right hypochondrium. The liver dulness extended from an inch below the nipple to six inches

below the ribs in the nipple line. By palpation its outline could be defined at the umbilicus and, on the right side, at the crest of the ilium. The surface of the liver appeared smooth, its border even; tenderness was marked. In addition œdema of the legs was very marked, the body was much emaciated, the countenance of a dusky hue, the conjunctiva slightly tinged with bile pigment. Further, the murmur of mitral regurgitation was heard over the heart, the breathing was labored, and the lungs œdematous. The temperature was normal. Appetite poor, tongue heavily coated, bowels constipated; one passage showed the feces dark and hard. Urine albuminous, specific gravity 1.010, light in color. Death two days after admission, from exhaustion and œdema of lungs.

Autopsy, eight hours after death.—Rigor mortis marked, trunk emaciated; abdomen distended, legs œdematous; face dusky and yellow tinged. On section, cavity of abdomen filled with bloody serum. Lungs œdematous. Heart small; left ventricle, wall thickened, averaging one-half inch. Mitral leaflets thickened and incompetent. Spleen enlarged to twice its normal size, soft and pulpy. Kidneys cirrhotic, but not granular, congested. In the left iliac fossa a cyst found with dark-colored grumous fluid contents, lobulated and springing from left broad ligament. It is to the liver and a tumor of the groin, however, that I wish to call especial attention.

The liver was not weighed, but was about three times its normal size. Two large round yellow-white umbilicated masses were seen on the surface, corresponding to the nipple line. On section they were soft, cream-colored, vascular, at the periphery the size of small oranges. Smaller similar masses were found scattered throughout the liver. The tissue of the liver between the masses was normal. The gall-bladder contained normal bile; the large bile-ducts were free and healthy. In the right groin two flat wart-like growths, hard and pale, the size of hickory-nuts, were seen, firmly connected with the subcutaneous tissue and inguinal glands. Warty in appearance, they looked not unlike a mulberry embedded in the skin, save in color. The glands of the corresponding groin were enlarged and matted together by a local inflammatory process.

Microscopical sections of the tumor of the skin and of the growths in the liver showed the appearance of an alveolar sarcoma; that of the skin developing from the adjacent connective tissue, and being, in all probability, the primary growth. These sections were made by my student, Mr. Stern, and the character of them confirmed by Dr. Formad.

I remark that the tumor of the skin was probably the primary growth,

for on examining the cyst of the broad ligament the left ovary could not be well defined, but in its place a nodule was seen which might have been a sarcomatous ovary. The tissues were too much destroyed for microscopical examination. *September* 11, 1884.

---

6. *Two cases of hypertrophied mole.*

Exhibited by Dr. G. E. de Schweinitz.

The first of these specimens is one removed from the face of a patient by Dr. John Ashhurst in the University Hospital. The man was aged about forty years, and the tumor took its origin in an ordinary mole, which, under the stimulus either of external irritants or undue manipulation, grew into a slightly raised mass, with flattened top and constricted base. After Dr. Ashhurst had excised the growth, I made a microscopical examination of it, with the following result: The uppermost portion of the tumor is densely pigmented, and the pigment is further seen to be of a brown or brownish-black color and contained in spindle or round cells, or to exist as free nuclei and granules. These pigmented spindle cells sometimes are arranged so as to form the boundaries of alveoli, which are in their turn filled with moderately large unpigmented lymphoid cells. The base of the mass shows a small cell infiltrate, enlarged sebaceous glands, and a massing of the epithelium of the part, forming the appearances of squamous epithelioma. Below, the fat and subcutaneous tissue present nothing abnormal. This growth may be classed, I think, as a hypertrophied mole having an epitheliomatous base.

The second specimen was removed by Dr. Agnew from the back of a man, also a patient in the University Hospital. This tumor developed in a mole and grew as a papilla-shaped excrescence above the surrounding skin level. Microscopic examination of the mass showed it, like the former one, to be composed of a densely pigmented tissue largely made up of spindle cells and free granules. Among the interstices of these were numerous blood channels filled with corpuscles. No malignant change at its base was noted, and the surrounding skin was normal. Ziegler, in his recent work on pathology, speaks of the not infrequent occurrence of melanotic and alveolar sarcoma in cellular warts and pigment spots; and certainly some parts of the specimens from the first case are strongly suggestive of a sarcomatous structure.

January 22, 1885.

7. *Sarcoma of the retroperitoneal glands.*

Exhibited by Dr. James Tyson.

Samuel D., a gardener, æt. 43 years, unmarried, was admitted to the Philadelphia Hospital August 15, 1884. There was no family history of phthisis or cancer, nor had he ever had syphilis. Three years ago he had a tertian intermittent fever which lasted a week only. He thought he had injured himself by heavy lifting in June, 1884, and dated his illness from that time, although he admitted having experienced some discomfort prior to that time in the constant stooping that his occupation required of him. About July 1st he noted that his feet and legs had begun to swell, also that the swelling would partially disappear at night. At this time he also began to have, at irregular intervals, severe pain in his legs, especially the left leg. He was subject to alternate constipation and diarrhœa. This was about his condition when admitted. There was also noted a swelling immediately below the edge of the ribs on the right side, which was ascribed to enlargement of the liver, the dulness occasioned by it being directly continuous with that of the latter organ. His condition changed slowly but gradually, the tumor became more evident, and the pain in the right leg increased. He was certain when admitted there was more pain in the left and at that time could not lie on the right side, while by November 20th he could rest more comfortably on that side. At this time the dulness extended in the mammary line, from the sixth rib to a line drawn transversely from a point one inch above the anterior superior spinous process of the ilium. In the middle axillary line the dulness extended from the ninth rib to the crest of the ilium, and posteriorly, from the eleventh rib to the same point. The tumor was bounded on the left and below by a line drawn from the umbilicus to a point one inch above the anterior superior process of the ilium and thence obliquely to that bone. There was distinct bulging in the right flank and right lumbar region. The circumference of the abdomen at the umbilicus was thirty-four inches. There was greater fulness in the right flank laterally and posteriorly, and the veins over this region and the right half of the abdomen were distended. From December 1st he was confined to his bed, being unable to stand in consequence of what he described as weakness in his legs, especially the right, and he suffered so much pain as to require the regular administration of morphine. The circumference at the umbilicus was thirty-six inches. The sulcus at the border of the ribs had become more marked.

There was at no time jaundice, and while he gradually emaciated there was no cachexia.

At first no thought was entertained that did not suppose the tumor was in some way associated with the liver. Abscess, lardaceous disease, and cancer were, however, excluded by the absence of the other essential symptoms, and it was finally thought that we had most likely to do with a hydatid cyst. This was based upon exclusion and obscure sense of fluctuation at the most prominent part of the swelling to the right of the umbilicus. Accordingly, on December 12th, I introduced an exploratory needle to the depth of four inches at this prominent spot. Only a few drops of bloody fluid were drawn, which was found upon microscopic examination to contain no distinctive elements. Forced by the results of this operation to abandon the liver as the seat of disease, the kidney was then selected as its probable seat, although repeated examinations of the urine had shown that while it was somewhat diminished in quantity it was otherwise normal. It was ascertained, however, twice, that it did not contain iodine after the administration of five grains of this substance. Soon after the 1st of January, 1885, his stomach ceased to retain food, after which he declined more rapidly, and died January 16th. As the disease progressed the tumor presented through the abdominal walls to the eye and also to palpation a more uneven outline, which could not, however, be described as nodules.

At the autopsy there was noted on inspection, œdema of the right leg and a tumor occupying the space between the ribs and ilium on the right side, extending three inches beyond the median line. It was bumpy or uneven; the hand could be pushed up a short distance between the ribs and the surface of the tumor. On section the visceral and parietal peritoneum appeared normal, and the omentum partially covered the abdominal contents, and was adherent only in the right iliac fossa. The colon was displaced, and, commencing at its head in nearly the normal situation in the right iliac region, extended upward and to the left along the border of the tumor mass to the region of the spleen, where it turned inward and made two or three twists along the left side of the abdomen. The right lobe of the liver was slightly enlarged, but the organ was otherwise normal. There were no adhesions whatever and its surface was smooth. It was unusually firm on section and the lobules seemed to have been compressed.

The *spleen* was slightly harder than usual, but otherwise normal. The pancreas and stomach were both displaced backward and to the left. The former was normal, as was also the latter, except that there were a few punctiform extravasations on its cardiac end.

The *left kidney* was found buried beneath the left portion of the tumor, and appeared one-third larger than normal. The capsule stripped off easily, leaving a smooth dark red surface. On section the cortex seemed slightly broader than in health and was darker in hue. These sections studied microscopically showed a normal histology. The organ was simply hypertrophied.

The *right kidney* was found closely applied to the front of the tumor —so closely that it was at first overlooked and the tumor thought to be one of that kidney. It was compressed, flattened, thinner than an average hand, and smaller in circumference than the normal organ. The minute examination of the right kidney revealed a very interesting condition. The tubules bore evidence of the compression to which the organ had been subjected. The cells were everywhere compressed and the tubules narrowed. There was a slight hyperplasia of intertubular tissue, especially about the Malpighian bodies. The *ureters* and *bladder* were normal.

The *pericardium* and *heart* were normal ; the *left pleural sac* contained a small quantity of bloody serum, and there were a few trifling adhesions.

The *left lung* contained along the outer anterior edge of the upper lobe, three inches from its base, a moderately firm nodule half an inch in diameter, pinkish-gray on section, and projecting above the adjacent cut surface of the lung. Two similar reddish-gray nodules were found on the lateral aspect of the lower lobe of the lung about four inches from its base. They were about an inch apart, about three-quarters of an inch in diameter, and projecting as much from the lung almost as sessile tumors. There was another small tumor on the posterior edge of the base of the lobe. There was more than the usual adhesion between the two lobes of the lung. The lower lobe of the right lung was much adherent to the diaphragmatic as well as the costal pleura. There was a warty excrescence about three-quarters of an inch in diameter attached by a small pedicle to the upper lobe and a still smaller one at its anterior edge. The nodules in both lungs were encapsuled. The *tumor* itself was lobulated and occupied the entire right side between the edge of the ribs and the pelvic bones and extended even to the left of the median line in the neighborhood of the umbilicus. It presented the same obscure sense of fluctuation, and upon section the lobes of which it was composed, each one of which appeared to correspond with an original lymphatic gland, protruded in its central position, and presented a uniform pinkish-gray surface of moderately soft, but by no means diffluent consistence. The microscopic examination revealed throughout the structure of a sarcoma. *February* 12, 1885.

8. *Two specimens of the recurrent "fibroid tumor of Paget."*

Exhibited by Dr. C. B. Nancrede.

These two specimens had been removed from the same patient at the interval of about four years. They presented no points of interest beyond the fact that they were typical examples of the small spindle-celled sarcoma, commonly known to us as recurrent fibroid. Possibly an explanation of the non-malignancy of such growths might be the more perfect organization of their vessel walls—which Dr. Nancrede thought careful microscopic examination would reveal—in contradistinction to the vascular channels, which the vessels of sarcomata practically were. *May* 14, 1885.

---

9. *Sarcoma of the thigh.*

Exhibited by Dr. H. R. Wharton.

Dr. Wharton presented a large tumor removed from the posterior portion of the left thigh of a patient in the University Hospital, under the care of Prof. Ashhurst, with the following history: George H., æt. 32 years, whose father is still living, and whose mother died when he was an infant, of meningitis, whose brothers are living and healthy, noticed some eight years ago a small tumor appearing on the posterior portion of the left thigh, about six inches above the popliteal space; since that time it has gradually increased in size, until at the date of his admission to the hospital it presented itself as an oblong tumor, larger than a man's head. The growth of this tumor was accompanied by paroxysmal attacks of severe pain. He could not remember ever having received an injury at this portion of his body. The tumor was enucleated without difficulty, and in so doing about six inches of the sciatic nerve were laid bare, which was directly in contact with the sheath of the tumor. A portion of the semitendinosus and biceps muscles was stretched over the tumor.

Upon examination after removal, the tumor was found to consist of one large cavity containing a reddish-brown fluid, surrounded by a wall, varying in thickness from an inch to two inches, and at points presenting numerous patches of calcareous degeneration; the inner surface of this wall was lined with irregular flocculent masses. Microscopical

examination proves it to be a spindle-celled sarcoma with areas of calcareous degeneration scattered through it.

The principal points of interest in this case are the large size of the tumor, the slow course of its development, the ease with which it was removed without injury to the surrounding structures.

Dr. Tyson said that he was much interested in the cystic feature of the tumor. It would be interesting to determine if this cyst—which is a typical example of the cysts by softening—has an endothelial lining. He also asked the nature of the fluid contents.

Dr. de Schweinitz replied that he had been foiled in his efforts to make satisfactory sections by want of time for decalcifying the growth. He had determined, however, that it was unquestionably a spindle-celled sarcoma. The contents of the cysts, which were of a chocolate color, had been spilled during the operation.

Dr. Barton said that at the previous meeting Dr. Nancrede had exhibited two growths, with a similar clinical history, and analogous histological structure. It would be interesting to examine both growths with reference to the character of the walls of the bloodvessels, as suggested by Dr. Nancrede, to ascertain if any light could be thrown upon the non-malignancy of the so-called recurrent fibroid tumor of Paget.

Dr. Nancrede remarked that he had at the previous meeting specially called attention to the fact that the *so-called* recurrent fibroid of Paget is a small spindle-celled sarcoma. The position which such growths occupy, viz., the subcutaneous connective tissue, did not seem to him, as had been suggested by Dr. Tyson, a satisfactory explanation of their non-recurrence. He was under the impression that a careful study of the histology of their vessel walls would demonstrate that they more closely approach those of a fibroid tumor than those of other sarcomata, in not being merely channels through the tissue, directly, or almost directly, in contact with the tumor cells. Dr. Nancrede thought the term "recurrent fibroid" a good clinical one, as applied to a certain class of sarcomata, since other tumors much resembling them in histological character pursue a far different course.

Dr. Tyson said that he had early made a study of these growths, first known as fibro-plastic tumors of Lebert, and later named by Paget "recurrent fibroid," but now correctly included among the sarcomata of Virchow. Dr. Tyson thought that the explanation of its non-malignancy is found in the fact that the physiology of sarcomata varies greatly in this respect, some being scarcely more so than certain fibromata, while others vie with the worst cancers in this characteristic. The former are represented by the hardest of the sarcomata, which again

are the small spindle-celled, which may be said to be the type of the recurrent fibroid of Paget. He agreed with Dr. Nancrede, that the term is a good clinical one, designating a small spindle-celled sarcoma recurring *in loco*, but seldom by metastasis.

Dr. Formad said that no true tumor ever had arteries or veins; their bloodvessels were merely blood channels without muscular walls, even in fatty tumors. The cancers are exceptions to this; they have true bloodvessels and nerves, hence are painful.

Dr. Nancrede replied, that as Dr. Formad's statements were totally at variance with those of all reliable observers, he was not prepared to accept them at present, and still thought that careful study of the histology of the vessel walls in the various sarcomata might reveal something of practical interest.

Dr. Formad said that, to him, the relative malignancy of these growths was plain. Spindle-cells can never move from their position, especially if the bloodvessels are small. The small round-celled sarcomata have small cells, and are more vascular, and, hence, are very malignant—*i. e.*, give metastasis. Giant-cells never travel.

Dr. Shakespeare said that the suggestions of Drs. Nancrede and Barton, as to a possible difference in the bloodvessel walls of sarcomata of differing malignancy, were doubtless based upon the well-known fact that these growths become generalized through the blood channels. It seemed to him a matter of interest, and also raised a point which might be found of importance, if properly investigated, as explaining the clinical differences. It is indeed true that the tendency to malignancy from metastasis is in large part due to the ease with which cells can be detached from their place, and this has as much to do with metastasis as the supposed mobility of elements. As to the condition of the vessel walls in recurrent fibroma, he was very sure that in the primary tumors which have been, after removal, diagnosed as pure fibromata, with numerous endothelial cells along the bands of fibrous tissue, recurrences have shown a change of type to perfect sarcomata; yet the bloodvessels in the first were those of connective tissue, while in the second they have the character of simple blood channels.

Dr. Hughes called attention to the theory of a late German observer, that all sarcomata arise from the endothelia of bloodvessels. It is then easily understood how they become generalized, the cells arising from the endothelium setting up the same change in the endothelium wherever they touch, while cells derived from other structures will have no effect. This distinction might be made between sarcomata remaining

local and those becoming generalized, that the former arise from fibrous tissue and not from endothelium.

Dr. Nancrede desired to say, in conclusion, that he was of course perfectly familiar with the fact that mobility of cells had much to do with malignancy, but he felt compelled to deny positively, upon the basis of experience, the so-called fact so positively asserted by Dr. Formad, that large spindle-celled sarcomata never can become generalized because, from the form of their cells, they must "stick" in the vessels. He had presented a specimen to this Society, some years since, of the most malignant growth he had ever had the misfortune to deal with (here followed history). He believed that Dr. Formad examined the specimen and had not then dissented from his opinion. He could relate other instances presented to this Society, but further remark was unnecessary, since all observers except Dr. Formad had repeatedly called attention to the special malignancy of large spindle-celled sarcomata, except in certain situations. He would suggest that positive statements founded on any one observer's experience are apt to be delusive.

June 11, 1885.

IX. SPECIMENS FROM THE LOWER ANIMALS.

1. *Autopsy of case of pleuro-pneumonia in a cow.*

Presented by Dr. T. D. Dunn.

The disease was of ten days' duration, and the prognosis being hopeless, the animal was killed. The rectal temperature was $104\frac{4}{5}°$, respiration 89, pulse 42, eyes sunken, ears drooped, back somewhat arched, great difficulty in walking, slight exertion causing dyspnœa and coughing. Respiration was jerky and shallow; there was slight muco-purulent coryza. Percussion gave absolute dulness over entire right side and lower part of left, while over the upper portions resonance was normal or slightly exaggerated. Auscultation: absence of vesicular murmur on right, and even bronchial breathing could only be detected over circumscribed areas; over upper part of left side, auscultatory signs normal; below, nothing could be heard.

Autopsy.—Much emaciation, muscular tissue of a deep mottled red, exuding on pressure much venous blood. The pleuræ contained about six quarts of clear serum, with a few flakes of lymph. Both layers of the pleura were covered with from one to three inches of thick, tough, unorganized lymph, the membrane itself being rough and congested. The weight of the membrane was estimated to be twelve pounds. The left lung was crepitant throughout, but congested below; the right lung was completely carnified, while some of the largest bronchi were filled with plastic plugs, which, on removal, left the mucous membrane rough and swollen. The other bronchi had their mucous membrane swollen and congested. Frothy muco-pus exuded from the cut lung surface when scraped. The solidified lung was estimated to weigh fifty pounds, the normal being three and a half pounds. Right heart was dilated and its tissue soft; as the animal had been bled after death, the vessels were nearly empty. Other organs healthy. Microscopical examinations of the blood $\times$ 670 to $\times$ 1000 from the heart showed innumerable globular or oval micrococci from 0.35 to 0.5 millimetre in diameter. They were rarely grouped in colonies, more frequently in pairs, but usually single. Lung-scrapings showed granular cells, shreds of tissue and innumerable micrococci. The cells contained bodies resembling the

micrococci of the serum; they were non-soluble in ether, neither did they stain with aniline green, nor hæmotoxylon, whether in an acid or alkaline solution, while the remainder of the cell readily colored. Aided by Dr. Martin, of West Chester (who assisted me in the microscopical examinations detailed), I have commenced culture experiments, which in one instance have succeeded. *September* 27, 1883.

---

2. *Some studies on the micrococcus of pleuro-pneumonia of cattle.*

Read by Dr. T. D. Dunn.

On September 25, 1883, through the kindness of Dr. Bridge, Assistant State Veterinary Surgeon, and Mr. Thomas Edge, Commissioner of Agriculture of Pennsylvania, I was invited to be present at an autopsy on some cows suffering from pleuro-pneumonia; their condition being such that recovery was deemed impossible, Mr. Edge ordered them killed. As a description of the macroscopic and microscopic condition of the lungs was read before this Society a year ago, and as it would have no special bearing on the bacterian nature of the disease, a detailed account will be omitted. Suffice it to say, the lung was completely solidified, the air cells filled with effused blood, serum, and lymph, which usually extends into the small bronchial tubes. Portions of the consolidated lung and blood from the heart were placed in a bottle which had been thoroughly cleansed, and the bottle closed with a ground glass stopper. These were examined microscopically by Dr. George Martin and myself, and were found swarming with germs—micrococci. These little bodies, although seen distinctly with a power of 670 diameters, are best studied with a power of 1000. They are colorless, globular, or oval in form, outline regular, and refractive power notable. The Brownian movement is marked; this is a tremulous motion not peculiar to micrococci. It is common to inorganic particles as well as minute vegetable and animal organisms. They do not seem to move in a manifest manner, independent of the currents of liquid in which they exist. They measure from a third to a half micromillimetre, or from $\frac{1}{8000}$ to $\frac{1}{6000}$ inch in diameter. They are not dissolved by ether, alkalies, or acids, and take the staining of aniline colors slowly. I have, however, succeeded in staining them by first treating with aqua ammonia, then with staining fluid, and afterward washing with a weak solution of nitric acid. They have recently been more satisfactorily stained by a two per cent. alcoholic solution of methyl-violet. They multiply in nitrogenous culture fluids at ordinary

temperatures by millions. They are generally separate, though sometimes united in pairs and little cellular colonies forming distinct zoöglœa. From the fact of their being occasionally seen in pairs it is reasonable to suppose that multiplication is taking place. They resist putrefaction, for the cultivation tubes, started September 26, swarmed with them two months later. When the nitrogenous material is exhausted, their growth is stopped, and they remain in a latent state, as it were, until additional food is given, or they are transplanted into fresh fluids. After the tubes stand a few weeks, the membrane formed on the top sinks to the bottom, and the liquid above clears. That they are not dead, but only in a state of repose, is evident from the fact that they multiply anew when inoculations are made from them, but less rapidly than inoculations from more recent cultures.

Dr. J. J. Woodward, U. S. A., presented, at a meeting of this Society in 1861, a pleuro-pneumonic lung, and mentioned certain "spores of fungi" found in both the healthy and diseased lung, but he did not describe them. These "spores of fungi" are probably the micrococci under consideration. Aside from this I have not found any record of them, but, unfortunately, I have not had access to the literature pertaining to this subject.

The following culture experiments were made with the serum virus taken from the diseased lung: The culture fluid consisted of an extract of fresh beef, made by chopping it fine and pouring over it hot water. After maceration the juice was expressed, and the extract boiled for several minutes. It was then filtered and again boiled to destroy thoroughly all germs. It was then placed in culture tubes which had been washed in a solution of corrosive sublimate, and afterward boiled. The tubes were closed by absorbent cotton, which was sterilized with corrosive sublimate and the application of dry heat. After the culture fluid in the tubes had cooled, a minute quantity of the serum was introduced by a small knife the blade of which had been heated in a spirit lamp. The tubes were then placed where the temperature ranged from 90° to 120° F. On examination of these tubes on the 28th, the liquid was found turbid, a thin membrane formed over the surface, and there was a slight deposit. Under the microscope thousands of micrococci were seen. From this cultivation a second was made, and after standing forty-eight hours the surface membrane, cloudiness of fluid, and slight deposit appeared, and myriads of micrococci were found. From this a third generation was started, in which appeared a few bacilli—the first discovered. They are very active, colorless bodies, measuring from three to five micromillimetres in their long diameters, and from one-third to one-half in their

short. Their movements are at times rapid, again they are in a state of repose. Sometimes one will remain a long time motionless, then suddenly dart across the field of the microscope, setting many of its fellows in motion, which seem to catch the spirit of the active bacillus. At one time they advance with the rapidity of an arrow, then retreat or describe circular lines. It was noticed that in those cultivations in which the bacilli were found, the surface membrane was thicker and more tenacious. In cultivations conducted at a lower temperature the development of micrococci was not so rapid. Fearing that some atmospheric germs might have been introduced with the culture, other cultivations were begun from the second generation, in which no bacilli were found. The culture fluid was boiled at intervals to kill germs that might develop from spores not destroyed by previous boilings, and as a further test non-inoculated tubes were placed by their side. In forty-eight hours the former were swarming with both bacilli and micrococci, while the non-inoculated ones remained clear for ten days. These subsequently developed germs after inoculation. A second series of observations was commenced with fresh virus, obtained October 4. The first and second cultures were pure, but in the third bacilli appeared, and in the fourth they had greatly increased. It is difficult to explain the relations these forms bear to each other; as to whether the bacilli are organisms developed from the micrococci —the latter being in a sporal stage of their growth, our investigations will not justify a positive answer. Koch has determined that the bacilli of anthrax develop veritable spores, and they in turn develop bacilli. Several other observers hold this view, and according to the investigations of Koch, Cohn, and Pasteur, upon the development of bacteria, it is probable that the spores of bacilli and other bacteria are identical with micrococci in form, aspect, and behavior toward chemicals. In those diseases in which certain bacilli and micrococci are found to be the virus, it is impossible to distinguish them from harmless ones by their microscopical appearance; that is, a specific disease germ can only be determined by its effects on living organisms. The micrococcus of pleuro-pneumonia, so far as present observations go, is identical with that of diphtheria, chicken cholera, and the recently discovered micrococcus of scarlet fever. It is further found that this germ of virulent matter rendered harmless by attenuation, does not differ microscopically from the unattenuated, which destroys life. I have made no inoculations on animals with the micrococcus of pleuro-pneumonia, but a few cows have been inoculated by others without any reference to a special virus or cultivation of the germs and the disease was transmitted. However, several experiments have been made, in view of

destroying the germ, the results of which I will briefly state. A tube containing cultivated micrococci was boiled, and from it a second was inoculated. In thirty-six hours the tube contained many micrococci, showing that the germ is not destroyed at 212°. A culture fluid, to which had been added ten per cent. of alcohol, was then inoculated. No micrococci had developed one week later. One and a half per cent. of benzoic acid with borax to dissolve was then added to a culture fluid; neither micrococci nor bacilli had appeared six weeks afterward. Another culture was started, to which was added corrosive sublimate in the proportion of one-half grain to the ounce. In three weeks there were no traces of germ life. To test the influence of cold on these organisms, a tube containing cultivated germs was frozen, and from this sterilized liquids were inoculated. In forty-eight hours they contained myriads of micrococci and a few bacilli. A portion of diseased lung was frozen and inoculations from this grew in about the same time. It was afterward found that the cotton which had been sterilized by heat and corrosive sublimate had been inadvertently exposed to old cultivations and decomposing organic substances, and it is possible that bacteria were introduced by it. When I repeated these experiments it was found that while inoculations from non-frozen virus develop micrococci in a few hours, it requires several days for sowings from frozen specimens to grow in the same culture fluid, and under the same conditions of temperature. Whether they were not exposed to cold long enough to destroy the germs, or the influence is only sufficient to render them inactive, further investigations will be required to determine. It is my impression that cold will check the spread of the contagion, but not destroy it altogether, and that when the disease once attacks an animal, cold will have no influence upon it, though it may prevent the spread of the infection to others in the same herd. The power of medicinal agents to control the disease seems to be very feeble. It would appear that corrosive sublimate, alcohol, and benzoic acid arrest the growth of these germs, but whether doses sufficient to destroy them can be administered without endangering life our veterinary surgeons must determine.

Dr. Shakespeare said that he had read of two attempts within the last year or two, to isolate the micrococcus of this disease. Bruylants and Ferrier united in an attempt of this kind and have reported their observations in the *Bull. de l'Academie Belgique*, 1880, to the effect that they found a micrococcus constant in the pleuritic and alveolar exudate. More recently the report of Poels and Nolan, of Rotterdam, has appeared, in which they describe the isolation and culture of many generations of micrococci. Moreover, they have compared them with those of human

pneumonia, claiming their identity morphologically and with regard to their mode of growth; and a further identity as to the results of inoculation, their experiments showing that pleuro-pneumonia in cattle has been produced by inoculation of the cultures of micrococci from human croupous pneumonia as well as by inoculation of cultures from the pleuro-pneumonia of cattle. The latter report is published in the *Centralb. f. d. med. Wiss.*, 1884, No. 9.

Dr. Formad said that this microörganism had also been seen and described by Veterinary Surgeon Lyman, who had presented a very elaborate report to the Department of Agriculture. Dr. Tuill also, both a medical man and a veterinary surgeon, had worked in pleuro-pneumonia for two years in the Pathological Laboratory of the University of Pennsylvania, always finding the micrococcus present, and in pure cultures, kept up for many generations, he had not observed any other bacteria. He had inoculated two calves with large quantities of the culture and had failed, whence he concluded that the micrococcus was not the cause of the disease. He remarked, as a fact in favor of the micrococcus being the cause of the disease, that these organisms are chiefly found in the lymph, and that in pleuro-pneumonia enormous lymph-spaces are developed in the lungs, which are filled with a grumous liquid containing micrococci in large numbers, while the contents of the alveoli contain very few micrococci but swarm with other bacteria.

Dr. Dunn, in his concluding remarks, said that one point of interest had been omitted in his paper, which was that the cattle from which the specimens had been obtained had been first knocked down, then bled to death and buried superficially in a field through which flowed a stream from which neighboring herds were watered. In a few weeks the disease appeared in these cattle also. As to the literature of the subject, he had not access to sufficient to familiarize himself with any investigations made by others. Some experiments with reference to inoculation have been successfully made in France and England. The lymph was introduced into the body and tail and was found to protect the animal from the disease. When the virus was inserted into the tail with proper precautions, the mortality was less, being from one to two per cent. It was also found that when the tail became greatly inflamed, it could be removed to limit the inflammation and still afford protection to the animal. Inoculated animals did not communicate the disease.

November 13, 1884.

3. *Acute endocarditis in a dog, with embolic infarctions in heart and kidneys.*

Exhibited by Dr. H. M. Fisher.

This was a carriage dog about 9 years old. Since he had had one of his eyes put out, about four years ago, by somebody firing a load of small shot at him, he had had much less spirit than previously and had become very fat. It was noticed two or three days before his death that he was languid and "off his feed," and he was observed to have a slight convulsion. Another fit occurred a few hours before his death. He was found dead one morning in a horse stall.

On opening his chest I found that his *lungs* were collapsed, but easily distended by forcing air through the trachea and that they presented nothing otherwise abnormal. Large veins in neck were greatly distended by black blood. A small clot was found embedded in the anterior surface of the transverse portion of the arch of the aorta. The right auricle of the *heart* and the canal were found to be distended with black fluid blood. The heart weighed nine ounces. The tricuspid valve showed numerous vegetations and was somewhat thickened. There were some points of infarction at the origin of the chordæ tendineæ. The mitral valve showed inflammatory vegetations, several of which from their appearance were evidently of recent production. One or two of these left, when detached, an ulcerated surface. The aortic leaflets were thickened and rigid and the aorta showed much thickening generally and other signs of atheromatous change. There were some yellowish spots in the heart muscle which looked like the débris of former emboli, also two infarctions which were apparently recent, in the left ventricular wall.

The *left kidney* weighed three ounces. Externally to it in the perinephritic tissue was a recent blood clot, and immediately beneath this in the kidney itself there was a wedge-shaped or conical infarction about three-quarters of an inch in diameter at its base, the base of it abutting directly upon the capsule of the kidney, and causing a pouting of the surface of the kidney at this point. The capsule of the kidney was somewhat adherent and the whole surface lobulated. Section of the kidney showed marked fibrous indurations, and one or two other smaller recent infarctions were seen in it. The pelvis was occupied by an oblong and jagged calculus which was very brittle. The *right kidney* weighed two ounces and was also markedly lobulated, and presented at

one spot a well-marked cicatricial depression, probably due to previous infarction. One or two spots of recent infarction were also noticed in the cortical portion of this organ and its pelvis also contained a number of small calculi.

The *liver* was irregular in outline and its vessels were filled with black blood. The left lobe was intensely congested and very soft and friable. The *spleen* was rather small and apparently of normal consistence.

March 26, 1885.

X. MISCELLANEOUS.

1. *Address of the Retiring President, Dr. James Tyson.*

Delivered October 9, 1884.

The termination of another year discovers the Pathological Society with a membership of 153, which is precisely that of a year ago, for, although eight new members were elected, there were six resignations and two deaths. The latter included the venerable Prof. S. D. Gross, who was one of the original members, and Dr. James Markce, who was a member for thirteen years.

The number of specimens exhibited from Sept. 1883, inclusive, to June, 1884, inclusive, was seventy-one, or nine less than during the sessions of 1882 and 1883, an average of three and one-half to each meeting. Among the more unusual were

Hypertrophy of Nasal Mucous Membrane, by Dr. Seiler.
General Melanosis, by Dr. Seiler.
Sarcoma of Anterior Mediastinum, by Dr. Bruen.
Pseudopolyposis of the Large Intestine, by Dr. J. H. Musser.
Cancer of the Mediastinum, by Dr. J. C. Wilson.
Acute Yellow Atrophy of the Liver, by Dr. Musser.
Hypertrophic Cirrhosis of the Liver, by Dr. Musser.
Primary Cancer of the Liver, by Dr. Musser.
Stab-wound of the Brain, by Dr. C. B. Nancrede.
Rupture of the Heart, by Dr. Dunn.
A Case of Paget's Disease of the Nipple, by Dr. MacConnell.
Aneurism of the Left Ventricle of the Heart, by Dr. Hughes.

The year has been one of no signal event in the history of the Society. We have gone on in the even tenor of our ways, adding, I trust, a few facts to the existing knowledge of pathological anatomy, while we have profited ourselves by the interchange of views which has taken place in the discussions. These discussions are becoming less and less discursive, and show that a large number of our members are becoming accurate pathologists and pathological histologists. The attendance has been less than in some other years, being an average of eighteen for each meeting, as compared with twenty last year; but it

has been more uniform, and the fact that the same faces are seen here evening after evening proves that there is more real interest in the subject; and the Society has probably never possessed in a more eminent degree the elements of success.

Our finances are in a healthy condition. A year ago, although the Treasurer reported a balance of $184.90 in the treasury, against this there was an indebtedness of $150. The income during the year, entirely from annual dues, was $455, of which $443.86 were expended, leaving a balance of $196.04, with $400 due the Society, of which $350 are reported by the Treasurer as easily collectable. All debts have been paid except that due the Collins' Printing House, the bill for which has not been rendered, the volume being just delivered. The Treasurer estimates the income for the ensuing year at $602 from 153 members, which, with the unpaid dues collectable and the balance of $196.04, will make the estimated income for next year $1148.04 to meet the annual expenses of the coming year and the cost of publishing the new volume, estimated at $435 for an edition of 200 copies bound. Adding the cost of corrections the cost will be $517, but as the action of the Society at its last meeting will virtually save it the cost of binding, we may put down its cost at about $500.

But one conversational meeting was held during the past year, on the fourth Thursday in October, 1883, when Dr. Seiler gave a lecture upon the Pathology of Phthisis. The Business Committee have provided a paper by Prof. Delafield, of New York, at the next conversational meeting to be held October 23d. The subject of the paper will be Broncho-pneumonia.

In the autumn of 1882, the Business Committee arranged for a series of meetings, the object of which should be the discussion of a special subject to be opened by a member invited for the purpose, who was expected to illustrate his remarks by an appropriate set of specimens. Two of these meetings have been held. At the first of them, February 8, 1883, Dr. Bruen gave an admirable lecture on the Morphology of Phthisis abundantly illustrated by specimens of the different forms of phthisis, and which elicited very full discussion. At the second meeting, January 25, Dr. Musser illustrated in an exhaustive manner the different forms of disease of the liver.

Undoubtedly the most important event of my term of service as president, is the issue of the volume (XI.) of *Transactions* which is ready for delivery this evening. It contains 301 pages, and includes, as far as furnished for publication, the descriptions of specimens presented to the Society, and addresses delivered before it from September, 1881, to June,

1883, inclusive, or for two years. In size the volume is almost precisely that of volume X., which contains 307 pages, and also represents the proceedings for two years or sessions. It contains an unusual number of excellent illustrations, of which sixteen illustrate Dr. J. Solis-Cohen's paper on Tuberculosis as manifested in the Larynx, and four Dr. C. Seiler's paper on Intra-nasal Hypertrophies.

The number of reports of the Committee on Morbid Growths is less than is found in any volume since this Committee was instituted. Indeed, there seems of late years to have been a gradual falling off in these reports, so that now it is comparatively rare to have one. This may be partly owing to the fact that skill in microscopy is very much more common among us than it used to be, and it is, therefore, unnecessary to call upon the Committee for assistance. But there has also been some dereliction of duty on the part of this Committee, as I recall several specimens referred to it on which no report has been made. It is to be hoped that the incoming members will renew the reputation which the Committee on Morbid Growths have in the past had for contributing to the interest and value of our meetings.

I have already said that I believe that at no time has the Society possessed in a more eminent degree the elements of success, by which I mean never was there a larger number of members qualified to contribute to our knowledge of pathology and morbid anatomy, and never were we less hampered by impecuniosity. At the same time the Society is capable of taking a more conspicuous position than it has at present among societies devoted to the increase and diffusion of medical knowledge. It has doubtless suffered through the formation of new societies, some of which, from their so-called more practical tendencies, are more attractive to the superficial mind, while they absorb, also, a certain amount of material which would otherwise come to us. While the membership has grown, we have also to note the resignation during the past few years of men whom, from their positions as teachers and practitioners, we would expect to see not simply as members, but as active members of such a society. This should not be the case, and an effort should be made to secure the return of these members, either by causing the Society to become so illustrious as to make its membership most desirable, or by removing the disaffection which may in some instances have been the motive for resignation. So fundamental to a rational system of medicine is a knowledge of pathology, and an interest in it, that I deem it a disqualification in an applicant for a teacher or hospital position, that he is not an active member of such a society as ours. It is curious that it seems to be a recognized thing in Philadelphia that when

a man approaches forty years of age he is graduated from pathology, and that a pathological society has no more interest for him. Especially does it seem to be the case, that having been President of this Society one or two terms debars the ex-President from any further interest in it. I can assure our ex-Presidents that this is not the case, and that we will still be glad to see them among us It is a sad mistake to suppose that pathology and morbid anatomy are for young men only. They are for old and young alike. Pathology is a changing, developing science, and I am sure that some of our older members would be surprised to find what they could learn from the young men who gather here semi-monthly.

The facts I have mentioned, however, make it necessary for us all to put our shoulders to the wheel, to make this Society the most illustrious in Philadelphia. To accomplish this, we must all work to one end, the interests of pathology. Present ambitions, personal grievances, personal likes and dislikes, personal feeling of all kinds must give way to the more ennobling purpose of a search for scientific truth.

In retiring from the chair which I have held, by your courtesy, for two successive terms, I am conscious that I have not been as efficient in forwarding the growth and prosperity of the Society as my interest in its objects had led me to wish, and as you had a right to expect of me. It is but an ill excuse to say that peculiarly pressing and absorbing duties elsewhere have contested the time and thought I would have preferred to give to the Pathological Society, but it is my only one. Your efficient business committee has, however, in a great measure, made up for this, and their unceasing efforts have brought forth good fruit which is likely to continue.

I have to thank you for your courteous coöperation in my official conduct of the Society.

---

2. *Case of abscess in the suprarenal capsules.*

Exhibited by Dr. E. T. Bruen.

The accompanying specimens were removed from the body of Mary S., æt. 57 years, who died in the Philadelphia Hospital. Two weeks before death she was admitted to the medical ward, and within a few days a circumscribed swelling in the left femoral region developed into an extensive abscess. Death occurred apparently from septicæmia. No satisfactory previous history could be obtained.

The post-mortem examination disclosed the left kidney one-third larger than normal, capsule quite adherent; upon removal the section showed a granulated surface pale and mottled; the pelvis of the kidney much dilated—*i. e.*, general evidence of parenchymatous nephritis. Suprarenal body very much enlarged, and closely united with the kidney by strong inflammatory adhesions. It was of the size and shape of a hen's egg; on section showed cystic degeneration, or softening of the medullary portion. The contents of the cyst were a thick, purulent, creamy liquid filled with cheesy particles. The cortical portion showed fibroid thickening, forming a dense connective-tissue wall one-quarter to one-half inch in thickness.

The right kidney was of normal size, but showed changes similar to those in the left. Right suprarenal body normal. Other abdominal organs normal; no peritonitis. Abdominal and other lymph glands throughout the body normal. Thoracic organs normal.

On examination of left femoral region a large tumor was found; upon section pus exuded freely, and a large abscess was discovered between the extensors and adductors, and lying beneath the sartorius. The abscess extended into the hip-joint; the acetabulum and periosteum of the head of the femur were eroded.

The comparative rarity of disease of the suprarenal body lends an interest to any lesions affecting it. Dr. Shakespeare has made sections of the capsule of this tumor, without finding any tuberculous structure. There was no bronzing of the skin, or other symptom than those naturally to be expected in association with a large abscess, such as was found in this case. These facts, together with the unilateral character of the lesion, incline me to consider this specimen as one of abscess in the suprarenal body.

Dr. O'Hara asked whether this might not be a surviving abscess left after the absorption of other pus centres, as he thought sometimes occurred.

Dr. Naucrede combated this novel view, contending that while fugitive vesical *congestions* sometimes occurred in pyæmia, which readily disappeared, as well as certain collections of white blood-cells in the thecæ of tendons and the bursæ contiguous to joints, yet he did not believe that septic emboli producing infarcts could be absorbed, as maintained by Dr. O'Hara. Besides, if this explanation were correct, the clinical history should indicate something of the sort, which it did not, being one of *septicæmia*, not pyæmia.

Dr. Bruen said that there were one or two points of interest upon which he had not touched in the notes already read. The patient had

led a dissipated life, having been brought into the hospital from one of the "slums" of the city. He supposed that the woman had received some injury, such as a blow, which had given rise to the abscess in the groin, and she had died with symptoms of septicæmia. He, therefore, regarded the abscess in the renal capsule as secondary. The localization of the pathological process in but one capsule, the absence of bronzing of the skin, vomiting, or vasomotor disorder, separated the case from Addison's disease. Indeed, it may be said the ensemble of the latter disease was wanting. Cases of Addison's disease had been described as being associated with abscess, but the disease was always bilateral, and in association with a special train of symptoms, and with the absence of other pathological processes in the system. The most valuable compilation of cases of diseases of the suprarenal capsules, up to the year 1866, can be found in the *Transactions of the London Path. Society*, vol. xvii., 196 cases having been collected by Dr. Greenhow.

April 9, 1885.

---

3. *Address of the Retiring President, Dr. E. O. Shakespeare.*

Delivered October 8, 1885.

Following the custom of former presidents of this Society I take the opportunity, at the close of my term of office, to say a few words briefly in review of the condition and progress of the Society during the last year, and to make some suggestions for the future born of the experience of the past.

But first, it is proper, and it is at the same time a pleasure to me, to express my hearty thanks for the honor you conferred a year ago by calling me to preside over your deliberations.

With the coöperation of a large proportion of our members, the Society has made many gratifying advances during the year just elapsed. The year was begun in the midst of many difficulties, some of which seriously threatened the prosperity, if not the continued usefulness of the Society. Indeed, forebodings of its speedy death were freely uttered.

I regret to be called upon to say that some of these serious difficulties have ended only with the end of my term of office.

It is, therefore, with no little satisfaction and pride that I am able to lay before you some facts which speak for themselves of a marked and substantial, and, when all the circumstances are given due consideration, an unexpected advance.

Perhaps there is no more reliable index of the solidity of a society than its financial condition. The application of this standard of measurement occasions satisfaction.

The Society began the year burdened with a debt of $677.09, of which $517.09 were due on account of the publication of our last volume of *Transactions*. $60 were due for back rent; $50 were due for back salary of the recorder; and $50 were due, as a prize to be given, to the member who had presented, during the previous year, the best series of pathological specimens accompanied by papers.

As an offset against this debt the Society began the year with a balance in the treasury of $196.04.

The total of cash received up to October 1, 1885, is		$823 79
The total amount disbursed:		
Collins	$275 00	
Rent for 1884	60 00	
Back salary, Recorder	50 00	
Prize	50 00	
Debt reduced by	$435 00	
Proper running expenses for 1885 . .	267 93	
Total disbursements		$702 93
Balance, October 8, 1885 . .		$120 86
Assets:		
Balance, October 8, 1885		$120 86
Back dues		278 58
Dues for 1886		608 00
Prospective initiation fees		85 00
Prospective initiation dues		34 00
Total assets for 1886 . . .		$1126 44
Deduct total estimated current expenses .	$292 05	
Money to be paid for publication of *Transactions* during nine months (about) .	340 00	
		$632 05
Leaving a balance of . .		$494 39
To meet liabilities, balance of debt on last volume of *Transactions*	$242 05	
Recorder owed for last quarter . . .	50 00	
		$292 05
Balance of assets to cover shrinkage in collection of dues, etc.		$202 34

When we turn to the question of membership, there is an equally satisfactory proof of real advance. Seventeen new members have been added to the pay-list of the Treasurer, and many more have been elected but not yet introduced to the Society. Against this satisfactory increment there has been a loss of three members by death. It is with great pleasure that I announce the fact that there have been no resignations. And when we compare the record of this year with that of the previous year, as to the attendance of members at the meetings and as to number of specimens presented there is unquestionable proof that even in this respect the Society has made a real and marked advance during my term as president.

The average attendance of the members at the meetings during the last term of my immediate predecessor in office was sixteen and one-half per meeting, while during the term just closed the average attendance was eighteen and one-half. Then, again, during my predecessor's last term the average of specimens presented was three and three-quarters per meeting, while during the term just closed the average was four and three-quarters per meeting. When it is taken into consideration that during the last term of my predecessor the contest for a prize of $50 to be awarded to the member who should present the best series of specimens during that year, was going on, and that, not only was there no such competition to stimulate members to activity during the term just closed, but that, on the contrary, the effort was openly made to divert members and specimens to other societies, I feel that there is just ground for the retiring president to congratulate himself and the Society, the latter of which he does most heartily, upon the material progress which has been made during the last year.

And now a few words as to the future. I think it will not be gainsaid by those who have long known this Society that jealousy between the schools and personal partisanship have at different times done much to drag our Society down below the level upon which, as one of the oldest medical associations in the city, it should rightly stand. I most heartily congratulate the Society upon the bright prospect which, with the jealousies of schools and bitter personal animosity buried at least for the term of the incoming president, and the provision for an adequate publication of its proceedings, now seems to be opening before it.

3. *A case of general melanosis.*

Exhibited by Dr. Carl Seiler.

The patient, S. H. R., was a native of Ohio, and at the time of his death, September 19, 1882, was 28 years of age. His father, also an American, died of phthisis pulmonalis, but was suffering at the time of his demise with an epithelioma whose location I forget. The mother, also an American, had some kind of a tumor of the breast—nature not known.

The patient had enjoyed comparatively good health up to within a few years of his death. Commencing five years prior to that event he suffered with occasional attacks of intestinal colic. These came on every three months, invariably in the evening, and continued all night. In the morning he would be entirely over it. In 1881 he contracted gonorrhœa and suffered considerably from an attack of epididymitis. In December, 1881, the sight of one eye became impaired, and in February, 1882, the other was attacked. He consulted an oculist (Dr. Ayers, I think), and was treated by him. What the treatment was I do not remember. About this time (February, 1882) he went to Dr. Falls to have a congenital nævus removed from the scapula. This tumor was reddish-brown in appearance and very prominent. He had it removed because his clothing by rubbing against it irritated it and made it painful. After the removal of the nævus by Dr. Falls, that gentleman was called into consultation by the oculist in regard to the patient's eyes, which grew steadily worse. He became a patient in the private hospital of Dr. Ayers, I think, and while voiding his urine one morning about the middle of March another patient called attention to the fact that it was very dark—almost black. Dr. Falls, on being informed of this symptom, supposing that it was a case of hæmaturia prescribed accordingly. Another month passed before Dr. Falls again saw him, and then his attention was aroused to the importance of the case for the first time. In the interim a great change had come over the man. He had lost fifteen or twenty pounds in weight, but his body was still fairly nourished. The integument of the ears, neck, face, etc., had become a dark ashen-gray color. The mucous membranes of the mouth, nose, and eyes were of the same hue. Scattered over his body were numerous nodules varying in size from a pea to a pin's head, being thicker on the anterior portion of the body than on the posterior. I have a series of photographs taken at this time which show that the visible nodules were

hundreds or perhaps thousands in number. The patient stated at this examination, that these nodules first made their appearance immediately after the removal of the nævus, in February, 1882 (I may be in error as to this point, but I glean as much from letters of Dr. Lechlider, who was his physician at home, in Greenville, Ohio). The first one noticed was about the size of a pin's head and situated on the right shoulder. They were not painful, and, hence, the patient had not called his physician's attention to them. The discoloration of the head had commenced about a week prior to the visit to Dr. Falls, or about the 8th of April. Dr. Falls caused an examination of his urine to be made at this time by Prof. Eichberg, of Miami Medical College. Some albumen was found, but the distinguishing feature was the intensely dark color of the sediment. Under the microscope this sediment was found to consist of granular casts of a dark brown, almost black color. Such was the condition of the patient on the 8th of April, 1882, and the problem presented to Dr. Falls was to make a diagnosis.

The possible diseases to be considered in arriving at a diagnosis were argyria, chloasma, melanæmia, melanosis, and Addison's disease. I will not attempt from memory to follow up the reasoning by which a differentiation was made and a diagnosis of *general melanosis* finally arrived at by Dr. Falls. It suffices that he did do so, and that his judgment was vigorously and viciously assailed by quite a number of physicians, not only in Cincinnati but elsewhere.

The disease progressed rapidly. On the 25th of July, Dr. Lechlider, of Greenville, Darke Co., Ohio, where the patient had his home, wrote me as follows: "Mr. Robinson's body is covered with nodules. There are hundreds of them visible, and a vast number that cannot be seen by the eye, but can be discovered by the touch. The entire body is black, cavities and all. I send you by express a bottle of urine voided this morning, and also a small bottle of saliva. The liquid part of the discharges from his bowels are of the same dark or black hue as are these fluids sent to you. He is entirely blind. He has a diarrhœa and his strength is rapidly declining. The end cannot be far off. When it does come I shall send you some of the nodules for examination."

A few days later Dr. Lechlider writes: "Our patient is entirely black from head to foot. He is rapidly declining."

The urine and saliva which he mentions as sending me came to hand, and I have the specimens yet. As soon as I took out a portion for immediate examination I replaced the fluids in small flasks and, drawing out the necks in an alcohol flame, sealed them up. The external appearances are the same to-day as when received. The urine looks like a

bottle of French writing and copying fluid. The saliva is not quite so dark.

The end came rapidly. On the 21st of September, Dr. Falls wrote me that the patient died on the morning of the 18th. He sent me at the same time by express a bottle containing the nodules from which the accompanying sections were made. The nodule from the liver, one of many found there, was about two inches long by one and a quarter wide and three-quarters of an inch thick. That from the brain was perfectly round, button-shaped, and about five-eighths of an inch in diameter. India ink itself is not blacker than these nodules. The piece of skin accompanying the nodules is, however, not black but of a dark chocolate color, and shows that the word "black," as used by Dr. Lechlider, should have been modified, though I have no doubt that it was much darker when first removed from the cadaver than when it reached me; for, as I remarked above, the pigment is so soluble that everything in the way of a fluid seems to take up more or less of it.

I am very sorry that I have no copy of the autopsy at hand. I will write to Dr. Falls and ask him to send you one. The post-mortem examination was conducted by Drs. Falls and Langdon, in the presence of a large number of physicians from Cincinnati. The result was a complete vindication of the skill and judgment of Dr. Falls.

Altogether, the case is a very remarkable one. The literature on the subject is very meagre, and parallel cases are consequently hard to find. In Pemberton's *Clinical Illustrations of various forms of Cancer*, London, 1867, the author quotes two cases of the disease, "General Melanosis," which occurred in his own practice, or under his personal observation. A case is reported in the London *Medical Times and Gazette*, and quoted in Tanner's *Practice*, which in most respects is a counterpart of this one. Fox, in his *Atlas of Skin Diseases*, also quotes a case.

September 27, 1883.

---

4. *A case of pernicious anæmia.*

Exhibited by Dr. W. E. Hughes.

George G. C., white, æt. 45 years, a clerk, was admitted into the University Hospital, February 4th, in an intensely exhausted condition with a history of illness lasting more than two and a half years. He had lived for the last twenty years along the banks of the Potomac in the midst of malaria, and had had ten years ago intermittent fever, last-

ing two months. His habits were regular, and he denied any venereal taint. For the last three or four years he has been much worried by family and business affairs. His father and a paternal uncle and aunt died of apoplexy, his mother and all her brothers and sisters of phthisis; of his own generation all the members were perfectly healthy; he was unmarried. Until he went into the army, during the war, he was well and strong; while there he had an irregular malarial fever, from the consequences of which, and of exposure, he never thoroughly recovered. Two and a half years ago he was attacked, without any obvious cause, by diarrhœa; and, though his appetite and digestion remained good, he lost flesh and strength rapidly. His urine at this time was much increased in quantity, and was said to contain sugar. The diarrhœa continued for some months, and he became reduced almost to a skeleton; then it ceased, the urine fell to its normal quantity, or even below, and he regained much of the flesh he had lost, though his strength and general condition remained far below par. After some months of this apparent improvement, he again commenced slowly to fail. Until within three months the functions of the gastro-intestinal organs were apparently well performed; since then he has had slight heaviness in the epigastrium and flatulence soon after eating a hearty meal, and the bowels have shown a tendency to constipation. Since last June he has been unable, from weakness, to perform any manual labor. There has been no hemorrhage. On admission he was too weak to raise himself in bed; intensely anæmic; the whole cutaneous surface pale straw colored, the veins showing through as pink lines, the mucous surfaces scarcely distinguishable from the skin, and moderately emaciated. There was no œdema. The heart action was excessively weak, with the apex beat in the usual position, and over the body of the heart was heard a soft, blowing, systolic murmur, lessened in intensity by firm pressure with the stethoscope. Over the jugulars and the lateral sinuses was heard a remarkably distinct venous hum. With the exception of a slight failure of eyesight, the special senses were normal. He answered questions intelligently but slowly, as though too tired to think rapidly. In the lower extremities he complained of a feeling of soreness, saying his legs felt as though they had been beaten with a stick. In twenty-four hours he passed one quart of urine, acid in reaction, no albumen, no sugar, specific gravity 1.012. Two days afterward he was weaker, and had lapsed into a mild wandering delirium. Examination of the blood gave 665,000 red corpuscles, and 6000 white corpuscles to the cubic millimetre. The red were rather pale, exceedingly variable in size, some of them being twice as large as normal, others very

small, and many of them tailed and otherwise irregularly shaped. Examination of the eye ground was rendered difficult by his delirium, but no retinal hemorrhages could be detected. He died February 8th.

Autopsy (made by Dr. Formad), three hours after death.—No rigor mortis. Moderate amount of soft, flabby, adipose tissue, especially beneath the peritoneum. Blood pale, everywhere fluid, no clots even in heart. The marrow in the tibia, humerus, and sternum was red, the fat in a great measure being substituted by leucocytes, and forms intermediate between white and red blood-cells and a few giant cells. The heart was rather small and very pale, valves were normal. The lungs contained a few calcified nodules in the apices, and were universally adherent to the chest walls and diaphragm. The bronchial and mediastinal glands were enlarged, and some of them calcified. The liver weighed three pounds, and was pale and anæmic. The spleen was normal in size and rather congested. The pancreas was diminished in size and indurated. In the left kidney were a few depressed cicatrices not unlike old gummata; kidneys, with this exception, normal but anæmic. The stomach showed some evidences of chronic gastritis. No enlargement of any lymphatic glands other than those noted. Nervous structures were not examined.

Dr. Formad said that the marrow, especially of the upper extremities, showed in a marked degree the typical currant-jelly appearance first described, he believed, by Drs. Pepper and Tyson.

Dr. J. H. Musser said that some of the clinical features of the case were unusual, especially the absence of retinal and other hemorrhages. The heart too is usually fatty, and he had thought that medullary bone changes were unusual, the text-books on pathology containing such statements. He brought the matter forward as he would like to have some light thrown on such discrepancies.

Dr. Bruen thought that the bone changes occur more frequently when the case is idiopathic than when there is a malarial history, as in one case seen by him.

Dr. Tyson said that the description of pernicious anæmia, in the pathological text books, is very vague, and no mention is made of bone changes, such as described by Dr. Pepper and by himself, in Virchow's *Archiv*, some years ago. This paper seems to have been entirely overlooked.

Dr. Sidney Roberts had had the opportunity of examining the fractured femur of a woman suffering from this disease, where he noted appearances identical with those presented by the humerus exhibited to the Society this evening. *February* 14, 1884.

INDEX.

ABSCESS, cerebral, 236
of pancreas, 66
of suprarenal capsules, 271
Address of retiring President, 268–273
Adenoma, cystic papillary, of neck, 249
Anæmia, pernicious, specimens from case of, 278
Aneurism of aorta, 80, 88, 109, 110
of heart, 100
of left ventricle, 82, 90
Animals, specimens from lower, 260
Apparatus, digestive, 23
genito-urinary, 200
Astragalus, caries of, 6
specimens from excision of, 14

BARTON, J. M., cystic papillary adenoma of neck, 249
Beates, Henry, Jr., double aneurism of ascending and transverse aortic arch, 109
Bladder, rupture of, 18
tuberculosis of, 200
tumor of, 204
Brain, abscess of, 236
phantom, 234
Broad ligament, cyst of, 222
Bruen, E. T., abscess in suprarenal capsules, 271
enlarged bronchial glands which had caused intrathoracic pressure, 135
sarcoma in anterior mediastinum, 244
three cases of tuberculosis, 152

CÆCUM, cylindrical-celled epithelioma of, 33
Carcinoma of larynx, 136
of liver, 27
of mammæ, colloid, 231
simple, 229
of stomach, 61, 63
and ovaries, 28
of uterus, 132, 218
Caries of head of humerus, 5
of astragalus, 6
Choroid, sarcoma of, 241
Clavicle, sarcoma of, 13
Colon, epithelioma of, 60
malposition of, 80
Committees and officers of Society, iv., v.
Contents, table of, iii.
Corresponding members, xvii

DELAFIELD, Francis, the pathology of broncho-pneumonia, 139
Digestive apparatus, 23
Diphtheria, organs from case of, 156
Diphtheritic bronchitis, 137
croup, 138
Dulles, C. W., enormous hypertrophy of heart (weighing forty-eight ounces), 75
very large ulcer of stomach with unusual features, 23
Dunn, T. D., case of intestinal occlusion, 61
case of pleuro-pneumonia in a cow, 260
rupture of heart, 87
some studies on the micrococcus of pleuro-pneumonia in cattle, 261
Dysentery, chronic, large intestines from two cases of, 33

EDWARDS, W. A., anomalous human lung, 158
carcinoma of uterus, etc., 218
organs from a case of diphtheria, 156
Empyema, 88, 129
Endocarditis, acute, in a dog, 266
ulcerative, 92
Epithelioma, cylindrical-celled, of cæcum, 33
of stomach and colon, 60
Exostosis from vomer, 114

FEMUR, osteomyelitis of, 21
Fibroid tumor, recurrent, of Paget, two cases of, 216
Fibroma of mammæ, 230

Fibroma adeno-, of lachrymal gland, 238
Fisher, H. M., acute endocarditis in a dog, 266
cancer of liver, 27
case of mitral and aortic incompetence, 105
heart showing dilated hypertrophy from a case of calculous pyelitis, 106
heart with mitral incompetence from a case of phthisis, 103
ovarian fibro-cysts and subperitoneal fibroids, 219
parenchymatous nephritis with intestinal ulceration, 210
phthisis with empyema, 129
tubercular ulceration of intestines, etc., 26
typhoid fever with abortion, specimens from, 32
Former Presidents, vi.
Fracture, compound, of leg and foot, 10
of base of skull, 1
of pelvis, 18
ununited, of both bones of forearm, 9
Fussell, M. H., primary tuberculosis of kidney, 212
specimens from case of pneumonia, 197

GENITO-URINARY apparatus, 200

HEART, aneurism of, 82, 90, 100
aortic and mitral valvular disease of, 105
hypertrophy of, 75, 106
mitral valvular disease of, 77, 103
rupture of, 87
Hinsdale, Guy, compound fracture of leg and foot, 10
fracture of base of skull, 1
necrosis of temporal bone and brain abscess, 236
phantom brain, 234
Hearn, J., colloid carcinoma of mammæ, 231
Paget's disease, 230
Henry, F. P., extremely contracted kidneys, 216
multiple hemorrhage of the kidney, 213
Hughes, W. E., absence of parietal pericardium, malposition of liver, 73
aneurism of left ventricle, 82
of aorta; empyema, 88
of left ventricle communicating with aorta, 90
Hughes, W. E., calcified pericardium; double mitral disease, 77
carcinoma of larynx, 136
case of pernicious anæmia, 278
cylindrical-celled epithelioma of cæcum, 33
diphtheritic bronchitis; croupous pneumonia, 137
croup, 138
general tuberculosis of serous membranes, 134
phthisis following empyema; amyloid kidneys; cancer of uterus, 132
two cases of suppurative nephritis, 201
tubercular ulceration of the intestines with perforation, 35
tuberculosis of bladder, etc., 200
Humerus, caries of head of, 5
osteomyelitis of, 22
resection of, 78
Hydatids passed in urine, 217
Hypertrophied mole, two cases of, 252
Hypertrophy of prostate gland, 205
nasal, posterior, 114

ILLUSTRATIONS, list of, xxiv.

JAW, lower, large spindle-celled sarcoma of, 1
upper, round-celled sarcoma of, 7

KIDNEY, amyloid, 132
contracted, 216
cystic degeneration of fœtal, 203
fatty, 218
malposition of, 80
multiple hemorrhage of, 215
sarcoma of, 206
tuberculosis of, 200, 212
Knee-joint disease, 18

LACHRYMAL gland, adeno-fibroma of, 238
Laryngeal complications of phthisis, 115
Larynx, carcinoma of, 136
Lewis, M. J., rupture of one of aortic leaflets during muscular strain, 85
Lipoma, 249
Liver, carcinoma of, 27
malposition of, 73
Longstreth, M., alveolar sarcoma of kidney, 206
Lung, anomalous, 158

MACCONNELL, W. G., case of Paget's disease, 230
colloid carcinoma of mammæ, 231
fibroma mammæ, 230
small spindle-celled sarcoma of rectum, 31
Malignant disease of peritoneum and abdominal viscera, 59
Mammæ, carcinoma of, 229, 231
fibroma of, 230
large spindle-celled sarcoma of lower jaw, 1
sarcoma of, 229, 232, 233
Mastoid abscess ending in basilar meningitis, 238
Mediastinum, anterior, sarcoma of, 244
tumor of, 247
Melanosis, general, case of, 276
Meningitis, cerebral, 238
Miscellaneous, 268
Mitchell, J. K., encephaloid disease of stomach, 63
Mollities ossium, infantile, case of, 8
Morbid growths, report of committee on
Dr. Musser's case of tumor of the bladder, 204
on Dr. Fisher's case of multiple ovarian fibro-cysts, with subperitoneal fibroids, 222
Dr. Barton's case of cystic papillary adenoma of neck, 250
Musser, J. H., abscess of pancreas and thrombosis of portal vein, 66
atheroma and aneurism of aorta; congenital deformity of stomach; malposition of transverse colon and right kidney, 80
hypertrophy of prostate gland, etc., 205
large intestines from two cases of chronic dysentery, 33
lipoma, 249
notes of a case of infectious, so-called ulcerative endocarditis, 82
pleuro-pneumonia complicated with delirium tremens, 131
sarcoma of skin, etc., 250
some statistics of hepatic diseases, etc., 37
tumor of bladder, etc., 204

NANCREDE, C. B., caries of astragalus, 6
caries of head of humerus, 5
Nancrede, C. B., chronic osteomyelitis of humerus, 22
excision of astragalus for caries, 14
extensive trephining of skull, 6
round-celled sarcoma of superior maxilla, 7
resection of humerus, 8
two cases of "recurrent fibroid tumor" of Paget, 216
Necrosis of temporal bone followed by brain abscess, 236
Neff, J. S., case of cardiac aneurism, 100
Nephritis, parenchymatous, complicated with intestinal ulceration, 210
suppurative, two cases of, 201
Nervous system, 234

OCCLUSION, intestinal, case of, 61
Officers and committees of Society, iv., v.
Organs of respiration, 114
of special sense, 236
Osler, W., aneurism of arch of aorta, 110
hydatids passed with the urne, 217
notes on the morbid anatomy of pneumonia, 188
tubercle bacilli in the urine, 215
Osseous system, 1
Osteitis of hip-joint, 11
Osteomyelitis of femur, 21
of humerus, 22
of tibia, 2
Ovaries, carcinoma of, 28
fibro-cysts of, 219

PACKARD, J. H., case of epithelioma of stomach and colon, 60
Paget's disease, 230
Pancoast, W. H., fibroma mammæ, 230
large spindle-celled sarcoma of lower jaw, 1
Pancreas, abscess of, 66
Phthisis, heart with valvular lesion from case of, 103
pathology and laryngeal complications, 115
with empyema, 129, 132
Piersol, G. A., notes on a case of infectious, so-called ulcerative endocarditis, 92
Pneumonia, 137, 197
broncho-, the pathology of, 139
-coccus of Friendländer, 162
notes on the morbid anatomy of, 188
pleuro-, 131
in a cow, case of, 260

Pleuro-pneumonia in cattle, some studies of the micrococcus of, 261
Portal vein, thrombosis of, 66
Porter, W. G., spondylitis of dorsal vertebræ with miliary tuberculosis of lungs, 16
Prostate gland, hypertrophy of, 205
Pyelitis, calculous, 106
Pyelonephritis and chronic parenchymatous nephritis in the same person, 208

RANDALL, B. A., mastoid abscess ending in basilar meningitis, 236
Rectum, small spindle-celled sarcoma of, 31
Reed, T. B., lipoma, 249
Respiration, organs of, 114
Retro-peritoneal sarcoma, case of, 253
Roberts, A. S,, early osteitis of hip-joint, 11
synostosis of vertebral column, 15
spondylitis of dorsal vertebræ, 16
Roberts, J. B., malignant disease of peritoneum and abdominal viscera, 59
of testicle tapped for hydrocele, 224
Rupture of aortic leaflet during strain, 85
of bladder, 18
of heart, 87

SARCOMA of anterior mediastinum, 244
of choroid, 241
of clavicle, 13
of kidney, 206
of lower jaw, 1
of mammæ, 229, 232, 233
of rectum, 31
of retroperitoneal glands, 253
of skin, 250
of testicle, 222, 225, 226
of thigh, 256
of upper jaw, 7
Schweinitz, G. E. de, adeno-fibroma of lachrymal gland, 238
cystic degeneration of fœtal kidney, 203
cysto-sarcoma of breast, 231
hypertrophied mole, 252
mastoid abscess ending in basilar meningitis, 238
recurrent scirrhus of male breast, 229
sarcoma of breast, 232
Schweinitz, G. E. de, sarcoma of clavicle, 15
of testicle, 225, 226
of choroid, 241
spindle-celled sarcoma of breast, 229
urethral polypi, 228
Seiler, Carl, case of general melanosis, 276
posterior nasal hypertrophy in situ, together with an exostosis from the vomer, 114
the pathology of phthisis and its laryngeal complications, 115
Sense, organs of special, 238
Serous membranes, general tuberculosis of, 134
Shakespeare, E. O., address of retiring President, 273
intestinal occlusion, 63
Skull, fracture of base of, 1
specimens from case of extensive trephining of, 6
Specimens, list of, xviii.
Spondylitis of dorsal vertebræ, 16
Sternberg, G. M., the pneumonia-coccus of Friedländer, 162
Stomach, carcinoma of, 29, 61, 63
congenital deformity of, 80
epithelioma of, 60
ulcer of, 23
Stricture, intestinal, 63
Suprarenal capsule, abscess of, 270
Synostosis of vertebral column, 15
System, nervous, 234
osseous, 1
vascular, 73

TESTICLE, carcinomatous sarcoma of, 222
Testicle, malignant disease of, 224
sarcoma of, 225, 226
Thrombosis of portal vein, 66
Tubercle bacilli in urine, 215
Tuberculosis, general, of serous membranes, 134
of bladder, 200
of kidneys, 212
three cases of, 152
Tumors not otherwise classified, 244
Typhoid fever, specimens from case of, 32
Tyson, James, address of retiring President, 268
retro-peritoneal sarcoma, 253
pyelo-nephritis and chronic parenchymatous nephritis in the same person, 208

ULCER of Peyer's patches in typhoid fever, 32
Ulcer of stomach, 23
tubercular, of intestines, 26, 35
Urethral polypi, 228
Uterus, cancer of, 132, 218

VASCULAR system, 73
Vomer, exostosis from, 114

WHARTON, H. R., chronic knee-joint disease followed by acute inflammation, 18
Wharton, H. R., sarcoma of thigh, 256
Willard, De Forest, fracture of pelvis; rupture of bladder; fracture of forearm, 18
osteomyelitis of femur, 21
Wilson, C. M., case of infantile mollities ossium, 8
case of ununited fracture of both bones of forearm, 9
cyst of broad ligament, 222
osteomyelitis of tibia, 2
Wilson, J. C., carcinoma ventriculi, 61
tumor of anterior mediastinum with secondary deposits in the lungs, 247